

REVIEW ARTICLE

BILATERAL PRIMARY MAMMARY (NON-HODGKIN'S) LYMPHOMA: REVIEW OF AN UNUSUAL PRESENTATION

Vibhuti Bhushan¹, Kavita Kumari², Pradeep Jaisawal³, Sanjeev Kumar⁴, Prem Prakash⁵, Khalid Mahmood⁶, S. K. Jha⁷, K. H. Raghwendra⁸

HOW TO CITE THIS ARTICLE:

Vibhuti Bhushan, Kavita Kumari, Pradeep Jaisawal, Sanjeev Kumar, Prem Prakash, Khalid Mahmood, S. K. Jha, K. H. Raghwendra. "Bilateral Primary Mammary (Non-Hodgkin's) Lymphoma: Review of an Unusual Presentation". Journal of Evolution of Medical and Dental Sciences 2014; Vol. 3, Issue 54, October 20; Page: 12487-12491, DOI: 10.14260/jemds/2014/3651

ABSTRACT: Bilateral primary non-Hodgkin's lymphoma of breast is a rare entity because incidence wise it comprises less than 10% of all primary breast lymphoma. Here a case of bilateral breast lump is reported and reviewed, who had bilateral axillary node involvement and which trucut biopsy showed evidence of primary non-Hodgkin's lymphoma and responded satisfactory to chemotherapy.

KEYWORDS: Breast tumor; Bilateral; Primary Non-Hodgkin's Lymphoma.

INTRODUCTION: Primary mammary involvement in NHL is rare and representing 0.4-0.7 % of all diagnosed cases of non-Hodgkin's lymphoma.^[1] Less than 0.6% of all breast malignancy is primary breast lymphoma.^[2] Breast lymphoma usually presents as a painless unilateral breast mass and bilateral disease is seen in less than 10 %.^[3] Such lymphomas are mostly non-Hodgkin's type representing 70-90%.^[1] Primary breast lymphomas exhibit a poor prognosis and its therapeutic management is controversial and till date not fully established. We report a bilateral primary lymphoma (non-Hodgkin's) of breast due to its rarity.

CASE REPORT: A 26 year old female presented to the outpatient department with complains of right breast lump for 3 months, left breast lump with axillary swelling for 1 month and fever for 15 days. Her medical history was unremarkable and there was no history of weight loss and night sweats. The physical examination revealed a lump involving whole of the right breast which was hard, non-tender and fixed to the skin but not to the underlying muscle. Local temperature was not raised and Peud's orange was absent. In left breast, there was a lump of size 5×4 cm involving all quadrants and was hard, non-tender with fixity to the skin but not to the underlying muscle.

There was no Peud' orange and local temperature was not raised. There was bilateral level I axillary lymph node enlargement which was mobile, firm to hard, non-matted and non-tender in nature (Fig-1). Blood examination didn't show any abnormality. In radiological examination, PA view of X-ray chest showed right sided pleural effusion with enlarged mediastinal shadow (Fig-2). Ultrasonography showed right sided pleural effusion and no other abnormality. In CECT Chest, there were bilateral breast mass with lymphomatous nodule in right axillary fossa and right sided pleural effusion. FNAC showed almost monotonous population of lymphoid cells seen in the background of RBCs. Granuloma not seen.

Cytological features are in favor of NHL and biopsy suggested for further evaluation and confirmation (Fig-3). True cut biopsy of both breast and axillary swelling showed loss of normal breast architecture and infiltration of monotonous population of mid-sized lymphoid cells with irregular dark stained nuclei present diffusely. Granuloma and Reed-sternberg cells were not seen and finding suggestive of non-Hodgkin's Lymphoma (Fig-4).

REVIEW ARTICLE

After confirming the diagnosis CHOP regimen chemotherapy was given as Inj. Vincristine -1.4 mg/m², Inj. Cyclophosphamide - 750 mg/m², Inj. Doxorubicin - 50mg/m², Tab. Prednisone- 50 mg/m² for 5 days recycled every 3 weeks for 6 cycles. The patient was later subjected to radiotherapy for local boost to both the axilla (45 Grey). There was significant improvement in patient symptoms and signs after the treatment.

DISCUSSION: Primary non-Hodgkin's lymphoma breast is a rare disease representing only 0.04% - 0.5% of malignant breast neoplasm and approximately less than 2% of extra nodal non-Hodgkin's lymphoma [1, 4]. Patients of PNHML generally present in their fifth or, sixth decade of life [5]. Numerous Authors have found that lymphoma occur more frequently in unilateral breast especially in right side and the rate of secondary lymphoma metastatic to breast exceeds slightly over primary breast lump.[6,7] Bilateral involvement in Primary non-Hodgkin's lymphoma breast is very rare. Most common presentation of primary non-Hodgkin's lymphoma breast is palpable mass.[9]

Domchek et al showed that more than 90% patients with breast lymphoma presented with a palpable mass and mostly diagnosed on clinical examination of breast or, breast self-examination. The increased use of screening mammography has not led to a proportional increase in the diagnosis of primary breast lymphoma nor has it translated into earlier detection of patient with breast lymphoma. [7, 10] The criteria for PNHBL are tissue diagnosis, close association of mammary tissue and lymphomatous infiltrate, no disseminated disease and involvement of ipsilateral axillary nodes only if it occurs concomitantly with primary lesion.

Also, patient with primary breast lymphoma must not have previous history of lymphoma. [8] Histological confirmation of lymphoma is done either by core needle biopsy technique or open biopsy. Primary breast lymphomas are most commonly B-cell lymphoma especially diffuse large B-cell lymphoma ranging from 45-79%. Indolent histologies e.g. follicular non-Hodgkin's lymphoma, extra nodal marginal zone (MALT) lymphoma occur most commonly.[11] A thoracic CT-Scan can confirm the large breast mass with pathological enlarged lymph node in the axilla.

Our patient also fulfills all these criteria as she presented with bilateral non-tender breast lump and had all clinical features of primary breast lymphoma and finally diagnosed as non-Hodgkin's lymphoma on the basis of histopathology, X-ray chest, ultrasound and CT-Scan chest. Patient was diagnosed as primary breast non-Hodgkin's lymphoma with stage II-E according to Ann Arbor staging system.[12]

The treatment of primary non-Hodgkin's breast lymphoma (PNHBL) is similar to that used for other lymphoma. Mastectomy has been a common component of PBL therapy for decades and remains a frequent treatment choice in some reports. Several studies found that mastectomy offered no benefit in the treatment of primary breast lymphoma. Ideally, surgery should be limited to a biopsy to establish the correct histological diagnosis, leaving the treatment with curative intent to radiotherapy and chemotherapy.[13,14]

Recent studies have shown that aggressive B-cell lymphoma should always be treated with chemotherapy alone or in combination with radiotherapy.[9,15-17] The most effective combination chemotherapy is 3-10 cycle of CHOP Regimen Inj. Vincristine-1.4 mg/m², Inj. Cyclophosphamide-750 mg/m², Inj. Doxorubicin-50mg/m², Tab. Prednisone-60 mg/m² for 5days recycled every 3 weeks along with radiotherapy.[9,15,18] Radio therapeutic doses ranges from 30-50 Grey in several studies.[9,18,19] Our case also responded well with this chemotherapy regimen.

REVIEW ARTICLE

Lymph node involvement among PBL patient ranges between 40-50% but there is no evidence that axillary clearance may improve the outcome. We were able to achieve a good response with chemotherapy & radiotherapy without surgical intervention. Many studies showed an improvement of result when treated with the immunotherapy along with chemotherapy. Rituximab (R) is a monoclonal antibody against CD-20 which is expressed by majority of NHL cells, added to CHOP regimen (R-CHOP regimen along with Rituximab-375/m²).^[9]

Various studies showed that 5 year survival ranges from 67-83% and recurrence free survival 42-83% in cases of primary non-Hodgkin's breast lymphoma. Many authors have reported CNS relapse up to 20%. There is variation of opinion regarding prophylactic CNS chemotherapy. ^[20,21,22]

CONCLUSION: Primary breast lymphoma is an unusual clinical condition and generally presented as painless breast mass. Although bilateral breast lump presentation of PBL is very rare. The treatment of primary breast non-Hodgkin's lymphoma depends on histological type and responds well to chemotherapy. Various radiological investigation and histopathology confirm the diagnosis of primary breast non-Hodgkin's lymphoma.

Diffuse large cell lymphoma is most common subtype of primary non-Hodgkin's breast lymphoma. No clear consensus concerning the therapy has emerged. Yet combination chemotherapy (CHOP regimen) and radiation therapy has been proposed as the gold standard treatment for PBL. Major surgery in the form of mastectomy should be avoided as it offers no better result. Survival in patient treated with cytotoxic chemotherapy has improved over the last several years.

REFERENCES:

1. Fischer MG, Chideckel NJ. Primary lymphoma of the breast. *Breast* (1984); 10: 7-12.
2. Gupta D, Shidham V, Zemba-Palko V, Keshgegian A. Primary bilateral mucosa-associated lymphoid tissue lymphoma of the breast with atypical ductal hyperplasia and localized amyloidosis: a case report and review of the literature. *Arch Pathol Lab Med* 24 (2000); 1233-1236.
3. Pullen CM, Cass AJ. Bilateral primary lymphoma of the breast. *Aust N Z J Surg* (2000); 66: 845-847.
4. Lamovec J, Jancar J. Primary malignant lymphoma of the breast: lymphoma of the mucosa-associated lymphoid tissue. *Cancer*. 1987; 60: 3033-3041.
5. Brooks HL, Mandava N, Pizzi WF, Shah S. Inflammatory breast carcinoma a community hospital experience. *J Am Coll Surg*. 1998; 186: 622-629.
6. Darnell A, Gallardo X, Sentis M, Castaner E, Fernandez E, et al. Primary lymphoma of the breast: MR imaging feature. A case report. *Magn Reson Imaging* (1999); 17: 479-482.
7. Paulus DD. Lymphoma of the breast. *Radiol Clin North Am* (1990); 28: 833-840.
8. Wiseman C, Liao KT. Primary lymphoma of the breast. *Cancer* (1972); 29: 1705-1712.
9. Wong WW, Schild SE, Halyard MY, Schomberg PJ. Primary non- Hodgkin lymphoma of the breast: the Mayo Clinic experience. *J Surg Oncol*. 2002; 80: 19-25.
10. Domche SM, Hecht JL, Fleming MD, Pinkus GS, Canellos GP. Lymphomas of the breast: primary and secondary involvement. *Cancer* 2002; 94 (1): 6-13.
11. Jones DE, d' Avignon MB, Lawrence R, Latshaw RF. Burkitt's lymphoma: obstetric and gynecologic aspects. *Obstet Gynecol* 1980; 56 (4): 533-536.

REVIEW ARTICLE

12. Harris NL, Jaffe ES, Diebold J, Flandrin G, Muller-Hermelink HK, Vardiman J, Lister TA, Bloomfield CD: World health organization classification of neoplastic diseases of the hematopoietic and lymphoid tissues: report of the clinical advisory committee meeting- Airlie House, Virginia. *Mod Pathol* 1997, 13: 193-207.
13. Ganjoo K, Advani R, Mariappan MR, McMillan A, Horning S: Non-Hodgkin lymphoma of the breast. *Cancer* 2007, 110: 25-30.
14. Lbrahim MH-, Singletary S: Ann. Surgical management of primary lymphoma of the breast. *Ann Surg* 1991, 214 (6): 725.
15. Ribrag V, Bibeau F, El Weshi A, Frayfer J, Fadel C, et al. Primary breast lymphoma: a report of 20 cases. *Br J Haematol* (2001); 115: 253-256.
16. Nissen NI, Ersboll J, Hansen HS, Walbom-Jorgensen S et al. A randomized study of radiotherapy versus radiotherapy plus chemotherapy in stage I-II non-Hodgkin's lymphomas. *Cancer* (1983); 52: 1-7.
17. Shafman TD, Mauch PM. The large-cell lymphomas. *Semin Radiat Oncol* (1995); 5: 267-280.
18. Ha CS, Dubey P, Goyal LK, Hess M, Cabanillas F, et al. Localized primary non-Hodgkin lymphoma of the breast. *Am J Clin Oncol* (1998); 21: 376-380.
19. Lyons JA, Myles J, Pohlman B, Macklis RM, Crowe J, Crownover RL Treatment and prognosis of primary breast lymphoma: a review of 13 cases. *Am J Clin Oncol*. 2000; 23: 334-336.
20. Hugh JC, Jackson FI, Hanson J, Poppema S. Primary breast lymphoma: an immune histologic study of 20 new cases. *Cancer*. 1990; 66: 2602-2611.
21. Young SD, Imrie K, Gospo darowicz M, Burkes R. Primary lymphoma of the breast: a 30 years retrospective analysis of the Toronto experience. *Prog Proc Am Soc Clin Oncol*. 1999; 18: 41.
22. Dixon JM, Lumsden AB, Krajewski A, Elton RA, Anderson TJ. Primary lymphoma of the breast. *Br J Surg*. 1987; 74: 214-216.

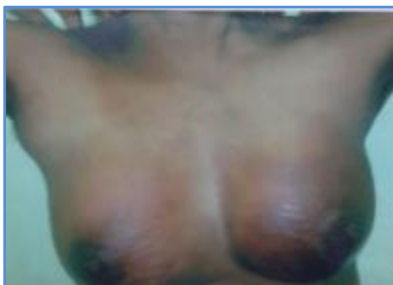

Fig. 1: Photograph of the patient with bilateral breast lymphoma

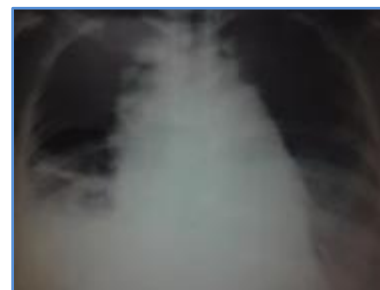

Fig. 2: X-ray of the patient showing Rt. Pleural effusion with enlarged mediastinal shadow

REVIEW ARTICLE

Fig. 3: FNAC shows monotonous population of lymphoid cells in the background of RBC.

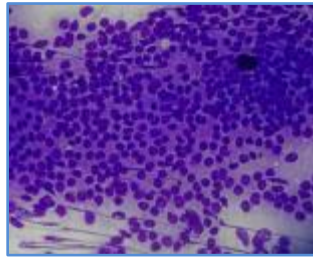


Fig. 3

Fig. 4 (A & B): Malignant lymphoma, True cut biopsy shows loss of breast architecture with mid-sized lymphoid cells and irregular dark stained nuclei (Haematoxylin-Eosin, original magnification $\times 100$ - A; Haematoxylin-Eosin, original magnification $\times 400$ - B).

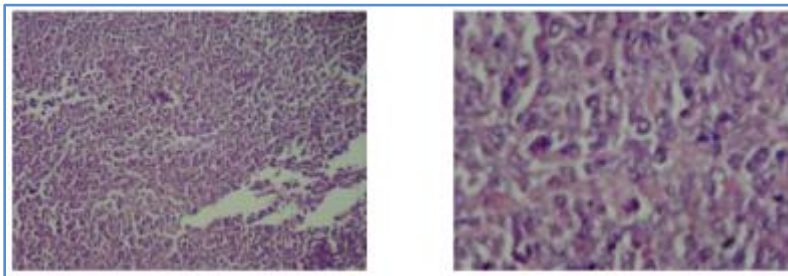


Fig. 4A

Fig. 4B

AUTHORS:

1. Vibhuti Bhushan
2. Kavita Kumari
3. Pradeep Jaisawal
4. Sanjeev Kumar
5. Prem Prakash
6. Khalid Mahmood
7. S. K. Jha
8. K. H. Raghwendra

PARTICULARS OF CONTRIBUTORS:

1. Assistant Professor, Department of General Surgery, IGIMS, Patna.
2. Senior Resident, Department of General Surgery, IGIMS, Patna.
3. Assistant Professor, Department of General Surgery, IGIMS, Patna.
4. Additional Professor, Department of Anaesthesiology & Critical Care Medicine, IGIMS, Patna.
5. Assistant Professor, Department of General Surgery, IGIMS, Patna.

6. Consultant, Department of Trauma Surgery, IGIMS, Patna.
7. Professor & HOD, Department of General Surgery, IGIMS, Patna.
8. Professor, Department of Anaesthesiology & Critical Care Medicine, IGIMS, Patna.

NAME ADDRESS EMAIL ID OF THE CORRESPONDING AUTHOR:

Dr. Vibhuti Bhushan,
D-4/2, IGIMS-Campus,
Sheikhpura, Patna-800014,
Bihar, India.
Email: drvibhuti.bhusan@gmail.com

Date of Submission: 06/10/2014.
Date of Peer Review: 07/10/2014.
Date of Acceptance: 15/10/2014.
Date of Publishing: 18/10/2014.