

Anabolic-Androgenic Steroid (AAS) Induced Bowel Ulcers Mimicking Inflammatory Bowel Disease in a Young Man

Devamsh Arora¹, Priyanka Yadav², Vidiyala Harika³, Akshay Dafal⁴, Sourya Acharya⁵, Samarth Shukla⁶

¹Datta Meghe Institute of Medical Sciences (Deemed to be University), Sawangi (Meghe), Wardha, Maharashtra, India

²Datta Meghe Institute of Medical Sciences (Deemed to be University), Sawangi (Meghe), Wardha, Maharashtra, India.

³Department of Medicine, Datta Meghe Institute of Medical Sciences (Deemed to be University), Sawangi (Meghe), Wardha, Maharashtra, India. ⁴Department of Medicine, Datta Meghe Institute of Medical Sciences (Deemed to be University), Sawangi (Meghe), Wardha, Maharashtra, India. ⁵Department of Medicine, Datta Meghe Institute of Medical Sciences (Deemed to be University), Sawangi (Meghe), Wardha, Maharashtra, India. ⁶Department of Pathology, Datta Meghe Institute of Medical Sciences (Deemed to be University), Sawangi (Meghe), Wardha, Maharashtra, India.

INTRODUCTION

Anabolic - androgenic steroids (AAS) are synthetic, or human-made variations of the male sex hormone testosterone. The proper term for these compounds is *anabolic-androgenic steroids*. "Anabolic" refers to muscle building, and "androgenic" refers to increased male sex characteristics. Some of the most common anabolic steroids taken today are anadrol, oxandrin, dianabol, winstrol, deca-durabolin, and equipoise. These steroids are used for medical conditions, but people also use them illegally to boost muscle mass, performance, and endurance and to shorten recovery time between workouts causing cardiac diseases, GI ulcers, hormonal disturbances, depression, etc. We present a case of a young male who was abusing AAS as performance enhancer, presented to us with chronic abdominal pain and later on colonoscopy. He was diagnosed to have multiple colonic ulcers.

Testosterone first synthesized in Germany in 1935 was initially used for the treatment of depression.^[2,3] Misuse of anabolic steroids was started in 1954 Olympics, when Russian weightlifters were given testosterone which is known to increase the muscle mass.^[4] More benefit is seen for strength-dependent sports [weightlifting, shot-put throwing, football] than for sports that require speed, agility, flexibility, and/or endurance.^[5] In the 1980s, anabolic steroid use began to extend into the general population and the vast majority of people who misuse anabolic steroids are male non-athlete weightlifters in their 20s or 30 in order to achieve their ideal body.^[6-8] Anabolic steroids have been used in recovery from catabolic states, as it maintains adequate nitrogen balance and therefore helps in tissue healing and the maintenance of muscle mass.^[9] The abuse of these drugs has been linked to many clinical manifestations like cardiac arrest, ischemic stroke,^[10,11] hypertension^[12] and infections like HIV and hepatitis B and C.^[13] The abuse of these drugs also cause oligospermia.^[14-16] gynaecomastia and male pattern baldness.^[17,18] in males while in females it causes excessive body hair, coarse skin^[19] and decreased breast size.^[20] Although many of the undesirable effects of anabolic steroid abuse have been reported, little is known about its involvement in the causation of colonic ulcers and the same has not been thoroughly discussed before.

Corresponding Author:

*Dr. Sourya Acharya,
Professor,
Department of Medicine,
DMIMS University, Sawangi (Meghe),
Wardha-442001, Maharashtra, India.
E-mail: souryaacharya74@gmail.com*

DOI: 10.14260/jemds/2019/826

*Financial or Other Competing Interests:
None.*

How to Cite This Article:

Arora D, Yadav P, Harika V, et al. Anabolic-androgenic steroid (AAS) induced bowel ulcers mimicking inflammatory bowel disease in a young man. J. Evolution Med. Dent. Sci. 2019;8(50):3816-3818, DOI: 10.14260/jemds/2019/826

*Submission 06-09-2019,
Peer Review 26-11-2019,
Acceptance 03-12-2019,
Published 16-12-2019.*



PRESENTATION OF CASE

A 24-year-old male presented with complaints of abdominal pain since 4 weeks which was diffuse (all over the abdomen) and is of dull aching type which is not relieved on consumption of food. Patient also had h/o loose stools since 3 weeks, mucoid in consistency which were associated with pain abdomen and tenesmus. Patient had fever since 2 weeks which was associated with chills and rigors.

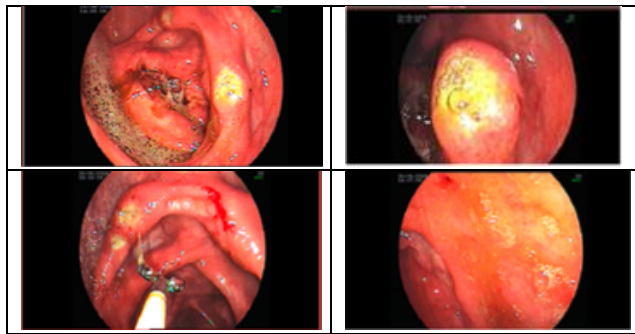


Figure 1. Colonoscopy Showing Multiple Ulcers

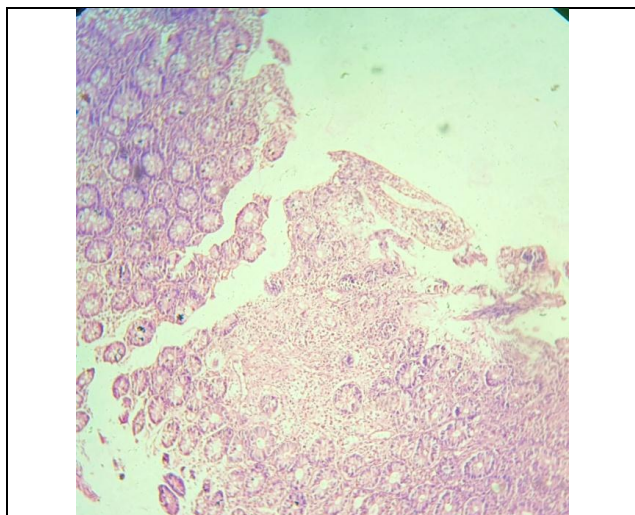


Figure 2. Section from the given H & E Slide 40 X View Shows Superficially Ulcerated Mucosa, Unremarkable Sub Mucosal Glands, Submucosa and Muscularis Mucosa, with Extensive Necrotic and Suppurative Debris with Tract Formation- Features Suggestive of Acute on Chronic Suppurative inflammatory Lesion

The patient had no history of alcohol intake. He exercised in a local gymnasium and was basically a body builder. On asking leading questions he agreed of taking anabolic steroids for performance enhancement. He was taking injection Testosterone enanthate 200 mg IM every month for 7 months and tablet Oxandrolone 20 mg orally 5 times a week since 6 months. There was no history travel to any other region. There was no history of hematemesis, melena, hematochezia, heart burn, chest pain, jaundice in the past. The patient took 2 separate courses of Tablet. Ciprofloxacin and tablet. Tinidazole each for 7 days by different private practitioners without any relief. His general physical examination was normal. CVS and RS examination did not reveal any abnormality. Per abdomen examination revealed diffuse abdominal tenderness on light palpation. There was no organomegaly. Bowel sounds were normal.

PATHOLOGICAL DISCUSSION

TLC 11,900/mm³ with predominant leukocytosis. Hb- 9 gm%, KFT, was normal. LFT: Serum bilirubin 1.8 mg%, ALT - 78 IU/L, AST - 64 IU/L, Serum alkaline phosphatase 180 IU/L. Serum Amylase and lipase were within normal. Fasting blood sugar and lipid profile was normal. Ig M Antibodies against the yeast *Saccharomyces cerevisiae* [ASCA] and against neutrophils [P- ANCA] were negative. USG abdomen was normal. A colonoscopy was performed which revealed multiple discrete ulcers in the descending colon. [Figure- 1] Histopathologic examination of the biopsy revealed features of non granulomatous inflammation. [Figure- 2]

DISCUSSION

Anabolic- androgenic steroids [AAS] are known to cause multi organ damage secondary to supra optimal dosage taken by the athletes. They increase the risk of atherogenesis.^[21,22] Within the gastro intestinal system main side effects of Anabolic steroids are increased levels AST, ALT and LDH^[23] which tend to peak in the 2nd to 3rd week of drug administration and are known to return to normal levels after discontinuation.^[23] Steroids induce a wide range of hepatic disorders ranging from impaired excretion, cellular hepatocyte changes, cholestasis, peliosis hepatis, and hepatocellular hyperplasia to carcinomas majority being benign adenomas have been reported.^[23]

Effect of exogenous steroids is expressed on the hypothalamic pituitary gonadal axis through negative feedback mechanism.^[23] Increased consumption of testosterone leads to rise in estradiol causing heightened voice and gynecomastia which may be painful.^[24] AAS caused mild elevation of serum creatinine.^[25] Weight lifters consuming anabolic steroids along with creatinine supplements may increase renal damage.

AAS also increase potassium due to retention of sodium and metabolic alkalosis along with hypokalaemia due to excretion of H⁺.^[6] These are the known side effects caused by the anabolic steroids. Ulcers in the large intestine due to AAS abuse has not been reported till date. This is a rare case where the patient presented with intestinal ulcers secondary to AAS abuse for increasing muscle strength. The histopathologic features ruled out characteristic features of inflammatory bowel disease [Ulcerative colitis and Crohn's disease] and the serologic markers were absent in our case.

REFERENCES

- [1] Kuhn CM. Anabolic steroids. *Recent Prog Horm Res* 2002;57:411-34.
- [2] McHenry J, Carrier N, Hull E, et al. Sex differences in anxiety and depression: role of testosterone. *Frontiers in Neuroendocrinology* 2014;35(1):42-57.
- [3] Freeman ER, Bloom DA, McGuire EJ. A brief history of testosterone. *The Journal of Urology* 2001;165(2):371-3.

- [4] Wade N. Anabolic steroids: doctors denounce them, but athletes aren't listening. *Science* 1972;176(4042):1399-403.
- [5] American Academy of Pediatrics. Adolescents and anabolic steroids: a subject review. American Academy of Pediatrics. Committee on Sports Medicine and Fitness. *Pediatrics* 1997;99(6):904-8.
- [6] Buckley WE, Yesalis CE 3rd, Friedl KE, et al. Estimated prevalence of anabolic steroid use among male high school seniors. *JAMA* 1988;260(23):3441-5.
- [7] Kanayama G, Boynes M, Hudson JI, et al. Anabolic steroid abuse among teenage girls: an illusory problem? *Drug Alcohol Depend* 2007;88(2-3):156-62.
- [8] Kanayama G, Pope HG Jr. History and epidemiology of anabolic androgens in athletes and non-athletes. *Mol Cell Endocrinol* 2018;464:4-13.
- [9] El Scheich T, Weber AA, Klee D, et al. Adolescent ischemic stroke associated with anabolic steroid and cannabis abuse. *J Pediatr Endocrinol Metab JPEM* 2013;26(1-2):161-5.
- [10] Santamarina RD, Besocke AG, Romano LM, et al. Ischemic stroke related to anabolic abuse. *Clin Neuropharmacol* 2008;31(2):80-5.
- [11] Urhausen A, Albers T, Kindermann W. Are the cardiac effects of anabolic steroid abuse in strength athletes reversible? *Heart Br Card Soc* 2004;90(5):496-501.
- [12] Ip EJ, Yadao MA, Shah BM, et al. Infectious disease, injection practices and risky sexual behavior among anabolic steroid users. *AIDS Care* 2016;28(3):294-9.
- [13] Bonetti A, Tirelli F, Catapano A, et al. Side effects of anabolic androgenic steroids abuse. *Int J Sports Med* 2008;29(8):679-87.
- [14] Liu PY, Swerdloff RS, Christenson PD, et al. Rate, extent and modifiers of spermatogenic recovery after hormonal male contraception: an integrated analysis. *Lancet* 2006;367(9520):1412-20.
- [15] Torres-Calleja J, González-Unzaga M, DeCelis-Carrillo R, et al. Effect of androgenic anabolic steroids on sperm quality and serum hormone levels in adult male bodybuilders. *Life Sci* 2001;68(15):1769-74.
- [16] Calzada L, Torres-Calleja J, Martinez JM, et al. Measurement of androgen and estrogen receptors in breast tissue from subjects with anabolic steroid-dependent gynecomastia. *Life Sci* 2001;69(13):1465-9.
- [17] Orlandi MA, Venegoni E, Pagani C. Gynecomastia in two young men with histories of prolonged use of anabolic androgenic steroids. *J Ultrasound* 2010;13(2):46-8.
- [18] Scott MJ 3rd, Scott AM. Effects of anabolic-androgenic steroids on the pilosebaceous unit. *Cutis* 1992;50(2):113-6.
- [19] Baker J. A report on alterations to the speaking and singing voices of four women following hormonal therapy with virilizing agents. *J Voice* 1999;13(4):496-507.
- [20] National Institute on Drug Abuse Research Report – Steroid Abuse and Addiction. National Institutes of Health Publication No. 00-3721. Bethesda: National Institutes of Health, 2000.
- [21] Hartgens F, Kuipers H. Effects of androgenic-anabolic steroids in athletes. *Sports Med* 2004;34(8):513-54.
- [22] Friedl KE. Effects of anabolic steroids on physical health. In: Yesalis CE, edr. *Anabolic steroids in sport and exercise*. Champaign: Human Kinetics 1993: p. 107-50.
- [23] Reents S. Androgenic-anabolic steroids. In: *Sport and exercise pharmacology*. Champaign: Human Kinetics 2000: p. 161-81.
- [24] Juhn M. Popular sports supplements and ergogenic aids. *Sports Med* 2003;33(12):921-39.
- [25] Maravelias C, Dona A, Stefanidou M, et al. Adverse effects of anabolic steroids in athletes: a constant threat. *Toxicol Lett* 2005;158(3):167-75.