

MANAGEMENT OF UNSTABLE INTERTROCHANTERIC FRACTURE BY PROXIMAL FEMORAL NAILSidharth Yadav¹, Anil V. Golhar², Ritul Agrawal³**HOW TO CITE THIS ARTICLE:**

Sidharth Yadav, Anil V. Golhar, Ritul Agrawal. "Management of Unstable Intertrochanteric Fracture by Proximal Femoral Nail". Journal of Evolution of Medical and Dental Sciences 2014; Vol. 3, Issue 15, April 14; Page: 4084-4102, DOI: 10.14260/jemds/2014/2403

ABSTRACT: Fractures of the intertrochanteric region are most commonly occurring fractures of proximal femur. Intertrochanteric fractures are disabling injuries frequently occur in elderly population and also in young. The incidence has increased due to the advancing age of the population and high energy trauma in younger population. In earlier days these fractures were managed conservatively either by non-rotating boot or upper tibial Steinman pin traction for 6-8 weeks. Thus because of prolonged immobilization complications like deep vein thrombosis, hypostatic pneumonia, pressure sores, dehydration etc. increased the morbidity and mortality. In addition fracture healing was generally accompanied by varus deformity and shortening of the hip because of the inability of traction to counteract effectively the deforming muscular forces. **Indications for nonoperative treatment are:** (a) An elderly person whose medical condition carries an excessively high risk of mortality from anaesthesia and surgery. (b) Non ambulatory patient who has minimal discomfort following fracture. (c) Undisplaced stable 2 part fracture (relative). Intertrochanteric fractures are almost always treated by early internal fixation, not because they fail to unite with conservative treatment (they unite quite readily) but (a) To obtain best possible position and (b) To get the patient up and walking as soon as possible and thereby reducing the complications associated with prolonged recumbency. Internal fixation is the treatment of choice for treating intertrochanteric fractures of femur as most of these fracture are highly unstable. Treatment of unstable fractures is difficult with conventional operative modalities & may result in complications like non-union, implant failure, malrotation deformity. Intertrochanteric fractures when treated with an intramedullary device (like PFN), the above mentioned complications can be reduced especially in unstable patterns. Also it is a closed technique, biology at fracture site is not disturbed. It allow earlier weight bearing and better rehabilitation. Thus the Proximal Femoral Nail (PFN) has increasing popularity in treatment of intertrochanteric fractures. **AIMS:** To study Intertrochanteric fractures of the femur & evaluate its results after its management by PFN. **OBJECTIVES:** 1. To achieve prompt union with normal alignment. 2. To get early mobilization, weight bearing and better Functional results. 3. To study the details of operative procedure of standard PFN. 4. To evaluate possible complications of standard PFN. **MATERIAL AND METHODS:** A randomized study of 30 patient of intertrochanteric fracture femur treated with proximal femoral nail (PFN) was done from June 2011 to August 2013. Results were critically assessed. Evans classification system was applied for evaluation. Serial radiographs were taken on an average at monthly interval to assess union. All patients in which PFN was used and who could be followed at least till union were considered. The study was prospective. **RESULTS:** We included 30 patients of intertrochanteric fracture of unstable type in our study. The mean age of patients in our study was 68 yrs with domestic fall as the mode of trauma in majority of cases. The mean time for radiological union signs was 12.93 wks. The mean Pre injury Lower extremity functional score (LEFS) was 69.86 and at 12 mths the mean score was 66.73.

ORIGINAL ARTICLE

CONCLUSION: Proximal femoral nail (PFN) is a useful modality for treating unstable intertrochanteric fractures with lesser operating time, lesser blood loss, early weight bearing and less chances of complications. We would like to recommend PFN as a modality of treatment for such fractures. Long term randomized controlled trials are needed to establish superiority of this implant over dynamic hip screw.

KEYWORDS: Unstable intertrochanteric fracture, Pfn (Proximal Femoral Nail), Functional outcome.

INTRODUCTION: Intertrochanteric fractures of femur is defined as fractures involving upper end of femur through and in between both trochanters with or without extension into upper femoral fragment.

The incidence has increased significantly during recent years due to the advancing age of the population. In young individuals, the injury results from high energy trauma, whereas in the elderly group, most of the fractures resulting from the trivial fall are because of osteoporosis.¹

Before the advent of the term osteoporosis Sir Astley Cooper² (1824) wrote "That regular decay of nature which are easily detected in the body and one of the principal of these is found in the bones, for they become thin in their shell and spongy in their texture." This osteoporosis of the bones is main feature leading to this fracture.

In earlier days these fractures were managed conservatively either by non-rotating boot or upper tibial Steinman pin traction for 6-8 weeks. Thus because of prolonged immobilization complications like deep vein thrombosis (DVT), hypostatic pneumonia, pressure sores, dehydration etc. increased the morbidity and mortality. In addition fracture healing was generally accompanied by varus deformity and shortening of the hip because of the inability of traction to counteract effectively the deforming muscular forces.

Indications for non-operative treatment are:-

- a) An elderly person whose medical condition carries an excessively high risk of mortality from anaesthesia and surgery.
- b) Non ambulatory patient who has minimal discomfort following fracture.
- c) Undisplaced stable 2 part fracture (relative).

This led to the era of internal fixation of intertrochanteric fractures. Intertrochanteric fractures are almost always treated by early internal fixation, not because they fail to unite with conservative treatment (they unite quite readily) but

- a) To obtain best possible position and
- b) To get the patient up and walking as soon as possible and thereby reducing the complications associated with prolonged recumbency.³

Internal fixation is the treatment of choice for treating intertrochanteric fractures of femur as most of these fractures are highly unstable. These are treated by various methods, Dynamic Hip Screw (DHS) being the gold standard for intertrochanteric fractures.⁴

As with the recent advances in the surgical field, new treatment modalities are developing for treatment of intertrochanteric fractures. One such recent treatment modality is Proximal Femoral Nail (PFN) devised by AO/ASIF group in 1996 has proven to be a promising implant in peritrochanteric, intertrochanteric or subtrochanteric femoral fractures.⁵

ORIGINAL ARTICLE

Intertrochanteric fractures when treated with an intramedullary device (like PFN); the above mentioned complications can be reduced especially in unstable patterns. It allows earlier weight bearing and better rehabilitation. Thus the Proximal Femoral Nail (PFN) has increasing popularity in treatment of intertrochanteric fractures.

The major aim of using PFN is bringing the neck and head into correct relationship with the femoral shaft, in essence, to restore length, correct neck shaft angle and avoid rotational deformity.

Biomechanically, compared to a lateral fixed side plate device, an intramedullary device decreases the forces of hip joint on implants by 25 to 30%. This has advantage especially in elderly patients, in whom the primary goal is early weight bearing and mobilization. The proximal femoral nail has an additional anti-rotational screw (hip pin) placed in the femoral neck to avoid rotation during the weight bearing.⁷

In this present study we will be assessing the results of difficulties, pitfalls, complications faced while surgically treating 30 such cases. The study restricts itself to fractures in adults. The study was prospective.

AIMS AND OBJECTIVES:

AIMS:

1. To study Intertrochanteric fractures of the femur and evaluate its results after its management by PFN.

OBJECTIVES:

1. To achieve prompt union with normal alignment.
2. To get early mobilization, weight bearing and better Functional results.
3. To study the details of operative procedure of standard PFN.
4. To evaluate possible complications of standard PFN.

Classification of Intertrochanteric Fracture: As emphasized by JENSEN⁸, a classification system must serve two functions. First, it must relate the possibility of obtaining a primary stable and anatomical fracture reduction. Second, it must allow the surgeon to predict the risk of secondary loss of reduction following internal fixation. Several classification systems have been proposed.

BOYD & GRIFFIN⁹: presented a classification system based on the case of obtaining and maintaining fracture reduction. They divided intertrochanteric fractures into four types.

EVANS presented a simpler classification based on dividing fractures into stable and unstable groups. He further divided the unstable fractures into those in which stability could be restored by anatomical or near anatomical reduction and those in which anatomical reduction would not create stability. Evan's system was refined by.

EVANS CLASSIFICATION: Classification system based on the stability of the fracture pattern and the potential to convert and an unstable fracture pattern to a stable reduction.

He has divided the fractures into two main types depending on the direction of the fracture.

ORIGINAL ARTICLE

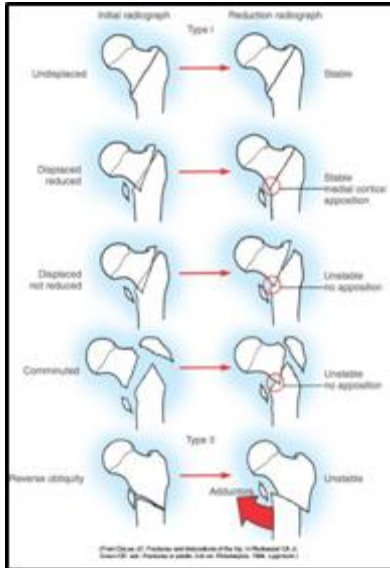


Fig 1: Shows Evan's Classification

MATERIAL AND METHODS: A randomized study of 30 patient of intertrochanteric fracture femur treated with proximal femoral nail (PFN) was done from June 2011 to August 2013. Results were critically assessed.

Evans classification system was applied for evaluation.

Serial radiographs were taken on an average at monthly interval to assess union.

Early ambulation was encouraged depending upon pain threshold, type of fracture.

All patients in which PFN was used and who could be followed at least till union were considered. The study was prospective.

Preoperative Evaluation: On admission detail history of the patient was taken into consideration including mechanism of injury, associated injuries, medical illness, preinjury status. Detailed examination of the fracture limb, status of skin and soft tissue was carried out.

The general condition was built up if necessary and complications of recumbency prevented, as far as possible with good nursing care. Anesthetic and physician fitness was taken. Standard anteroposterior view of pelvis with both hip joints and lateral view of affected side were taken in all cases to know accurately fracture geometry and type.

OPERATIVE TECHNIQUE: A fracture table was used for all the cases. Following suitable anesthesia patient was place supine on fracture table. Patient's injured leg was placed in neutral or adduction with 10-15 degree of internal rotation and uninjured leg placed in flexion and abduction as far as possible to accommodate the image intensifier.

Closed reduction was carried out in all patients. All steps of reduction were carried out under image intensifier television control. If reduction is not achieved by closed methods then open reduction has to be performed.

ORIGINAL ARTICLE

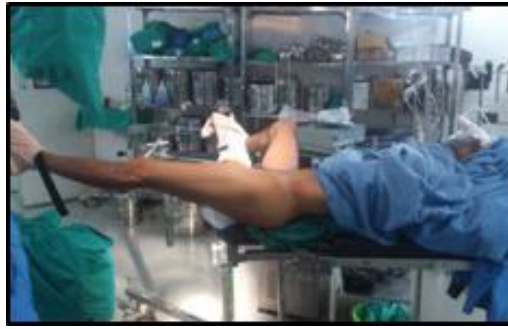

Fig. 2: Patient position on fracture table

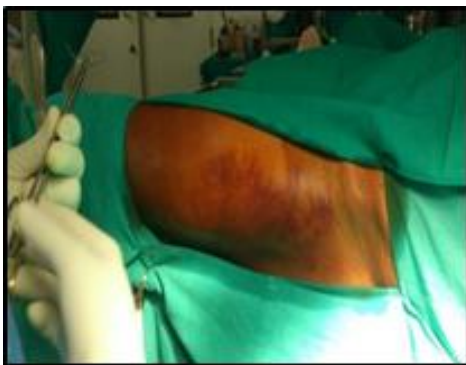

Fig. 3: Draping

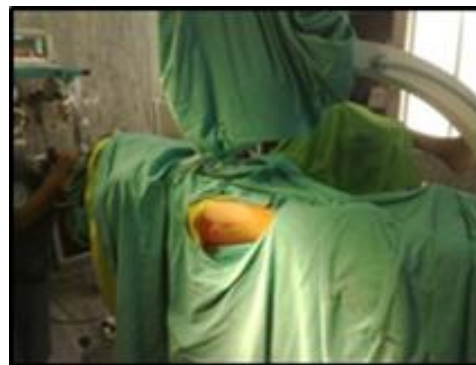

Fig. 4: C Arm Position

The tip of greater trochanter was located & 5 cms longitudinal incision was taken proximal from tip of trochanter. Entry point was taken with the help of curved awl. Awl was driven into cancellous bone till medullary canal was opened. Proximal cannulated reamer was used to open the proximal portion of femur to 14 mm to accommodate the proximal portion of nail (14 mm).

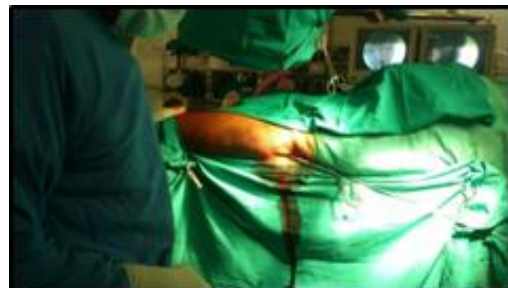

Fig. 5: Proximal Femoral Rimming

Nail, selected as per preoperative planning gently pushed through the trochanter region and across the fracture area under Image Intensifier using gentle twisting movements of handle. Proximal and distal screws were inserted through the insertion handle. Distal locking was done in most of the cases with single locking bolt.

ORIGINAL ARTICLE

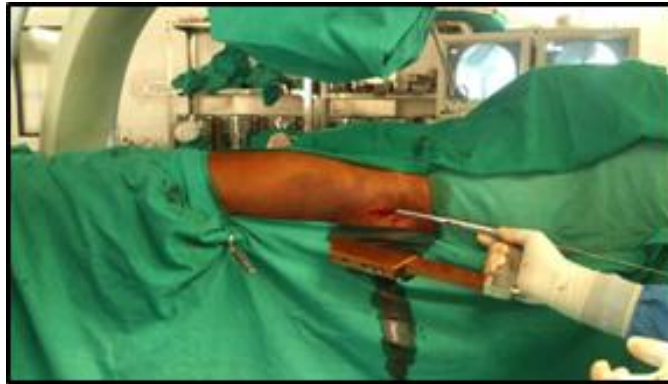

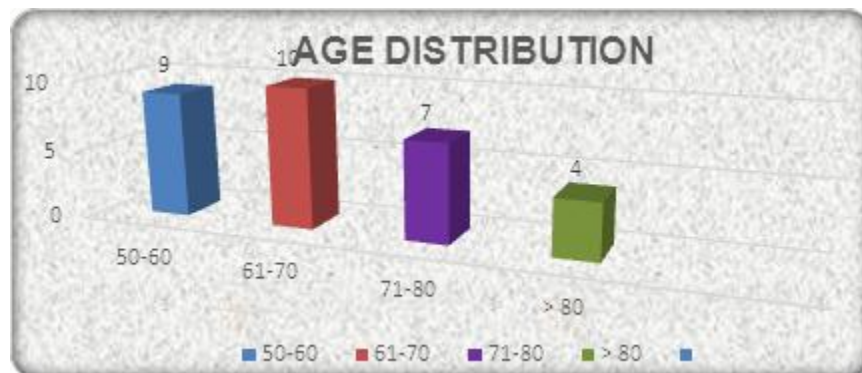
Fig. 6: Nail Insertion

OBSERVATIONS AND RESULTS: The present prospective, randomized study was conducted in the Department of Orthopedics, at our institute from June 2011 to August 2013. A total of 30 patients of intertrochanteric fracture femur treated with proximal femoral nail (PFN) were included in the study. All patients in which PFN was used and who were followed at least till clinicoradiological union were considered. The following observations were made:

AGE DISTRIBUTION:

Age range	No. of patients	Percentage
50-60	9	30%
61-70	10	33.33%
71-80	7	23.33%
>80	4	13.33%
Mean±SD	68.26±9.82	
Range	50-87	

TABLE 1

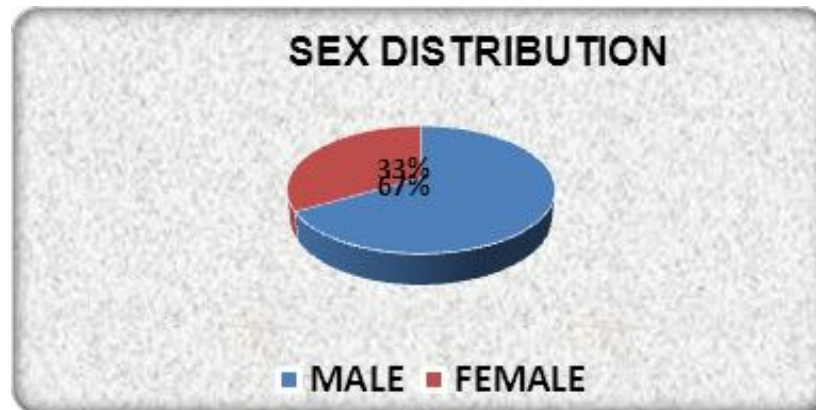


ORIGINAL ARTICLE

SEX DISTRIBUTION:

Sex	No. of patients	Percentage
Male	20	67%
Female	10	33%

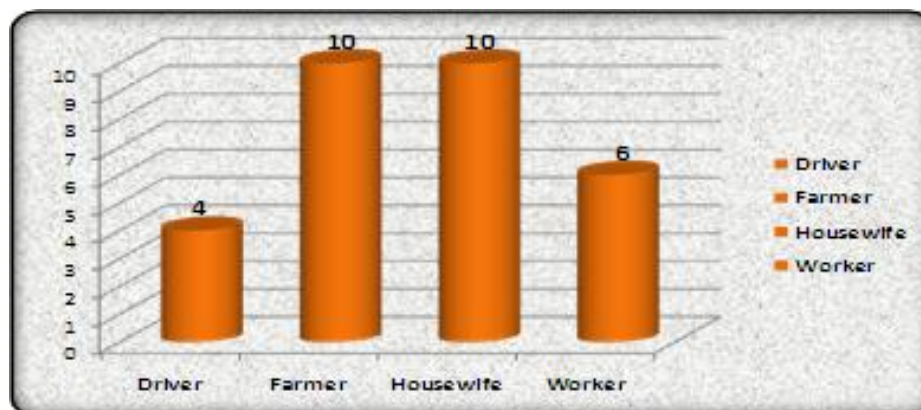
TABLE 2



OCCUPATION WISE DISTRIBUTION:

Occupation	No. of patients	Percentage
Driver	4	13.33%
Farmer	10	33.33%
Housewife	10	33.33%
Worker	6	20%

TABLE 3

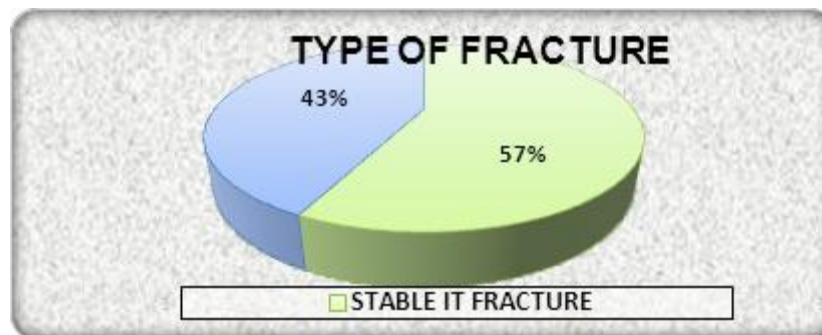


ORIGINAL ARTICLE

DIAGNOSIS AND TYPE OF FRACTURE:

Diagnosis and type	No. of patients	Percentage
Fracture IT unstable	30	43%
Fracture IT stable	40	57%
Total	70	

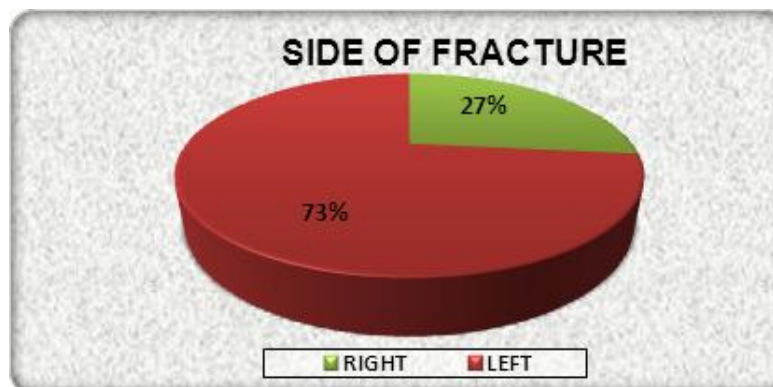
TABLE 4



SIDE OF FRACTURE:

Side	No. of patients	Percentage
Left	22	73%
Right	8	27%

TABLE 5

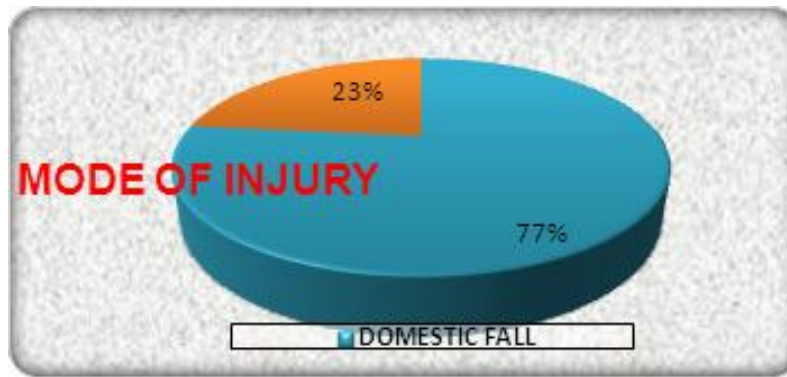


MODE OF INJURY:

Mode of injury	No. of patients	Percentage
Domestic fall	23	77%
Road traffic accident	7	23%

TABLE 6

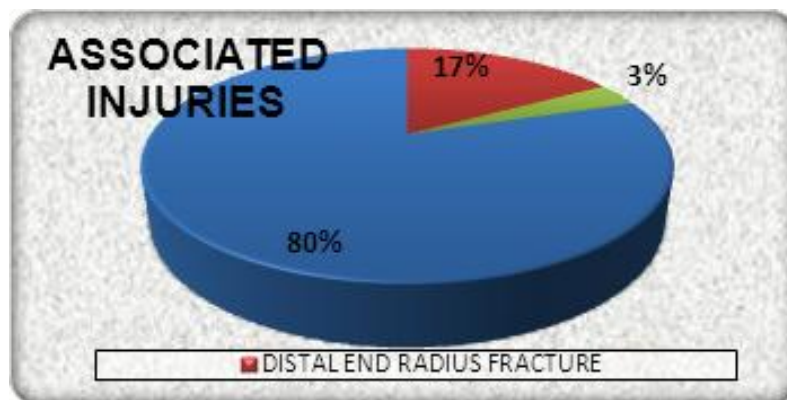
ORIGINAL ARTICLE



ASSOCIATED INJURY:

Associated injury	No. of patients	Percentage
DER	5	17%
Head injury	1	3%
Nil	24	80

TABLE 7

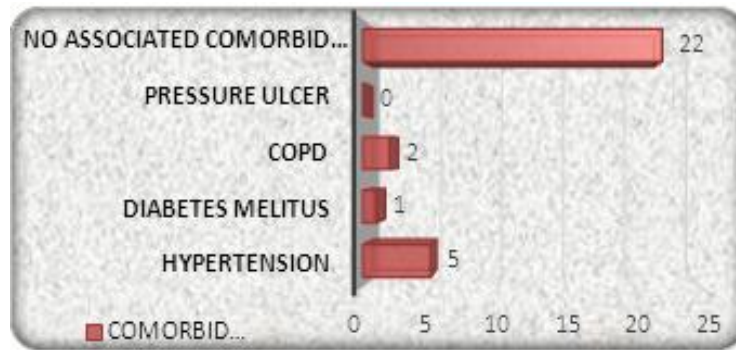


COMORBID CONDITION:

Comorbid condition	No. of patients	Percentage
Chronic obstructive pulmonary disease	2	7%
Diabetes mellitus	1	3%
Hypertension	5	17%
Nil	22	73%

TABLE 8

ORIGINAL ARTICLE



DURATION OF SURGERY:

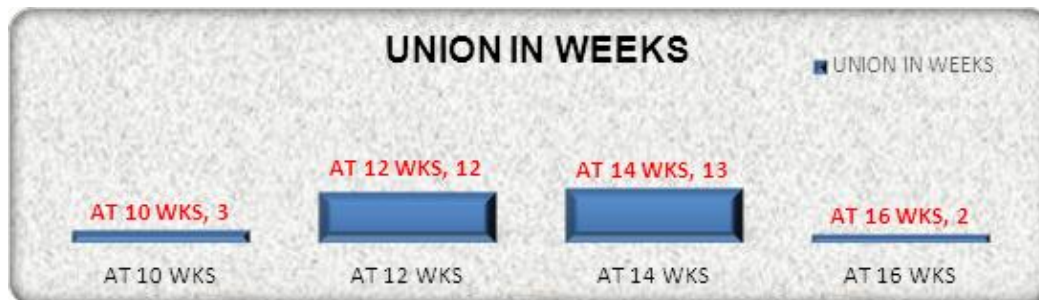
Mean duration (In minutes)	No. of patients	Percentage
55.66±13.81	30	100%

TABLE 9

TIME OF UNION:

Time to union (weeks)	No. of patients	Percentage
10 weeks	3	10%
12 weeks	12	40%
14 weeks	13	43%
16 weeks	2	7%
Mean time	12.93±1.55	100%

TABLE 10

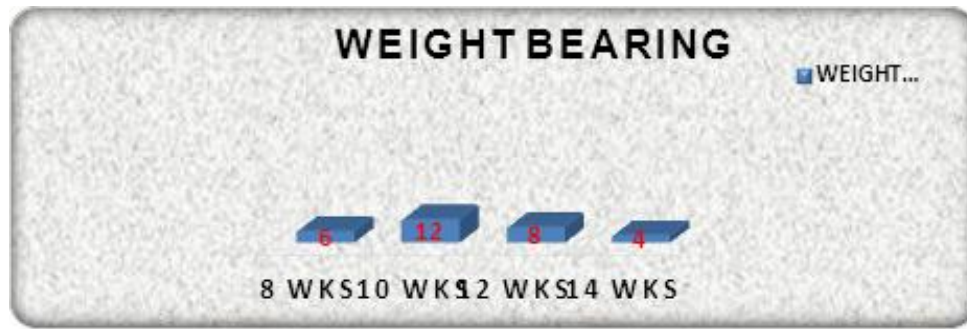

TIME TAKEN FOR WEIGHT BEARING:

Weight bearing(weeks)	No. of patients	Percentage
8 weeks	6	20%
10 weeks	12	40%
12 weeks	8	27%
14 weeks	4	13%

Table 11

ORIGINAL ARTICLE



HOSPITAL STAY:

Hospital Stay (in days)	No. of patients	Percentage
Upto 11 days	20	67%
13 days	4	13%
15 days	2	7%
>15 days	4	13%
Mean±SD	12.43±2.47	
Range	11-20	

TABLE 12

BLOOD LOSS:

Blood loss (in ml)	No. of patients	Percentage
60 ml	17	57%
70 ml	3	10%
80 ml	3	10%
90 ml	3	10%
100 ml	2	7%
110 ml	1	3%
120 ml	1	3%
Mean±SD	72.33±17.55	
Range	60-120	

TABLE 13

COMPLICATIONS:

Complications	No. of patients	Percentage
Nil	24	80%
Screw cut out	1	3%
Z effect	2	7%
Superficial infection	2	7%
Shortening	1	3%

TABLE 14

ORIGINAL ARTICLE

MORBIDITY/ MORTALITY:

	No. of patients	Percentage
Within 1 year	No death	100%
After 1 year	3	10%

TABLE 15

DISTRIBUTION OF CASES ACCORDING TO LOWER EXTREMITY FUNCTIONAL SCALE (LEFS): At the time of enrolment, we evaluated the pre injury lower extremity functional scale (LEFS) of every patient in the present study. The distribution of cases as per LEFS is as under:

Pre injury Lower Extremity Functional Scale:

LEFS	No. of patients	Percentage
Upto 60	7	23%
61-70	8	27%
71-80	15	50%
Mean±SD	69.86±9.52	
Range	45-80	

TABLE 16

From the above table, it is clearly shows that at the time of enrolment we found 7 (23%) patients with an LEFS score upto 60; 8 (27%) upto 61-70 and majority of patients i.e. 15 (50%) had a range of 71-80 LEFS. Mean LEFS was 69.86±9.52 with a range of 45-80.

COMPARISON OF MEAN LEFS SCORE BEFORE TRAUMA AND AFTER 3/6/12 MONTHS REVIEW:

In the present study, at the time of admission and after postoperative period; we found no change in functional score. We reviewed our cases at 3 months; 6 months and 12 months interval and the following results were found.

	Before trauma	After 3 months
LEFS	69.86±9.52	35.03±8.37
Spearman correlation	r -0.295; p=0.113 (p>0.05) Not significant	

TABLE 17: At 3 months review

When we evaluated our cases after 3 months period, we found that before trauma mean LEFS was 69.86±9.52 and after 3 months it was 35.03±8.37. When we compared mean LEFS before and after 3 months statistically by using Spearman Correlation of Coefficient (r value) it was found to be not significant.

	Before trauma	After 6 months
LEFS	69.86±9.52	50.6±10.54
Spearman correlation	r -0.183; p=0.334 (p>0.05) Not significant	

TABLE 18: At 6 months review

ORIGINAL ARTICLE

When we evaluated our cases after 6 months period, we found that before trauma mean LEFS was 69.86 ± 9.52 and after 6 months it was 50.6 ± 10.54 . When we compared mean LEFS before and after 6 months statistically by using Spearman Correlation of Coefficient (r value) it was found to be not significant.

	Before trauma	After 12 months
LEFS	69.86 ± 9.52	66.73 ± 10.34
Spearman correlation	r -0.139; p=0.464 (p>0.05) Not significant	

TABLE 19: At 12 months review

When we evaluated our cases after 12 months period, we found that before trauma mean LEFS was 69.86 ± 9.52 and after 12 months it was 66.73 ± 10.34 . When we compared mean LEFS before and after 12 months statistically by using Spearman Correlation of Coefficient (r value) it was found to be not significant.

COMPARISON OF MEAN LEFS SCORE AT DIFFERENT TIME INTERVALS DURING STUDY: In the present study, we also compared our cases during their follow up period i.e. 3 months; 6 months and 12 months. We reviewed our cases at 3 months; 6 months and 12 months interval and the following results were found.

	After 3 months	After 6 months
LEFS	35.03 ± 8.37	50.6 ± 10.54
Spearman correlation	r = 0.918; p <0.01 Significant	

TABLE 20: 3 months versus 6 months

When we evaluated our cases between 3 months and 6 months period, we found that at 3 months period LEFS score was 35.03 ± 8.37 and after 6 months it was 50.6 ± 10.54 . When we compared mean LEFS 3 months and 6 months statistically by using Spearman Correlation of Coefficient (r value); we found that there is significant difference between the means of two groups and it was found to be significant (p<0.01).

	After 6 months	After 12 months
LEFS	50.6 ± 10.54	66.73 ± 10.34
Spearman correlation	r = 0.931; p <0.01 Significant	

TABLE 21: 6 months versus 12 months

When we evaluated our cases between 6 months and 12 months period, we found that at 6 months period LEFS score was 50.6 ± 10.54 and after 12 months it was 66.73 ± 10.34 . When we compared mean LEFS 6 months and 12 months statistically by using Spearman Correlation of Coefficient (r value); we found that there is significant difference between the means of two groups and it was found to be significant (p<0.01).

ORIGINAL ARTICLE

	After 3 months	After 12 months
LEFS	35.03±8.37	66.73±10.34
Spearman correlation	r = 0.860; p <0.01 Significant	

TABLE 22: 3 months versus 12 months

When we evaluated our cases between 3 months and 12 months period, we found that at 3 months period LEFS score was 35.03±8.37 and after 12 months it was 66.73±10.34. When we compared mean LEFS 6 months and 12 months statistically by using Spearman Correlation of Coefficient (r value); we found that there is significant difference between the means of two groups and it was found to be significant (p<0.01).

DISCUSSION: Intertrochanteric fractures of femur are relatively common injuries among the elderly individuals. In order to reduce the morbidity and mortality associated with the conservative management of intertrochanteric fractures, surgical management of the intertrochanteric fractures is advocated as the best modality in managing these fractures.

In case of unstable intertrochanteric fractures the incidence of limb shortening, medialization of distal fragment, nonunion and implant cutouts is high. This led to development of intramedullary devices. These devices have the advantage of being an intramedullary fixation device, shorter lever arm of device causing less tensile strain on the implant, controlled fracture impaction due to incorporation of sliding screw, shorter operative duration and less soft tissue dissection.

During this study period 70 patients of intertrochanteric fractures presented in OPD and Casualty out of which 30 patents were diagnosed as unstable intertrochanteric fracture (type 2 Evan's) which were included in this study and were surgically managed by proximal femoral nail.

The fractures were classified by using Evan's classification which is widely accepted classification. The purpose of this study was to evaluate functional outcome of the management of unstable intertrochanteric fracture with proximal femoral nail.

Intramedullary nails are mainly recommended for unstable trochanteric fractures, subtrochanteric and reverse oblique fractures or pathological fractures.

Simmermacheret al¹² reported an overall technical failure rate of only 4.6% in a series of 191 fractures and no cases of mechanical complication.

In this study the average age was 68.26 years ranging from 20-84 years. Intertrochanteric fractures are common in elderly. The average age reported in other studies are as follows:

Series	Years	Average age (yrs.)
Schumpelick et al ¹³	1955	63
Riska E.B ¹⁴	1971	81.5
Sahlstrand ¹⁵	1974	75
Ecker et al ¹⁶	1975	75.1
Wolfgang ¹⁷	1982	73.2
Mohanty& chacko ¹⁸	1984	61.7
G.S.Kulkarni ¹⁹	1984	62
Kenzor et al ²⁰	1984	73

ORIGINAL ARTICLE

Parker et al ²¹	1996	79
T.S Sethi et al ²²	1993	61
Watson et al ²³	1998	76
Present study	2011	68

The male preponderance in our study is in contrast to the female preponderance as observed by various other authors.

Series	Year	Female %	Male %
Ecker et al ¹⁶	1975	484 (74%)	171 (26%)
Wolfgang ¹⁷	1982	185 (64.4%)	102 (35.6%)
G.S.Kulkarni ¹⁹	1984	76 (55%)	64 (45%)
Parker et al ²¹	1992	112 (57.7%)	82 (42.3%)
Lin-chih hwang ²⁴	2001	20 (30%)	46(70%)
Present study	2011	10 (33.33%)	20 (66.66%)

Male predominance as found in our study correlates with that of lin-chihhwang et al²⁴ in 2001.

Out of 30 patients 23 patient sustained injury by trivial fall (77%) such as fall at home, slipping in bathroom or missing a step. In 7 (23%) patients mode of injury was road traffic accident.

Series	Year	Incidence of trivial fall
Gupta R.C ²⁵	1974	79.4%
Ganz et al ²⁶	1979	70%
Hornby et al ²⁷	2006	55%
Present study	2011	77%

The average amount of blood loss was 72.33 ml (mean 72.33±17.55) which was comparable to other study.

Series	Year	Blood loss
Little et al ²⁸	2008	78
Present study	2011	72.33

The average time of surgery was 55.667 minutes. The operative time was comparable with other studies.

Series	Year	Operative time (in mins)
Hardy et al ²⁹	1998	71
Leung et al ³⁰	1992	53
Parjarinen et al ³¹	2005	55
Little et al ²⁸	2008	54
Present study	2011	55.67

ORIGINAL ARTICLE

Bed side mobilization and toe touch weight bearing was started from the next day of surgery. Fully weight bearing was started at 8 weeks except for 4 patients who were non-compliant in following the physiotherapy, due to increased communitation and other comorbid condition.

The mean period for Radiological union signs were 12.93 wks., in two patients radiological union was seen at 16 wks. All the patients in our study were subjected to lower limb functional score at 3 mths, 6 mths and 1 year. At the end of 1 yr. according to the patient and their carrier results were good or excellent as all patients were able to reach there pre injury level which was comparable with other studies.

There were Post-operative complications in 6 patients. Post-operative complications were in form of superficial infection, screw cut out, Z effect and shortening.

Comparison with other Studies:

	G.Alyssari ³²	Pavelka et al ³⁴	Menses et al ³³	MinosTylliankis ⁶	C Boldin et al ⁵	Present study
Bony union(wks)	100%	95%		97.7%	100%	100%
Z effect	-	-	0.8%	5 (11.1%)	3 (5.45%)	2 (7%)
Anatomic reduction	8 (11%)	95%	80%	-	34 (61.8%)	
Screw cut out	4 (8%)	4%	0.8%	2 (4.44%)	2 (3.6%)	1(3%)
Failure of fixation	5 (10%)	-	8 (17.77%)	7 (12.72%)	3 (7.5%)	-
Femoral fracture	1 (1.4%)	1.5%	1 (0.7%)	1 (2.22%)	-	-
Delayed union	-	5%	2%	2 (44.44%)	-	
Open reduction	2(2.8%)	-	-	3 (6.66%)	5 (10%)	-

J. Pajarinen et al³¹ did a randomized study comparing the post-operative rehabilitation and concluded that PFN when used for trochanteric fracture have positive effect on speed of restoration of walking when compared with DHS. Whereas a meta-analysis done by Xiao Huang et al³⁵ found both to be equally effective in treatment of trochanteric fractures.

Short comings of our study is small number of patients and shorter follow up. Comparative studies with other modalities of fixation are needed to establish the role of intramedullary devices in unstable intertrochanteric fractures of femur. Future research should focus on improvisation in implant design to prevent mechanical causes of implant failure.

To conclude Proximal femoral nail is useful device in treatment of unstable intertrochanteric fracture. It is relatively easy procedure and a biomechanical stable construct which allows early weight bearing.

SUMMARY AND CONCLUSION: Intertrochanteric fractures are the most disabling injuries in the elderly and are the leading cause of hospital admissions. This study was done to analyze the functional outcomes of unstable intertrochanteric fractures using proximal femoral nail.

We prospectively reviewed 30 cases of unstable intertrochanteric fractures managed surgically by proximal femoral nail. Fractures were classified as per Evans classification. The age of patients in present study ranged from 50-87 yrs., averaging 68.26 yrs. out of which 20 were males and 10 were females. 77% of cases were due to trivial fall and 23% due to road traffic accident. 7 patients (27%) had associated comorbid condition such as chronic obstructive pulmonary disease

ORIGINAL ARTICLE

(COPD), diabetes mellitus (DM), and hypertension (HT). The average amount of blood loss was in range of 60 to 120 ml. The average operating time was 56 mins (range 40 to 80 mins).

All the patients were reviewed at 3, 6 and 12 months post operatively. All patients were allowed to touch weight bearing from next day and average time of full weight bearing was 11 wks. Average time of radiological union was 12.93 wks. In our study we had 2 cases of z effect, 1 cases of screw cutout, 1 of shortening and 2 patients had superficial infection. There were no cases of implant failure such as breakage of nail, breakage of screw. We lost 3 patients in follow up because of death due to secondary reasons after 1 yr. of surgery. All the patients were able to reach there pre injury functional status at the end of this study.

Excellent clinical and radiological outcome has been reported with use of PFN for treatment of unstable intertrochanteric fractures. Finding in current study correlated with the literature in terms of operating time, blood loss, radiological union and functional outcome.

Proximal femoral nail (PFN) is a useful modality for treating unstable intertrochanteric fractures with lesser operating time, lesser blood loss, early weight bearing and less chance of complications. We would like to recommend PFN as a modality of treatment for such fractures. Long term randomized controlled trials are needed to establish superiority of this implant over dynamic hip screw.

BIBLIOGRAPHY:

1. Bucholz RW, Heckman JD, Court- Brown CM, Tornetta III P. Intertrochanteric Fracture. In: Rockwood and Green's Fracture in Adults Vol. 2. 7th ed.: Lippincott Williams & Wilkins; p1597-1640.
2. Stevens J, Freeman PA, Nordin BEC, Barnett E. The incidence of osteoporosis in femoral neck fractures. *J.B.J.S.*1962; 44B (3):520-527.
3. Solomon L, Warwick D, Nayagam S. Injuries of hip & femur. In: Apley's System of orthopaedics and fracture. 9th ed.; p853-858.
4. Kulkarni GS, Limaye R, Kulkarni M, Kulkarni S. Intertrochantric fracture Current Concept Review. *Indian Journal of Orthopaedics.* 2006; Vol 40(1):16-23.
5. Boldin C, Seibert FJ, Fankhauser F, Peicha G, Grechenig W, Szyskowitz R. The Proximal Femoral Nail (PFN) - a minimal invasive treatment of unstable proximal femoral fracture: A Prospective study of 55 patients with a follow up of 15 mths. *Acta Orthopaedic Scandinavica.* 2003; 74(1):53-58.
6. Tyllianakis M, Panagopoulous A, Papadopoulous A, Papisimos S, Mousafirir K. Treatment of extracapsular hip fractures with the proximal femoral nail (PFN): Long term results in 45 patients. *Acta Orthop Belg.* 2004; 70(5):444-454.
7. Morihara T, Aria Y, Tokugawa S, Fujita S, Chantani K, Kubo T. Proximal femoral nail for treatment of trochanteric femoral fracture. *Journal of Orthopaedic Surgery.* 2007; 15(3):273-7.
8. Jensen J.S. Classification of trochanteric fractures. *Acta Orthop Scand.* 1980; 51:803-810.
9. Boyd H.B, Griffin L.L. Classification and treatment of trochanteric fractures. *Arch Surg.* 1949; 58(6):853-866.
10. Tronzo RG. Fracture of hip in adults. In: *Surgery of hip joint.* 2nd ed.: springer; 1984. P 163-338.
11. Koval KJ, Zukerman JD. Intertrochanteric Fracture. In: *Hip Fracture: A Practical Guide to management.* Springer; 2000. p129-170.

ORIGINAL ARTICLE

12. Simmermacher RK, Bosch AM, Van der werken C. the AO/ASIF proximal femoral fracture. *Injury*.1999; 30(5):327-32.
13. Schumpelick W, JantezenPM. A new principle in the operative treatment of intertrochanteric fracture of the femur. *J Bone Joint Surg Am*. 1955; 37(4):693-698.
14. Riska EB. Intertrochanteric fracture of the femur. *Acta Orthopaedics* 1971; 42:268-280.
15. Sahlstrand T. The Richard compression screw and sliding hip screw system in the treatment of intertrochanteric fractures. *Acta Orthopaedica Scandinavica*.1974; 45(2):213-9.
16. Ecker ML, Joyce JJ 3rd, Kohl EJ. Treatment of intertrochanteric fractures using a compression screw. *J Bone Joint Surg Am*. 1975; 57(1):23-7.
17. Wolfgang GL, Bryant MH, O'Neill JP. Treatment of intertrochanteric fractures of the femur using sliding plate fixation. *Clinical Orthopaedics and Related Research*. 1982; (163):148-158.
18. Mohanty SP and Chacko V. A comparative analysis of operative and non-operative management of intertrochanteric fracture. *Indian Journal of Orthopaedics* 1984; 18(1):19-24.
19. Kulkarni GS. Treatment of intertrochanteric fracture of hip by modified Richards's compression and collapsing screw. *Indian Journal of Orthopaedics* 1984;18(1):30-34.
20. Kenzora JE, McCarthy RE, Lowell JD, Sledge CB. Hip fracture mortality: relation to age, treatment, preoperative illness time of surgery and complication. *Clinical Orthopaedics and Related Research* 1984; (186):45-56.
21. Parker MJ. Trochanteric hip fracture. *Acta Ortho Scand* 1996; 67(4):329-332.
22. Sethi TS. Dynamic hip screw in intertrochanteric fractures. *IJO* 1993; 27(2):161-165.
23. Watson JT, Moed BR, Cramer KE, Karges DE. Comparison of the compression hip screw with Madoff sliding plate for intertrochanteric fracture: A Randomized prospective study. *Clinical Orthopaedic and Related Research* 1998; 348:79-86.
24. Hwang LC, Lo WH, Chen WM, Lin CF, Huang CK, Chen CM. Intertrochanteric fracture in adults younger than 40 yrs. *Arch Orthop Trauma Surg*. 2001;121(3):123-6.
25. Gupta RC. Conservative treatment of intertrochanteric fracture of femur. *Indian Journal of Orthopaedics* 1974; 36(6):229.
26. Ganz R, Thomas RJ, Hammerle CP. Trochanteric fracture of femur treatment and results. *Clin Orthop Relat Res*. 1979; (138):30-40.
27. Hornby R, Evans JG, Vardon V. Operative or conservative treatment for trochanteric fractures of the femur. A randomised epidemiological trial in elderly patients. *J Bone Joint Surg Br*. 1989; 71(4):619-623.
28. Little NJ, Verma V, Fernando C, Elliott DS, Khaleel A. A prospective trial comparing the Holland nail with the dynamic hip screw in the treatment of intertrochanteric fractures of the hip. *J Bone Joint Surg Br*. 2008; 90(8):1073-8.
29. Hardy DC, Descamps PY, Krallis P, Fabeck L, Smets P, Bertens CL, Delince PE. Use of an intramedullary hip screw compared with a compression hip screw with a plate for intertrochanteric femoral fractures. A prospective randomized study of one hundred patients. *J Bone Joint Surg Am*. 1998; 80(5):618-30.
30. Leung KS, So WS, Shen WY, HuiPW. Gamma nails and dynamic hip screws for pertrochanteric fractures. A randomized prospective study in elderly patients. *J Bone Joint Surg Br*. 1992; 74(3):345-51.

ORIGINAL ARTICLE

31. Pajarinen J, Lindahl J, Michelsson O, Savolainen V, Hirvensalo E. Pertrochanteric femoral fractures treated with a dynamic hip screw or a proximal femoral nail: a randomized study comparing post-operative rehabilitation. *J Bone Joint Surg Br.* 2005; 87(1):76-81.
32. Al-yassari G, Langstaff RJ, Jones JW, Al-Lami M. The AO/ASIF proximal femoral nail for the treatment of unstable trochanteric femoral fracture. *Injury.* 2002; 33(5):395-9.
33. Menezes DF, Gamulin A, Noesberger B. Is the proximal femoral nail a suitable implant for treatment of all trochanteric fracture. *Clin Orthop Relat Res.* 2005; (439):221-7.
34. Pavelka T, Kortus J, Linhart M. Osteosynthesis of proximal femoral fractures using short proximal femoral nails. *Acta Chir Orthop Traumatol Cech.* 2003; 70(1):31-8.
35. Huang X, Leung F, Xiang Z, Tan PY, Yang J, Wei DQ et al. Proximal femoral nail versus dynamic hip screw fixation for trochanteric fractures: a meta-analysis of randomized controlled trials. <http://www.ncbi.nlm.nih.gov/pubmed/23533361> (accessed 16/12/2013).

AUTHORS:

1. Sidharth Yadav
2. Anil V. Golhar
3. Ritul Agrawal

PARTICULARS OF CONTRIBUTORS:

1. Resident, Department of Orthopaedics, NKPSIMS & Lata Mangeshkar Hospital, Nagpur.
2. Professor and HOD, Department of Orthopaedics, NKPSIMS & Lata Mangeshkar Hospital, Nagpur.
3. Resident, Department of Orthopaedics, NKPSIMS & Lata Mangeshkar Hospital, Nagpur.

NAME ADDRESS EMAIL ID OF THE CORRESPONDING AUTHOR:

Dr. Sidharth Yadav,
S/o Jitender Kumar Yadav,
C/o Kalawati Hospital,
Model Town, Rewari – 123401, Haryana.
E-mail: sidharthyadav29@gmail.com

Date of Submission: 06/03/2014.
Date of Peer Review: 07/03/2014.
Date of Acceptance: 26/03/2014.
Date of Publishing: 14/04/2014.