

# CASE REPORT

---

## A CASE REPORT - AMYAND'S HERNIA

Shekappa C. Malagimani<sup>1</sup>, Yashwanth C.N<sup>2</sup>, Basavaraj Biradar Patil<sup>3</sup>, Pradeep Y.M<sup>4</sup>, Shivaprasad M<sup>5</sup>

### HOW TO CITE THIS ARTICLE:

Shekappa C. Malagimani, Yashwanth C.N, Basavaraj Biradar Patil, Pradeep Y.M, Shivaprasad M. "A case report - Amyand's hernia". Journal of Evolution of Medical and Dental Sciences 2013; Vol2, Issue 35, September 2; Page: 6754-6757.

**ABSTRACT:** Hernia is commonly operated in surgical department either emergency basis or as elective case. Unusual contents of hernia sac are uncommon, but are likely to be encountered by a surgeon in his career due to the frequency of hernia repair. The presence of vermiform appendix in inguinal hernias, referred to as Amyand's hernia, is rare occurring in about 1% of inguinal hernias. This is to present our experience of unusual contents in inguinal hernia sac. Amyand's hernia is not very often seen in the clinical practice and its pre-operative diagnosis is very difficult hence awareness of this disease condition is essential for pre-operative suspicion and even diagnosis of the condition.

**KEY WORDS:** Amyand's hernia, appendix

**INTRODUCTION:** Inguinal hernia repair is one of the commonest operations in surgical practice. However, when a surgeon encounters unusual content it could pose a difficulty in its management 1 2. The often encountered unusual contents are appendix, ovary, fallopian tubes, urinary bladder, colonic diverticulum, Meckel's diverticulum or persistent mullerian duct syndrome has been reported 1, 2. In 1735, Claudius Amyand first reported the presence of perforated appendicitis within an inguinal hernial sac. He performed trans herniotomy, appendicectomy, this being first ever appendicectomy reported in literature 3, 4. We are presenting a case of inguinal hernia with appendix as content treated with reduction of contents and hernioplasty in our hospital.

**CASE REPORT:** A 28 years old male came to out -patient department with a large globular, incomplete, irreducible, indirect inguinal hernia. It was considered as enterocele as the gut sounds were audible over the swelling. The contents reduced with gurgling but not completely. Laboratory tests are within normal levels.

**OPERATIVE FINDINGS:** Under spinal anaesthesia, Right transverse inguinal incision taken. On opening the sac the content found to be appendix and some part of terminal ileum. Appendix found to be normal. Contents reduced completely and hernioplasty done. Patient tolerated the procedure well. Post operative period was uneventful.

## CASE REPORT

---

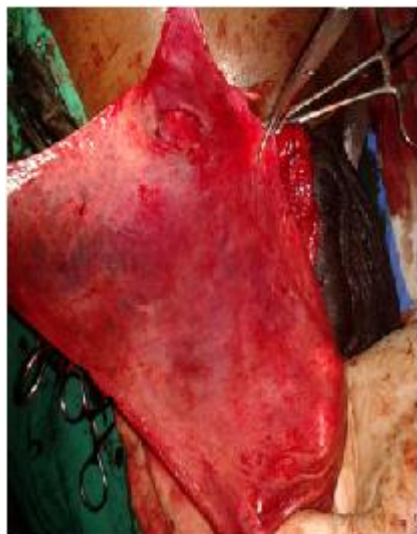

Fig-1: hernial sac

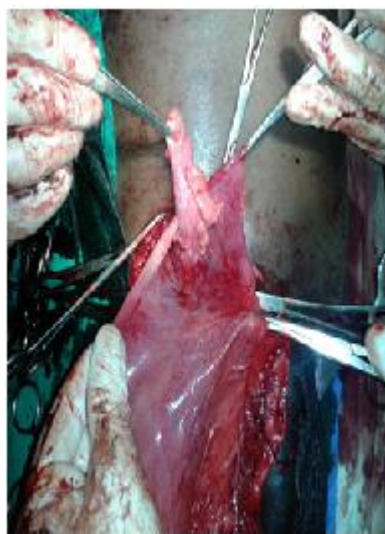


fig-2: appendix in hernial sac

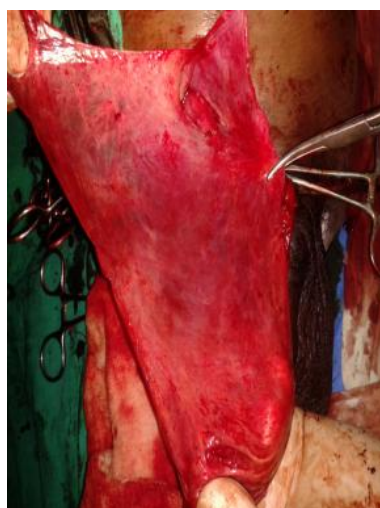

Fig-3: long hernial sac

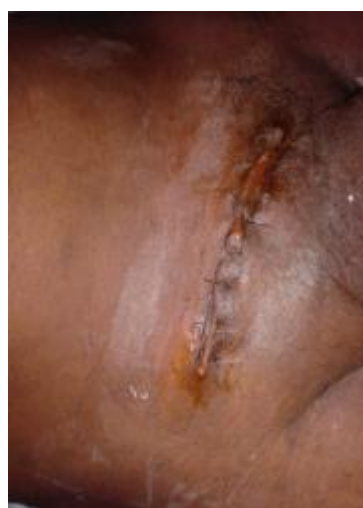

Fig-4: suture line at operated site

**DISCUSSION:** The term Amyand's hernia is used for depicting the condition of non inflamed appendix, inflamed appendix or perforated appendix within an inguinal hernia 5. The Amyand's hernia in adults is rare and with less than 1% prevalence. The incidence of having a normal appendix within the hernia sac varies from 0.5% to 1%, whereas only 0.1% of all cases, acute appendicitis is present in an inguinal hernia 6. Amyand's hernia is common in men and is almost exclusively right sided, most likely due to the usual anatomical position of the appendix, although there have been reports of left sided Amyand's hernia and in such cases there is usually an associated situs invertus, mobile caecum or intestinal malrotation 6.

Claudius Amyand (1680-1740) while operating at St. George's hospital, on 11yrs old boy with an inguinal hernia and a faecal fistula discharging in the groin found perforated appendicitis within the hernia sac. He performed appendicectomy; the patient recovered from faecal fistula but, the hernia recurred 4. Appendix within the hernia sac can be complicated by acute appendicitis 1, 7.

# CASE REPORT

---

Amyand's hernia is commonly misdiagnosed as an ordinary incarcerated hernia. Symptoms mimicking appendicitis may occur. Pre-operative diagnosis of hernial appendicitis is very difficult and when it occurs it is usually diagnosed as strangulated inguinal hernia 5. In case of Amyand's hernia, diagnosis is almost always made intra-operatively. Radio-imaging technique like USG and CT-scan may be helpful in pre-operative diagnosis but they are not always enough 9.

There is no standard protocol for the management of Amyand's hernia. Factors such as the presence of an inflamed appendix, contamination of the surgical field, patient age and anatomic features of the tissue are important determinants for appropriate surgery 10. Normal appendix can be returned back to peritoneal cavity as in this case or appendectomy done 4. Hernioplasty (mesh repair) without appendectomy is the favoured option in patients with a normal appendix.5. In this case appendix reduced and hernioplasty done without any post-operative complication. However, in cases of appendicitis, transherniotomy appendectomy should be performed followed by herniorrhaphy 3, 5, 11. The presence of pus or perforation is an absolute contraindication to hernioplasty 3.

**CONCLUSION:** Amyand's hernia is rare entity. Surgery is the only modality of treatment. Although pre-operative diagnosis of Amyand's hernia is very difficult but awareness of this condition will definitely help in pre-operative suspicion of the disease and even early diagnosis because acute appendicitis is always a dire condition. Being aware of this possibility, along with the appropriate management would ensure better outcome in these patients.

## REFERENCES:

1. Gurer, M. Ozdogan, N. Ozlem, A. Yildirim, H. Kula-coglu and R. Aydin, "Uncommon Content in Groin her-nia Sac," *Hernia*, Vol. 10, No. 2, 2006, pp. 152-155.
2. K. Ballas, T. H. Kontoulis, C. H. Skouras, A. Triantafyl-lou, N. Symeonidis, T. H. Pavlidis, et al., "Unusual Findings in Inguinal Hernia Surgery. Report of 6 Rare Cases," *Hippokratia*, Vol. 13, No. 3, 2009, pp. 169-171.
3. Anagnostopoulou S, Dimitroulis D, Troupis TG, Allamani M, Paraschos A, Mazarakis A, NikiteasNI, Kostakis A. Amyand's hernia: A case report. *World J Gastroenterol* 2006; 12:4761-63.
4. Hutchinson R. Amyand's hernia. *J R Soc Med*1993; 86:104-5.
5. Sharma H, Gupta A, Shekhawat NS, Memon B, Memon M. Amyand's hernia: A report of 18 consecutive patients over a 15-year period. *Hernia*. 2007; 11:31-5.
6. Logan MT, Nottingham JM. Amyand's hernia: a case report of an incarcerated and perforated appendix within an inguinal hernia and review of the literature. *Am Surg*. 2001; 67:628-9.
7. Nigri G, Costa G, Valabrega S, Aurello P, D'Angelo F, Bellagamba R, Lauro A, Ramacciato G. A rare presentation of amyand's hernia. Case report and review of the literature. *Minerva Chir* 2008; 63:169-74.
8. D'Alia C, Lo Schiavo MG, Tonante A, Taranto F, Gagliano E, Bonanno L, et al . Amyand's hernia: case report and review of the literature. *Hernia*. 2003; 7:89-91.
9. Yagnik VD. Amyand's hernia. *J Indian Assoc Pediatr Surg*. 2012; 17(2):88.
10. Karatas A, Makay O, and Salihoglu Z. Can preoperative diagnosis affect the choice of treatment in Amyand's hernia? report of a case. *Hernia* 2008; 13: 225-7.

# CASE REPORT

---

11. Tisdale JB, Barwell NJ. Amyand's hernia and peri-appendicular abscess in primary care. *Hernia* 2008; 12:311-12.

## **AUTHORS:**

1. Shekappa C. Malagimani
2. Yashwanth C.N.
3. Basavaraj Biradar Patil
4. Pradeep Y.M.
5. Shivaprasad M.

## **PARTICULARS OF CONTRIBUTORS:**

1. Associate Professor, Department of Surgery, VIMS, Bellary.
2. PG Student, Department of Surgery, VIMS, Bellary.
3. Professor, Department of Surgery, VIMS, Bellary.

4. PG Student, Department of Surgery, VIMS, Bellary.
5. Professor, Department of Surgery, VIMS, Bellary.

## **NAME ADDRESS EMAIL ID OF THE CORRESPONDING AUTHOR:**

Dr. Shekappa C.M,  
B/24, Staff Quarters, VIMS (OPD),  
Cantonment, Bellary.  
Email – doc\_shekar@yahoo.com

Date of Submission: 26/08/2013.

Date of Peer Review: 27/08/2013.

Date of Acceptance: 28/08/2013.

Date of Publishing: 29/08/2013