

NEURILEMMOMA (SCHWANNOMA) OF UPPER EYELID

Arun Kumar Sinha¹, Ranjeet Kumar²

¹Associate Professor, Department of Ophthalmology, Patna Medical College and Hospital, Patna, Bihar, India.

²Junior Resident, Department of Ophthalmology, Patna Medical College and Hospital, Patna, Bihar, India.

HOW TO CITE THIS ARTICLE: Sinha AK, Kumar R. Neurilemmoma (schwannoma) of upper eyelid. J. Evolution Med. Dent. Sci. 2018;7(41):4481-4482, DOI: 10.14260/jemds/2018/999

PRESENTATION OF CASE

A 20-year-old young man came to Eye OPD of our hospital with a complaint of painless nodule which enlarged slowly for 1 year on his left upper eyelid in outer part and in between upper orbital margin and lid margin. He had no history of NF or any other nodule.

Neurilemmoma (Schwannoma) are benign, encapsulated tumours of the nerve sheath. Their cells of origin are thought to be Schwann cells derived from the neural crest. These masses usually arise from the side of a nerve, are well encapsulated and have a unique histological pattern. Schwannoma of ophthalmic interest is rare, although it has been reported in relation to the orbit and less frequently with uveal tract and conjunctiva.^{1,2,3,4} Instances of eyelid neurilemmomas are extremely rare. Here, we describe a case of eyelid schwannoma of 20 yr. young male patient with a solitary nodular cystic swelling in left upper eyelid. The diagnosis of schwannoma was made after the eyelid cystic mass with histopathologic reports and ultrasound B-scan.

This benign lesion essentially manifests itself with cosmetic deformity, a palpable mass, symptoms similar to a compressive neuropathy or combination of this. The cause of these neoplasm is unknown. Neurilemmoma can be associated with Von Recklinghausen disease, when the case presents as multiple tumours. Neurilemmoma is the most common neurogenic tumour. It represents 1% of all orbital tumours and 35% of peripheral nerve tumour. Mostly benign but may undergo malignant transformation in patients with neurofibromatosis. It is seen most commonly in young adults to middle aged individuals (20 - 50 years). No sex or racial predilection recognised.

Ocular Examination

On ocular examination, visual acuity was 6/6 both eyes. Slit-lamp examination and fundoscopy of both eyes were within normal limit. But there was a solitary nodular cystic swelling measuring 14 × 12 mm size in lateral side of left upper eyelid margin. The nodule was freely mobile, not fixed to underlying structure or with skin. The mass did not affect the movement of lid and did not cause dropping of involved eyelid.

'Financial or Other Competing Interest': None.

Submission 29-08-2018, Peer Review 21-09-2018,

Acceptance 27-09-2018, Published 08-10-2018.

Corresponding Author:

Ranjeet Kumar,

Junior Resident,

Department of Ophthalmology,

Patna Medical College and Hospital,

Patna, Bihar,

India.

E-mail: dr.ranjeetpmch@gmail.com

DOI: 10.14260/jemds/2018/999



DIFFERENTIAL DIAGNOSES

1. Inclusion cyst.
2. Chalazion.
3. Neurofibroma.
4. Lipoma.
5. Ganglion cyst.

CLINICAL DIAGNOSIS

As neurilemmoma can present in many locations, the clinical presentation can be varied. In most cases, while schwannoma is usually indicative of neurofibromatosis-2. Clinically, it presents as a slow growing, painless, well-defined solitary mass, usually in the superior orbit and is frequently confused with chalazion or inclusion cyst. It presents as slow growing masses remaining over long time. The tumour, though rare, can be present in both upper and lower eyelids.^{1,2,3,4} Orbital symptoms may include exophthalmos, diplopia and visual loss from optic nerve compression.

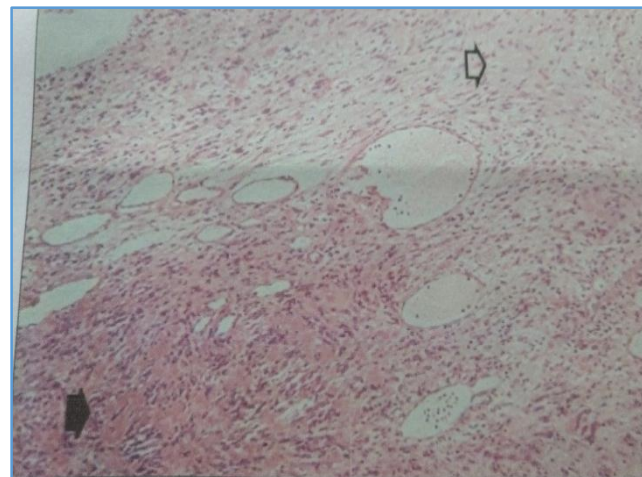


Figure 1. Histopathologic Slide of Left Upper Lid Cystic Swelling

The lesion was completely removed by shave excision under local anaesthesia. On microscopic examination, histopathologic bundles of spindle cell with no mitotic activity were observed. Immunohistochemical analysis revealed a strong positive reaction for S-100 Protein.

Biopsy may be needed to clearly define the tissue type. For bony lesions and for particularly large soft tissue lesions biopsy was prudent to ensure correct diagnosis and management. Whenever a biopsy is considered, strict biopsy guideline principle must be followed.

Imaging Studies

Plain Radiograph, CT Scan, MRI and USG for body part involvement.

Macroscopic View

They appear to be well demarcated, they usually grow very slowly and are asymptomatic.

HISTOPATHOLOGIC DISCUSSION**HISTOLOGICAL FINDINGS****There are Two Distinct regions as Follows-**

1. **Anthony A Pattern:** It shows fascicles and bundles of non-pigmented spindle cells with elongated band nuclei and abundant extracellular collagen with adipocytes and squamous cells. Spindle cells may palisade around eosinophilic regions that are Verocay bodies. They are positive for S-100 staining.
2. **Anthony B Pattern:** These are much less cellular and have a background of loose connective tissue that is myxomatous in appearance.

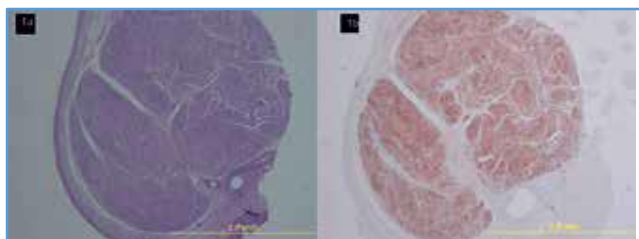


Figure 2. Histologic Analysis of Eyelid Schwannoma. Spindle Cells showing Palisading Pattern

Occasionally, more aggressive histological appearance may predominate, but such forms usually lack mitotic figures. The most important features in diagnosis remains the strong reactivity to S-100 protein by immunochemistry.

Staging

Neurilemmomas are Commonly Classified according to the Enneking System for Benign Lesions as Follows-

Grade 1: Inactive lesions.

Grade 2: Lesions that deform the surrounding tissue, but are not destructive or locally aggressive.

Grade 3: Lesions that are locally aggressive and may invade local tissues, but do not have metastatic potential.

DISCUSSION OF MANAGEMENT

Complete excision with clear margin to establish the histopathological diagnosis and prevent recurrence.

Incomplete removal is associated with eventual recurrence and more aggressive behaviour. There have been anecdotal reports of malignant changes in previously incompletely excised benign schwannoma. The swelling also tend to transgress tissue planes and grow rapidly on incomplete excision. An attempt to preserve nerve should be made, but this is not always possible and does not appear to have any major consequences at this site.

Most common complication of surgical treatment is neuroplexia; however, this neurological deficit can be permanent depending on the resection of neural tissue. Generally, patient tolerate resection well with complete and rapid relief of symptoms.

The prognosis for life is good, except following intracranial spread. Recurrence is unlikely after complete resection. Patients usually have rapid and complete relief of pain with excellent long-term results. In other locations, a poor prognosis have been described if the cells are fusiform and contains melanin granules or if epithelial cells are present. Nevertheless, the eyelid schwannoma has not been reported in schwannoma.

FINAL DIAGNOSIS

Schwannoma

It is a Schwann cell tumour that arises as an outpouching from peripheral or cranial nerve. It has a neural crest origin, representing 1% orbital tumour and 35% peripheral nerve tumours. These are mostly seen in young adults (20 - 50 years) and are slow growing, painless, well defined, solitary masses, usually seen in upper orbit and are frequently cystic.

REFERENCES

- [1] Touzri RA, Errais K, Zermani R, et al. Schwannoma of the eyelid: apropos of two cases. *Indian J Ophthalmol* 2009;57(4):318-20.
- [2] De Jong L, Demaerel P, Sciot R, et al. A patient with swelling of the eyelid: ancient schwannoma of the supraorbital nerve (2010:6b). *Eur Radiol* 2010;20(9):2301-4.
- [3] Shields JA, Guibor P. Neurilemoma of the eyelid resembling a recurrent chalazion. *Arch Ophthalmol* 1984;102(11):1650.
- [4] Patil SB, Kale SM, Jaiswal S, et al. Schwannoma of upper eyelid: a rare differential diagnosis of eyelid swellings. *Indian J Plast Surg* 2010;43(2):213-5.