

CASE REPORT

PERFORATING PILOMATRICOMA MIMICKING BREAST CARCINOMA IN AN ADULT MALE

Mark Ruth Prasanna¹, Nalini Calton²

HOW TO CITE THIS ARTICLE:

Mark Ruth Prasanna, Nalini Calton. "Perforating Pilomatricoma Mimicking Breast Carcinoma in an Adult Male". *Journal of Evolution of Medical and Dental Sciences* 2014; Vol. 3, Issue 27, July 07; Page: 7605-7608, DOI: 10.14260/jemds/2014/2943

ABSTRACT: Pilomatricoma also known as calcifying epithelioma of Malherbe is a benign tumour arising from the hair matrix cells. This is predominantly seen in children and presents as small subepidermal nodules most commonly in head and neck regions. Trunk and lower extremities are rarely involved. We report a case of perforating pilomatricoma of breast in a 60years old male, clinically mimicking breast carcinoma

KEYWORDS: Pilomatricoma, perforating, breast.

KEYMESSAGES: Pilomatricoma is a benign tumour which can rarely cause perforation or ulceration of skin that can mimic malignancy and only wide local excision of the tumour is the required treatment with no further intervention.

INTRODUCTION: Pilomatricoma is a benign skin adnexal tumour of hair follicle differentiation. These tumours are commonly seen in children and adolescents involving mainly head and neck region, followed by upper and lower extremities and trunk.¹ Pilomatricomas can be either single or multiple. These present as small sized subepidermal nodules ranging from 0.5 to 3 cms, however tumours more than 5cms were also reported.^{1,2}

CASE REPORT: A 60years old male presented with a lump in the right breast of one year duration. The lump was small initially and gradually increased in size. Ulceration was noted 15 days prior to his presentation. No history of pain, nipple discharge or any other significant history. On examination there was a palpable mass in the right breast. The mass was firm to palpate and had restricted mobility. The skin overlying the mass was ulcerated. Nipple was normal. No palpable axillary lymph nodes of the same side or the contralateral side noted.

The left breast is normal. No imaging studies done. Right simple mastectomy done with a clinical diagnosis of fungating carcinoma breast.

Simple mastectomy specimen measured 8.5x4.5x4.0cms. The elliptical skin surface showed nipple, which is unremarkable; and a raised area slightly away from the nipple, measuring 1.2cms in diameter with a tiny central ulceration [Figure 1]. Serial cut sections showed a well defined grayish white growth measuring 5x3.5x3.0cms [Figure 2]. The growth was involving the overlying skin and was 0.5 cm away from the base.

Microscopy revealed a circumscribed lesion within the dermis extending down into the subcutaneous tissue. There are islands of proliferating basaloid cells with mild pleomorphism and occasional normal mitoses. No significant nuclear atypia or evidence of malignancy noted. These cells showed differentiation to mature squamous cells. Several nests of shadow cells, wet keratin and keratin pearls are present [Figure 3]. There is extensive foreign body type of giant cell reaction and

CASE REPORT

dystrophic calcification. The tumour is ulcerating the overlying skin. Nipple is unremarkable. The above features are consistent with the diagnosis of perforating pilomatricoma.

DISCUSSION: Pilomatricoma is a benign tumour of hair matrical differentiation also known as calcifying epithelioma of Malherbe.³ The name 'Pilomatricoma' was given by Forbes and Helwig.⁴ Majority of the tumours present in children and adolescents in the head and neck region as small, solitary, non-tender subcutaneous nodules ranging from 0.5 to 3cms in diameter.

Multiple lesions, even though extremely rare are also reported in literature.⁵ Upper and lower extremities and trunk are the less commonly involved sites.^{1,2} Rare familial cases have also been reported which can be associated with familial conditions like myotonic dystrophy and Gardner's syndrome.^{6,7}

These tumours are adherent to the overlying skin, however free from the underlying tissue. Ulceration or perforation is an uncommon finding. Surgical excision is the required treatment of choice.^{5,8}

Pilomatricoma of male breast were rare in literature.⁹ In the present case the patient's age and presentation with a breast lump and ulceration of the overlying skin had lead to the diagnosis of fungating breast carcinoma. However, on histopathology it turned out to be pilomatricoma which is a benign tumour and the patient would not need further management.

Histologically these tumours are often well defined and surrounded by a connective tissue capsule. They are seen in the dermis sometimes extending into the subcutaneous fat. The tumours are composed of islands of basaloid, keratinized epithelial cells called shadow or ghost cells whose cellular details are lost. The basaloid cells display dark staining nuclei, scant cytoplasm, and indistinct cell borders. Within the basaloid cell islands may be seen eosinophilic centers of keratinisation.

There can be extensive foreign body giant cell reaction to the keratinous material and dystrophic calcification. Ossification can also occur.^{2,10} Ulceration or perforation was rarely seen as reported by some authors.⁸ In the present case the lesion was large with a maximum dimension of 5 cm and was perforating through the overlying skin which lead to a clinical diagnosis of carcinoma.

Morphologically there are three variants of pilomatricoma; anetodermic, proliferating and perforating types, of which perforating pilomatricomas are extremely rare. Perforation is also termed as transepithelial elimination. The tumour tissue causes mechanical irritation resulting in epithelial hyperplasia of hair follicle and epidermis which enclose the tumour. This gradually comes close to the surface and eliminated with the keratinocytes.^{8,11}

The differential diagnosis includes benign lesions like sebaceous and trichilemmal cysts; and malignant tumour of the skin like basal cell carcinomas with matrical differentiation.^{1, 9, 12} Pilomatricomas unlike basal cell carcinomas, present as firm deep seated encapsulated nodules, usually covered by normal skin. Microscopically shadow cells are characteristic which are not seen in basal cell carcinomas with matrical differentiation.¹²

Pilomatrical carcinoma, the malignant counterpart of this tumour is an asymmetric, cellular and infiltrative neoplasm. Microscopically they are cellular with proliferating, hyperchromatic basaloid cells with nuclear atypia and numerous mitoses. These tumours may recur and show distant metastasis.¹⁰

Perforating pilomatricoma is a rare occurrence. An unusual site of presentation in the breast associated with perforation as in this case lead to a misdiagnosis of malignancy.

CASE REPORT

We present this case in view of rarity of presentation of pilomatricoma as a large mass in the breast with ulceration of the overlying skin leading to the clinical diagnosis of carcinoma breast. Pilomatricoma is a benign tumour and wide local excision of the tumour is the required treatment with no further intervention.

REFERENCES:

1. Zaman S, Majeed S, Rehman F Pilomatricoma – Study on 27 cases and review of literature. *Biomedica* 2009; 25: 69–72.
2. Lan MY, Lan MC, Ho CY, Li WY. Pilomatricoma of head and neck. A retrospective review of 179 cases. *Arch Otolaryngol Head Neck Surg.* 2003, 129:1327-1330
3. Malherbe A and Chenantais J. Note sur epitheliomacalcifiedes glandes sebacees. *Prog Med* 1880; 8: 826-837.
4. Forbis R, Helwig EB. Pilomatricoma (calcifying epithelioma) *Arch Dermatol* 1961; 83: 606-18.
5. Salati SA, al Aithan B. Multiple facial pilomatricomas. *J Pakistan association of dermatologists* 2011; 21: 215-218.
6. Chuang C, Lin C. Pilomatrixoma of the head and neck. *J Chin Med Assoc* 2004; 67: 663-63.
7. Duflo S, Nicollas R, Roman S, Magalon G, nad Triglia JM. Pilomatrixoma of the head and neck in children; a study of 38 cases and a review of the literature. *Arch Otolaryngol Head Neck Surg* 1998; 124: 1239-42.
8. Fetil E, Özkan S, Ilknur T, et.al. Multiple pilomatricoma with perforation. *Int J Dermatol* 2002; 41: 892-3.
9. Hubeny CM, Sykes JB, O’Connel A, Dogra VA. Pilomatricoma of the adult male breast: A rare tumour with typical ultrasound features. *J Clin Imaging Science* 2011; 1: 1-3.
10. Storm CA, Seykora JT. Cutaneous adnexal neoplasms. *Am J Clin Pathol* 2002; 118 (Suppl 1): S33-S49.
11. Uchiyana N, Shindo Y, Saida T. Perforating pilomatricoma. *J Cut Pathol.* 1986;13:312-318.
12. Aloï FG, Molinero A, Pippione M. Basal cell carcinoma with matrical differentiation. Matrical Carcinoma. *Am J Dermatopathol* 1988; 10:509-513.

Figure 1: Simple mastectomy specimen showing nipple (white arrow) and grey white raised area with a tiny ulcer in the centre, site of perforation (blue arrow).

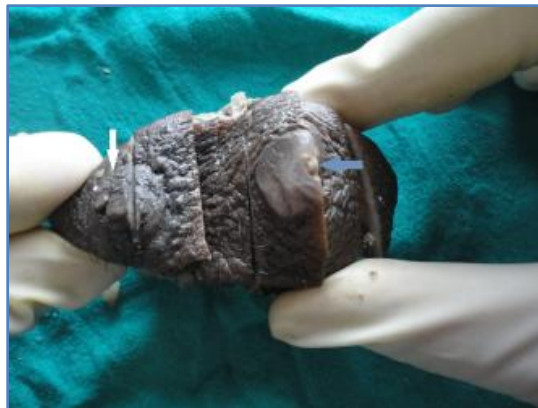

Figure 1

CASE REPORT

Figure 2: Cut section shows circumscribed grey white mass. Site of perforation (arrow).

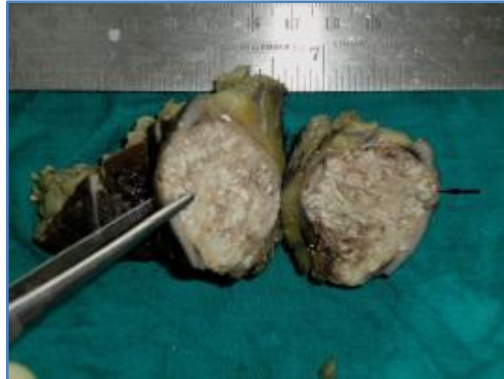


Figure 2

Figure 3: Pilomatricoma composed of proliferating basaloid cells (horizontal arrow) maturing to form ghost cells (vertical arrow). Ulceration of the overlying skin (arrow) [Hematoxylin eosin stain 20x].

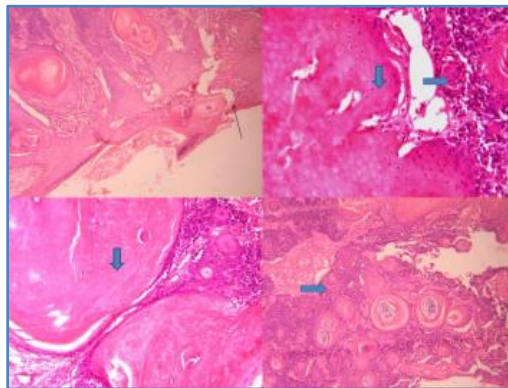


Figure 3

AUTHORS:

1. Mark Ruth Prasanna
2. Nalini Calton

PARTICULARS OF CONTRIBUTORS:

1. Assistant Professor, Department of Pathology, Christian Medical College, Ludhiana.
2. Professor, Department of Pathology, Christian Medical College, Ludhiana.

NAME ADDRESS EMAIL ID OF THE CORRESPONDING AUTHOR:

Dr. Mark Ruth Prasanna,
#48-17-13, Gandhipuram-1,
Rajahmundry-533103,
Andhra Pradesh.
Email: ruthpmark@yahoo.com

Date of Submission: 13/06/2014.
Date of Peer Review: 14/06/2014.
Date of Acceptance: 26/06/2014.
Date of Publishing: 07/07/2014.