

**EVALUATION OF DEGENERATIVE DISEASE OF LUMBOSACRAL SPINE BY 3 TESLA MRI**Pintu Biswas<sup>1</sup>, Asim De<sup>2</sup><sup>1</sup>Senior Resident, Department of Radiodiagnosis, Agartala Government Medical College, Agartala, Tripura.<sup>2</sup>Associate Professor, Department of Radiodiagnosis, Agartala Government Medical College, Agartala, Tripura.**ABSTRACT****BACKGROUND**

Low back pain (LBP) secondary to degenerative disease of spine is a condition related to musculoskeletal system and affecting mostly middle aged and older persons, but now-a-days younger people are also suffering. Plain radiograph can be helpful in visualising gross anatomic changes in the intervertebral disc. But MRI is the standard imaging modality for detecting disc pathology.

Aims and Objective- To evaluate imaging characteristics and extent of degenerative changes of the lumbosacral spine by 3 Tesla MRI and also to identify the associated changes and to find the pattern of pathological changes identified by MRI in low backache.

**MATERIALS AND METHODS**

Total 118 patients were studied to evaluate the MRI appearance of Degenerative disease of lumbosacral spine. The vertebrae, intervertebral discs, spinal canals and neural foramens were looked for the changes of degeneration. The spinal cord and the nerve roots were observed for signs of compression and degeneration.

**RESULTS**

Males were more frequently involved than females and they were mostly of 5<sup>th</sup> and 6<sup>th</sup> decades of their lives. Per patient disc involvement were 3.55%. Annular disc tear, disc herniation, narrowing of spinal canal, narrowing of lateral recess, compression of neural foramen, ligamentum flavum thickening and facet arthropathy were common at the L4 - L5 disc level.

**CONCLUSION**

Degeneration of lumbosacral spine is the most common cause of low back pain. Multiple levels of the disc involvement are seen per person. Males are more frequently affected to the disc degeneration than females. MRI is the standard imaging modality for detecting disc pathology due to its advantages like multiplanar imaging capability, excellent soft tissue contrast, precise localisation of intervertebral disc changes and lack of radiation.

**KEYWORDS**

Degenerative Disease of Spine, Intervertebral Disc, Magnetic Resonance Imaging, Low Back Pain, Spinal Canal Stenosis.

**HOW TO CITE THIS ARTICLE:** Biswas P, De A. Evaluation of degenerative disease of lumbosacral spine by 3 tesla MRI. J. Evolution Med. Dent. Sci. 2018;7(03):384-390, DOI: 10.14260/jemds/2018/85

**BACKGROUND**

The problem of low back pain (LBP) in the developed world nears epidemic proportions and has increased with a lifetime prevalence reported to be up to 84%.<sup>[1]</sup> LBP can result from many causes including congenital spinal stenosis, neoplasm, infection, trauma and inflammatory or arthritic processes, but lumbar disc degeneration is the commonest cause of LBP.<sup>[2]</sup>

Lumbar radiography may not identify all the abnormalities related to LBP symptoms and may be harmful because it exposes the gonads to ionising radiation.<sup>[3]</sup> Though CT is still used as the initial imaging modality in many institutions and correlation between CT and surgical findings were similar, routine CT imaging covers only a limited number of levels and may miss unexpected disease slightly higher or lower than the area of suspected pathology.

When CT is performed after injection of intrathecal contrast material, the sensitivity of the examination is increased but this is an invasive procedure and associated with risks of iodinated contrast, bleeding and infection.<sup>[4]</sup>

MRI has become the imaging modality of choice in the evaluation of spinal degenerative disease. MRI has several advantages including multiplanar imaging capabilities, superior soft tissue contrast and lack of ionising radiation. MRI is superior even to contrast-enhanced CT scans in distinguishing bone, disk, ligament, nerve, thecal sac and spinal cord. Pulse sequences can be adjusted to evaluate specific areas of interest or to more accurately define the disease process.<sup>[4]</sup>

This study is taken to evaluate the pattern of pathological changes identified by MRI in patients with low back pain.

**MATERIALS AND METHODS**

This cross-sectional study was conducted at the Department of Radiodiagnosis at Agartala Government Medical College and GB Pant Hospital, Agartala, Tripura over a period of 4 months from 1st September 2016 to 31st December 2016.

Total 118 patients were studied by 3 Tesla MRI machine using T1 and T2 sagittal, T2 coronal, T1 and T2 axial and T2 term sagittal sequences.

*'Financial or Other Competing Interest': None.*  
Submission 16-12-2017, Peer Review 03-01-2017,  
Acceptance 06-01-2018, Published 15-01-2018.

Corresponding Author:

Dr. Asim De,


Office Lane,

Opp. TOSDM Office,

Agartala-799001, Tripura.

E-mail: drasimde@rediffmail.com

DOI: 10.14260/jemds/2018/85



Patients between 18 to 87 years of the age with history of low back pain were included in the study after obtaining a verbal consent.

Patients with the history of trauma, prior surgery, spinal infections, active malignancy, pregnancy, cervical spine involvement and age less than 17 years were excluded from the study.

All the observation was done by two Radiologists (Associate Professor and Resident).

#### **Following MRI Findings were noted-**

Change in Lumbar lordosis, presence of Schmorl's nodes and reduction of disc height.

#### **Changes of Disc were observed as follows-**

##### **Disc Desiccation-**

Normally, central nucleus pulposus shows high signal intensity on T2WI and peripheral annulus, low signal intensity on T2WI (Figure 1). In desiccation, the disc lost its central high T2 signal.<sup>[3]</sup>

##### **Modic Changes-**

##### **Modic described Three Types End Plates Changes, namely Type 1, Type 2 and Type 3**

Type I changes (vascular pattern) correspond to active inflammation that showed decreased signal intensity on T1-weighted images and high signal intensity on T2-weighted images.

Type II changes (fatty pattern), the next stage, reflect fatty infiltration and showed high signal intensity on both T1-weighted and T2-weighted images.

Type III changes (sclerotic pattern) are seen in advance chronic stage and correspond to bone sclerosis. This was seen as low signal intensity on both T1-weighted and T2-weighted images.<sup>[5]</sup>

##### **Annular Tear**

It is also called annular fissure. Annular tear is further classified according to axial location into: Central or median, paramedian, foraminal and extraforaminal. But we could not divide our data to classify accordingly. We simply noted that whether annular tear were present or not. Tear in the disc was seen as hyperintense on T2-weighted images.<sup>[2]</sup>

##### **Disc Bulge**

An annular bulge represents an extension of the disk margin beyond the confines of the adjacent vertebral end plate. The annular fibres are stretched, but intact. The disk bulges diffusely around the posterior (and sometimes lateral) aspects of the end plate.<sup>[4]</sup> It is named according to the location like central, paracentral, foraminal or extraforaminal.<sup>[6]</sup>

##### **Disc Herniation**

Disk herniation is distinguished from annular bulge by its focality, whereas a disk usually bulges fairly uniformly along its margins. A disk herniates through one particular spot- the annular tear.<sup>[4]</sup>

A herniated disk can be subclassified as- (1) Protrusion (2) Extrusion and (3) Sequestration.

##### **Protrusion**

A disc protrusion is a herniated disc in which the greatest distance in any plane between the edges of the disc material beyond the disc space is less than the distance between the edges of the base in the same plane.<sup>[7]</sup> This is the simplest (and probably earliest) type of disk herniation.<sup>[4]</sup>

##### **Extrusion**

This is a herniated disc in which, in at least one plane, any one distance between the edges of the disc material beyond the disc space is greater than the distance between the edges of the base in the same plane.<sup>[7]</sup> The herniated segment remains attached to the parent disk, but may extend to cephalad or caudad.<sup>[4]</sup>

##### **Sequestration**

When an extruded nucleus breaks free of the parent disc, it is termed as sequestered disk or free fragment. The sequestered portion may or may not be confined by the posterior longitudinal ligament. In fact it may migrate inferiorly or superiorly to a different interspace or in rare cases may even penetrate the dura.<sup>[4]</sup>

##### **Ligamentum Flavum Thickening**

Ligamentum flavum thickening was measured on the axial image, perpendicular to the spinal canal axis and parallel to the lamina, where ligamentum flavum were seen along their entire length and measurement were taken at the half length of ligament flavum.<sup>[3]</sup> We had labelled a value of > 4 mm as thickened ligamentum flavum.

##### **Facetal Arthropathy-**

Facetal arthropathy was noted as reduction in synovial facet joint space with loss of high signal intensity on T2WI.<sup>[3]</sup>

##### **Narrowing of Spinal Canal**

In the mid-sagittal T2 weighted images, spinal canal diameter was measured. Spinal canal diameter less than 11.5 mm indicates narrowing of the canal.<sup>[7]</sup>

##### **Narrowing of Lateral Recess**

It was measured at the level of the pedicle in axial section as the distance between the post aspect of the vertebral body and superior articular facet. If it was less than 4 mm, it was considered abnormal.<sup>[7]</sup>

##### **Compression of Neural Foramina**

Compression of neural foramen was observed in T2W sagittal image. On sagittal images, the normal neural foramen has the appearance of a vertical oval. If disk material extends into the foramen, the oval narrows inferiorly, creating a keyhole shape.<sup>[6]</sup>

##### **Others**

Lumbarisation and sacralisation of the vertebra were observed.

#### **Following Incidental findings were also noted-**

Vertebral haemangioma- These are well-defined, round-shaped abnormal high signal intensity lesion in both T1WI and T2W1 without fat suppression.<sup>[2]</sup>

**Tarlov Cyst**

These are CSF-filled sacs located in the spinal canal of S1 - S4 region of vertebrae.<sup>[8]</sup>

**RESULTS**

Total 118 patients were studied in the evaluation of MRI appearance of degenerative disease of lumbosacral spine. Sixteen patients were excluded from the study as they had history of trauma, prior surgery, spinal infections, mass or evidences of vertebral metastasis.

Degenerative changes were present in total 419 no. of discs, so per patient disc involvement were 3.55%.

From total 118 patients, 84 patients (i.e. 71.2% of total patients) were male and 34 patients (i.e. 28.8% of total patients) were female [Refer Table No. 1]. They were mostly of 5<sup>th</sup> and 6<sup>th</sup> decades of their life, together constituting approximately 51.69% of total cases (61 patients) [Refer Table No. 2].

Lumbar lordosis was preserved in 80 (i.e. 67.79% of total patients) (Figure 2) and loss of the lumbar lordosis (Figure 4) was seen in 38 (i.e. 32.20% of total patients). Degenerative scoliosis which is defined as scoliosis that occurs during adulthood as a result of degenerative changes of the spine was noted in eight cases (6.77%). Nine patients (i.e. 7.62% of total patients) showed listhesis in the spine in the form of anterolisthesis (Figure 3) or retrolisthesis (Figure 4). Anterolisthesis is common as compared to retrolisthesis. L4 vertebral body listhesis over L5 vertebral body was common in anterolisthesis. In retrolisthesis, L5 over S1 and L2 over L3 were equally seen [Refer Table No. 3].

Conus end at L1 and disc between L1-L2 vertebral level which was most common and seen in 72 patients (i.e. 61.01% of total patients).

Reduction of body height was seen in 18 vertebrae (1.52% of total vertebrae). Decreased disc heights were seen in 22 discs, most commonly involving L4-L5 disc level (7 discs, i.e. 31.81% of decreased disc height) followed by L5-S1 disc levels (6 discs, i.e. 27.27% of decreased disc height) (Figure 3). Osteophytosis was demonstrable in eighty-eight (88) vertebral bodies (7.45% of total vertebrae) in our study. Maximum osteophytes were seen at L3, L4 and L5 vertebrae. Anterior marginal osteophytes were in 83 and posterior osteophytes in 5 vertebrae. The anterior margin of L4 vertebral body was the commonest site of osteophytosis. Modic type-1 end plate changes were seen in 5 discs. Total 163 discs showed Modic type-2 changes, commonly observed in L4-L5 and L5-S1 disc level. Desiccations were noted in 191 discs (45.58% of involved discs), commonly at L4-L5 level (Figure-3, 8). Schmorl's nodes were present in 76 discs (18.13% of involved discs), which was also commonly noted at L4-L5 level (Figure-3, 8) [Refer Table 4].

Total 46 discs (i.e. 10.97% of involved disc) showed annular disc tear, mostly involving L4-L5 level (Figure-4). Herniation of disc was seen in forty discs (9.54% of involved discs). Among them 37 cases were protrusion (92.5% of disc

herniation), which mostly involved L4-L5 and L5-S1 level (19 and 12 no's respectively) (Figure-5, 6). Extrusion was in three discs (7.5% of disc herniation) and was common at L4-L5 disc level.

Disc bulge was seen involving 300 discs (71.59% of involved discs) and was common at L3-L4, L4-L5 and L5-S1 level. Among these, diffuse posterocentral disc bulge were seen in 44 discs (14.66% of total disc bulge), diffuse posterocentral with bilateral paracentral disc bulge were seen in 193 discs (64.33% of total disc bulge), right paracentral disc bulge were seen in 7 discs (2.33% of total disc bulge), diffuse posterocentral with right paracentral disc bulge were seen in 9 discs (3% of total disc bulge), left paracentral disc bulge were seen in 3 discs (1% of total disc bulge), diffuse posterocentral with left paracentral disc bulge were seen in 9 discs (3% of total disc bulge) and bilateral paracentral disc bulge were seen in 35 discs (11.66% of total disc bulge).

Spinal canal stenosis was seen in 174 discs (41.52% of involved discs) level, commonly involving L3-L4, L4-5 and L5-S1 levels (Figure-5, 6).

Narrowing of lateral recess was seen in 233 disc levels (55.60% of involved discs) involving L3-L4, L4-L5 and L5-S1 region. Compression of neural foramen was seen in 142 disc levels (33.89% of involved discs), most commonly noted at L4-L5 followed by L5-S1 region.

Facetal arthropathy and ligamentum flavum thickening was seen in 9 (2.14% of total involved disc) and 4 discs (0.95% of total involved disc) level respectively (Figure-7) and both were common at the L4-L5 and L5-S1 disc level [Refer Table-5].

As incidental findings vertebral haemangioma were seen in 36 vertebral bodies (i.e. 3.38% of total vertebral bodies) and Tarlov cyst in 1 case (i.e. 0.84% of total patients) (Figure-8).

Age Group (Years )	No. of Cases	Percent
18-20	1	.8
21-30	8	6.8
31-40	23	19.5
41-50	34	28.8
51-60	27	22.9
61-70	19	16.1
71-80	5	4.2
81-90	1	.8
<b>Total</b>	<b>118</b>	<b>100.0</b>

*Table 1. The Table is showing the Age distribution of the Cases*

Sex	No. of Cases	Percent
Male	84	71.2
Female	34	28.8
<b>Total</b>	<b>118</b>	<b>100.0</b>

*Table 2. The Table is showing the Sex distribution of the Cases*

Parameter	Comment	Total Number	Percent
Loss of lumbar lordosis		38	32.20
Scoliosis present	Convexity toward right	2	6.77
	Convexity toward left	6	
Kyphosis		2	1.7
Lumbarisation present		1	0.8

Sacralisation present	Partial	3	9	7.62
	Complete	6		
Spondylolisthesis	L4 over L5	3	5	4.23
	L5 over S1	1		
	S1 over S2	1		
Retrolisthesis	L2 over L3	2	4	3.38
	L5 over S1	2		

**Table 3. Frequencies of Degenerative Changes like Loss of Lordosis, Scoliosis, Kyphosis, Lumbarisation, Sacralisation and Listhesis**

LEVEL	Osteophytes			Reduced Body Height	Fatty Marrow Infiltration	Haemangioma	Tarlov cyst	Reduction of IVDS	Modic Change			Schmorl's Node			Disc Desiccation	
	Anterior (A)	Posterior (P)	A+P						Type-1	Type-2	Type-3	Upper end plate	Lower end plate	Both end plate	Complete	Partial
D10-D11	-	-	-	-	-	2	-	-	-	-	-	1	-	-	-	-
D11-D12	-	-	-	-	-	7	-	-	-	-	-	4	-	-	-	-
D12-L1	-	-	-	3	1	4	-	-	-	1	-	5	1	1	-	-
L1-L2	5	-	-	5	5	4	-	2	-	9	-	10	2	1	11	4
L2-L3	11	1	1	2	3	6	-	3	1	15	-	8	-	5	4	23
L3-L4	21	1	1	2	3	4	-	3	1	34	-	7	4	4	10	35
L4-L5	23	1	1	4	4	2	-	7	2	50	-	9	1	5	19	41
L5-S1	21	1	1	2	7	5	-	6	1	45	-	5	-	2	11	31
S1-S2	2	1	-	-	6	2	1	1	-	9	-	-	1	-	-	2
Sub Total	83	5	4	18				22	5	163	-	49	9	18	55	136
<b>TOTAL</b>	<b>88</b>			<b>18</b>	<b>29</b>	<b>36</b>	<b>1</b>	<b>22</b>	<b>168</b>			<b>76</b>			<b>191</b>	

**Table 4. Different variables like Osteophytes, reduction of Vertebral Body Height, Fatty Marrow Infiltration, Haemangioma, Reduction of Intervertebral Disc Space (IVDS), Modic changes, Schmorl's Nodes, Disc Desiccation and their correlation with the Intervertebral Disc/ Vertebral Body Level**

Level	Disc Bulge							Herniation			LR Narrowing			NF Compression			Thecal Indentation	Spinal Canal Stenosis	Ligamentum Flavum Thickening	Facetal Arthropathy		
	D BIL	D	R	D+R	L	D+L	PARA BIL	Prot	Extr	Seq	RT	LT	BIL	RT	LT	BIL				RT	LT	BIL
D10-D11	-	1	-	-	-	-		-	-	-	-	-	-	-	-	-	1	-	-	-	-	-
D11-D12		1															1					
D12-L1		1															1					
L1-L2	5	4				1	3					5			3	7	7	-	-	-	-	-
L2-L3	15	7	-	-	-	-	10	1	-	-		21			9	18	18	-	-	-	-	-
L3-L4	53	13	1	1	1	3	9	5	-	-	3	3	56	-	1	34	66	47	-	-	-	2
L4-L5	76	5	3	2	1	3	8	19	2	-	2	4	84	-	1	50	90	65	2	-	-	4
L5-S1	44	12	3	6	1	2	5	12	1	-	7	4	44	-	-	44	55	37	2	-	-	3
S1-S2	-	-	-	-	-	-	-	-	-	-	-	-	-	-	-	-	-	-	-	-	-	-
Sub-total	193	44	7	9	3	9	35	37	3	-	12	11	210		2	140		174	4			9
<b>Total</b>	<b>300</b>							<b>40</b>			<b>233</b>			<b>142</b>			<b>239</b>	<b>174</b>	<b>4</b>	<b>9</b>		

**Table 5. Different variables like Disc Bulge, Herniation, Narrowing of Lateral Recess, Compression of Neural Foramen, Thecal Sac Indentation, Spinal Canal Narrowing, Ligamentum Flavum Thickening, Facetal Arthropathy and their correlation with the Intervertebral Disc Level**

[D- Diffuse posterocentral; D BIL- Diffuse posterocentral and bilateral paracentral; R- Right paracentral; D + R- Diffuse posterocentral and right paracentral. L- Left paracentral; D + L- Diffuse posterocentral and left paracentral; PARA BIL- Bilateral paracentral; Prot- Protrusion; Extr- Extrusion; Seq- Sequestration; LR- Lateral recess; NF- Neural foramen; BIL- Bilateral]

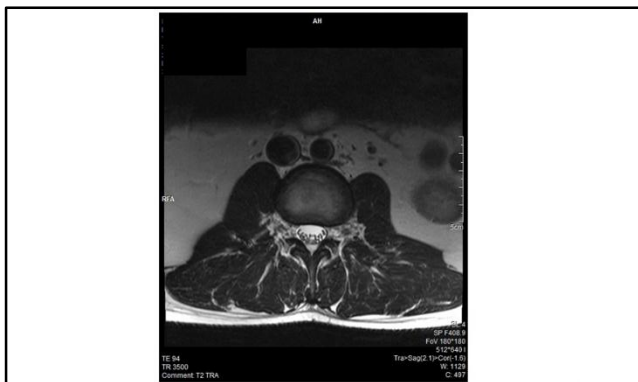

Figure-1. Axial T2WI shows normal disc. High signal intensity in nucleus pulposus [double headed arrow] and low signal intensity in annulus fibrosus [arrow].

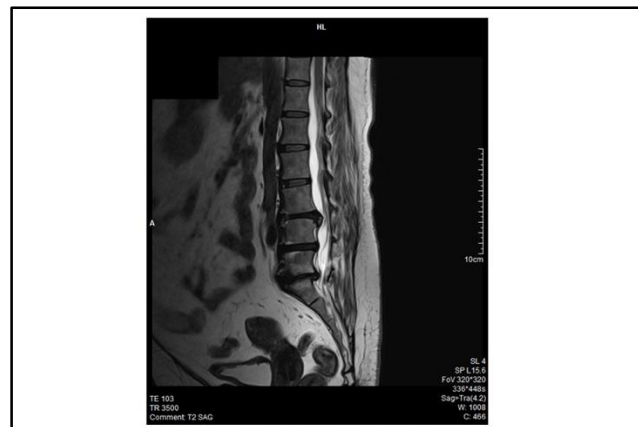

Figure- 4. Sagittal T2WI shows loss of lumbar lordosis with retrolisthesis of L5 over S1 vertebra [double arrow]. Annular tear with evidence of diffuse posterocentral disc bulging is seen at L3-L4 level [arrow]. Diffuse posterocentral disc bulge is also seen at L4-L5 & L5-S1 level.

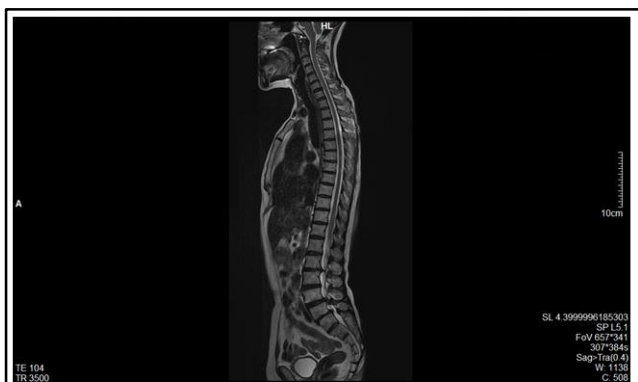

Figure-2. Sagittal T2WI of whole spine shows normal lumbar lordosis.

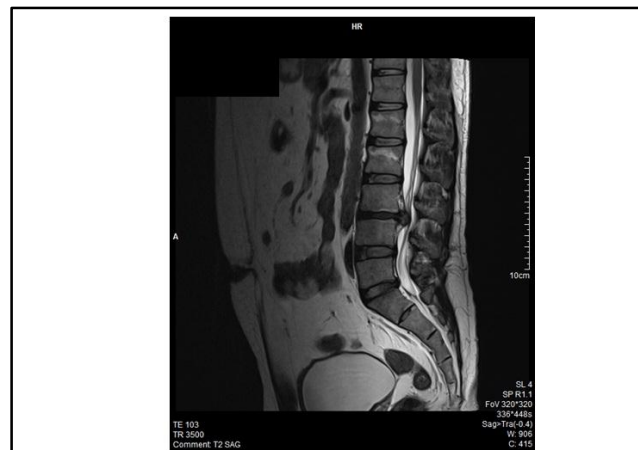

Figure-5. Sagittal T2WI shows loss of lordosis. Protrusion of disc material at L3-L4 level causing spinal canal stenosis [white arrow]. Desiccation is seen is also seen in L3-L4 disc. Disc bulge is noted at L5-S1 level.

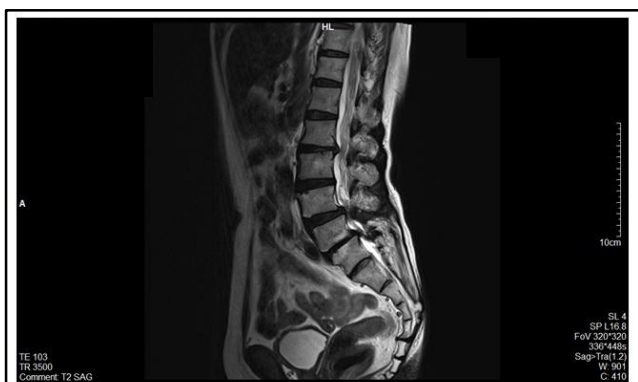

Figure-3. T2WI Sagittal image shows disc bulge at L2-L3, L4-5 & L5-S1 level associated with narrowing of IVDS at L2-3 & L5-S1 level (elbow connector). Disc desiccation is seen at multiple levels (arrows). Schmorl's nodes are seen in upper end plate of L3, 4 & S1 (double arrows). Minimal anterior subluxation of L5 over S1 (spondylolisthesis- grade 1) is noted [white arrow].

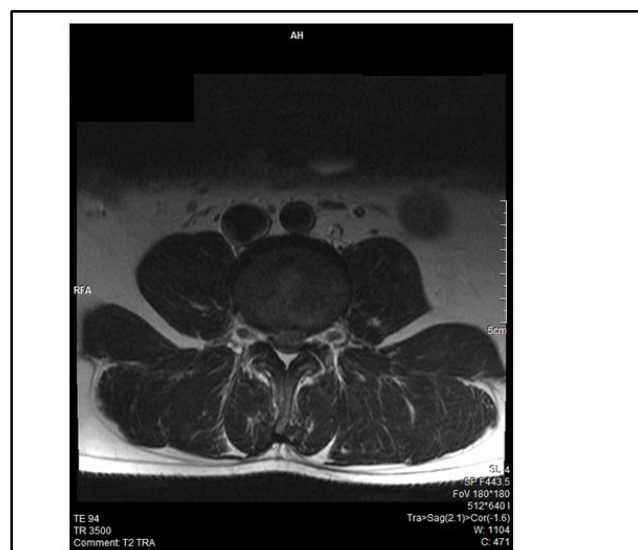

Figure-6. Axial T2WI showing protruded disc causing spinal canal stenosis

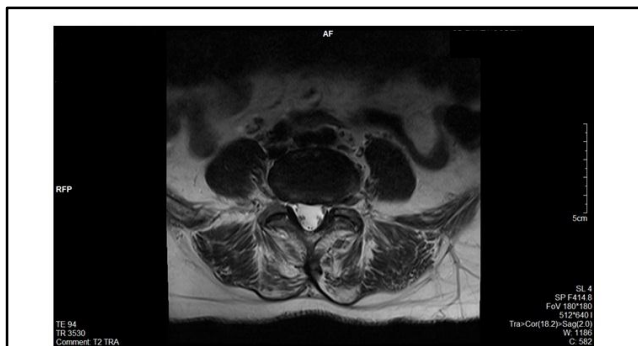

Figure-7. Axial T2WI shows bilateral facet arthropathy [arrow] and bilateral ligamentum flavum thickening [double arrow] at the level of L4-L5. At the same level diffuse posterocentral and bilateral paracentral disc bulge is also seen.

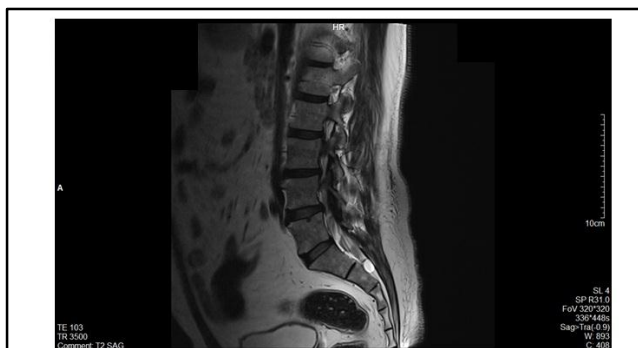

Figure-8. Sagittal T2WI shows tarlov cyst at the level of S2 vertebral body [white arrow]. Schmorl's node is noted at upper end plate of L5 (double arrow). Disc desiccation is seen at L1-2, L2-3 & L3-4 level (arrows).

## DISCUSSION

In our study, we observed that males (71.2%) are more commonly affected than females (28.8%). Similar sex distribution was observed by Suthar et al.<sup>[2]</sup> In that study, there were 55.04% male and 44.94% female. Degeneration of disc was most commonly observed in 5th and 6th decades of life in our study, which was comparable with the previous study.<sup>[9]</sup>

Osteophytosis was demonstrable in 7.45% of total vertebrae in our study. In their study by Rai et al, the anterior margin of L4 vertebral body was the commonest site of osteophytosis, same as noted in our study. Rai et al also observed that in general posterior osteophytes were the least common, which is consistent to this study.<sup>[10]</sup>

Decrease disc heights were seen most commonly involving L4-L5 disc level (31.81% of decreased disc height), which is close to the study by Suthar et al who also noted that decreased disc heights most commonly involved L4-L5 level (in 32.26%).<sup>[2]</sup> Disc desiccation is a common degenerative change of intervertebral discs observed in various previous studies similar to our study.<sup>[2,3]</sup>

In our study, we observed Modic type 1 change in 6 and type 2 changes in 163 discs. Several series have shown that type 2 changes are the most frequent and may account for up to 90% of Modic changes.<sup>[11]</sup>

Spondylolisthesis was seen in 7.62% cases, which is close to the study by Abhikesh et al who observed it in 10.6% cases.<sup>[3]</sup> Anterior subluxation of L4 vertebral body over L5 vertebral body was common in our study. Similar findings were noted by Modic and Ross.<sup>[5]</sup> In retrolisthesis, L5 over S1 and L2 over L3 were equally seen. Many authors noted that retrolisthesis of L5 over S1 is common.<sup>[2,3]</sup>

In this study herniation of disc was seen in forty discs (9.54% of involved discs), which is in concordance with previous study by Suthar et al where herniation was seen involving 150 discs (62.24% of involved discs).<sup>[2]</sup> Protrusion was more common than extrusion, which is similar to other studies.<sup>[10]</sup> Most commonly involved level in disc herniation was L4-L5 level, which is consistent to previous study.<sup>[3]</sup>

Frequency of facet arthropathy and ligamentum flavum thickening were significantly less. Ligamentum flavum hypertrophy was seen at lower spinal level involving the L4/L5 and L5/S1 level, which was similar to the study conducted by Saleem et al.<sup>[12]</sup>

In the present study reduced disc space, disc bulge and herniation was observed in most of spinal canal stenosis cases, but all of them did not have ligamentum flavum hypertrophy. These observations are consistent to the study by Genevay et al.<sup>[13]</sup>

Disc degeneration with diffuse disc changes were more commonly found at L4-L5 and L5-S1 level and L1-L2 is the least common. Similar observations were made in previous studies.<sup>[2, 9]</sup>

In this study, most patients had degenerative changes at multiple levels and very few patients had degenerative changes at single level. This also correlates with the past studies.<sup>[14,15]</sup>

## CONCLUSION

Degeneration of lumbosacral spine is the commonest MRI pattern in patients with low back pain. Males are more frequently affected to the disc degeneration than females. Wide spectrum of degenerative changes has been observed in this study involving all age groups. Degeneration of intervertebral disc is the commonest degenerative finding observed.

Annular tear, disc bulge, herniation, spinal canal stenosis, narrowing of lateral recess, compression of neural foramen, facet arthropathy and ligamentum flavum thickening were more common at lower lumbar levels, e.g. L4-L5 and L5-S1 level, probably due to highest mechanical stress.

MRI is the standard imaging modality for detecting disc pathology due to its advantages of multiplanar imaging capability, excellent spinal soft tissue contrast, precise localisation of intervertebral disc changes and lack of radiation.

## REFERENCES

- [1] Walker BF. The prevalence of low back pain: a systematic review of the literature from 1966 to 1998. *J Spinal Disord* 2000;13(3):205-17.
- [2] Suthar P, Patel R, Mehta C, et al. MRI evaluation of lumbar disc degenerative disease. *J Clin and Diagn Res* 2015;9(4):TC04-9.
- [3] Kapadia B, Abhikesh S, Patil N, et al. Magnetic resonance evaluation of degenerative lower spine in chronic low back pain patients. *Int Journal of Pharmaceutical Sciences and Medicine* 2017;2(3):1-8.
- [4] Jacobs DS. Degenerative disease of the spine. In: Haaga JR, Dogra VS, Forsting M, et al. eds. *CT and MRI of the whole body*. 5<sup>th</sup> edn. Philadelphia: PA: St. Louis: Mosby 2008:755-70.
- [5] Modic MT, Ross JS. Lumbar degenerative disc disease. *Radiology* 2007;245(1):43-61.

- [6] Helms C, Major N, Anderson M, et al. *Musculoskeletal MRI*. 2<sup>nd</sup> edn. Philadelphia, PA: Elsevier Saunders 2009.
- [7] Atlas SW. *Magnetic resonance imaging of brain and spine*. 4<sup>th</sup> edn. Philadelphia: Williams & Wilkins 2009:1449-506.
- [8] Park HJ, Jeon YH, Rho MH, et al. Incidental findings of the lumbar spine at MRI during herniated intervertebral disk disease evaluation. *AJR Am J Roentgenol* 2011;196(5):1151-5.
- [9] Cheung KM, Karppinen J, Chan D, et al. Prevalence and pattern of lumbar magnetic resonance imaging changes in a population study of one thousand forty-three individuals. *Spine (Phila Pa 1976)* 2009;34(9):934-40.
- [10] Rai GS, Mehra A, Gaur TNS. A prospective study of magnetic resonance imaging findings in patients of chronic low back pain: a clinico-radiological correlation. *Int J Res Med Sci* 2016;4(1):47-56.
- [11] Rahme R, Moussa R. The modic vertebral endplate and marrow changes: pathologic significance and relation to low back pain and segmental instability of the lumbar spine. *AJNR Am J Neuroradiol* 2008;29(5):838-42.
- [12] Saleem S, Aslam HM, Rehmani MA, et al. Lumbar disc degenerative disease: disc degeneration symptoms and magnetic resonance image findings. *Asian Spine J* 2013;7(4):322-34.
- [13] Genevay S, Atlas SJ. Lumbar spinal stenosis. *Best Pract Res Clin Rheumatol* 2010;24(2):253-65.
- [14] Boden SD, Davis DO, Dina TS, et al. Abnormal magnetic-resonance scans of the lumbar spine in asymptomatic subjects. A prospective investigation. *J Bone Joint Surg Am* 1990;72(3):403-8.
- [15] Takatalo J, Karppinen J, Niinimäki J, et al. Prevalence of degenerative imaging findings in lumbar magnetic resonance imaging among young adults. *Spine (Phila Pa 1976)* 2009;34(16):1716-21.