

# Stratification of Tetralogy of Fallot and Status of Pulmonary Artery by Cardiac CT (Pulmonary Angiography)

Ajad Kumar Sarawagi<sup>1</sup>, Varsha Sodani<sup>2</sup>, Rajendra Kumar Sodani<sup>3</sup>, Mahesh Verma<sup>4</sup>

<sup>1</sup>Professor, Department of Radiodiagnosis, RD Gardi Medical College, Ujjain, Madhya Pradesh, India. <sup>2</sup>Senior Resident, Department of Radiodiagnosis, RD Gardi Medical College, Ujjain, Madhya Pradesh, India. <sup>3</sup>Consultant Radiologist (Director), Department of Radiodiagnosis, Sampurna Sodani Diagnostics, Indore, Madhya Pradesh, India. <sup>4</sup>Consultant Radiologist, Department of Radiodiagnosis, Apollo Hospitals, Indore, Madhya Pradesh, India.

## ABSTRACT

### BACKGROUND

One of the important causes of morbidity and mortality in paediatric population is Congenital Heart Disease (CHD). Genetic, environmental and cultural factors may lead to variability in prevalence and incidence.<sup>(1)</sup> There are many modalities for the diagnosis of CHD, in our armamentarium. Echocardiogram is the first in cases suspicious of CHD. However quite often, it is difficult to access and evaluate great arteries, pulmonary veins, coronary arteries and intracardiac anomalies in detail. In seriously ill or uncooperative patients, magnetic resonance imaging (MRI) is often of limited use. MRI examination also takes longer duration, causes claustrophobia and electronic devices such as pacemakers are a contraindication.<sup>(2)</sup>

### METHODS

In this retrospective observational study 21 cases of clinically diagnosed Tetralogy of Fallot's (TOF ) referred to Sodani Diagnostic Centre, Indore and matching our inclusion and exclusion criteria, were included in this study. Out of 21 subjects, 9 were female and 12 were male. Youngest was 9 months old and eldest was 30 years old. Most of the study subjects were sent investigation of the morphology of heart and great vessels using cardiac CT, as echocardiography was not enough. All studies were performed on 128 Slice GE Optima after taking consent.

### RESULTS

In our study, a 128 slice multidetector CT scanner GE Optima was used, to scan 21 patients with TOF. Defect in ventricular septum (VSD) was noted in all cases (n =21). Overriding of aorta was noted in nineteen patients (90%). Right ventricle was mildly hypertrophied (RVH) in 10 patients (47%). 8 patients (33%) were showing major aorto-pulmonary collateral circulation (collateral diameters ranged from 1 to 3.5 mm) and narrowing of pulmonic infundibulum was seen in 7 patients (28%), aortic arch was right sided in 5 cases (23%). Complex pulmonary artery morphology was seen in most of the patients. Pulmonary trunk and bilateral pulmonary arteries were significantly narrowed in 3 cases (14%). Stenosis of main trunk and left pulmonary artery were noted in 2 cases (9%). Right pulmonary artery and main trunk narrowing was seen in 4% (n=1).

### CONCLUSIONS

Important additional information is obtained by using technically advanced Multidetector CT. Newer advances have significantly increased the speed of CT machines, so we can complete the procedure of pulmonary CTA with ease of peripheral venous access and markedly reduced sedation time. No correlation was found between size of pulmonary trunk and collaterals, which suggests that every patient has different chance of detecting collaterals. However as age increases, chances of getting collaterals also increases.

### KEYWORDS

Tetralogy of Fallot, Pulmonary Artery, Cardiac CT

Corresponding Author:

Dr. Varsha Sodani,  
LG-1, Morya Centre,  
16/1, Racecourse Road,  
Indore-1, Madhya Pradesh, India.  
E-mail: drvarshasodani@gmail.com

DOI: 10.14260/jemds/2019/605

Financial or Other Competing Interests:  
None.

How to Cite This Article:

Sarawagi AK, Sodani V, Sodani RK, et al.  
Stratification of tetralogy of fallot and  
status of pulmonary artery by cardiac ct  
(pulmonary angiography). *J. Evolution  
Med. Dent. Sci.* 2019;8(36):2787-2792, DOI:  
10.14260/jemds/2019/605

Submission 31-03-2019,  
Peer Review 22-08-2019,  
Acceptance 30-08-2019,  
Published 09-09-2019.



## BACKGROUND

One of the important causes of morbidity and mortality in paediatric population is Congenital Heart Disease (CHD). Genetic, environmental and cultural factors may lead to variability in prevalence and incidence.<sup>(1)</sup> Among many modalities for diagnosis, in our armamentarium, Echocardiogram is the first in cases suspicious of CHD, however infrequently, it is difficult to access and evaluate great arteries, pulmonary veins, coronary arteries and intracardiac anomalies in detail. In seriously ill or uncooperative patients, Magnetic resonance imaging (MRI) is often of limited use as it takes longer duration and claustrophobia and electronic devices such as pacemakers are a contraindication.<sup>(2)</sup> Frequently noted morphological heterogeneity, large number of potential surgical palliations, and quite often associated congenital extra and intracardiac anomalies seen in various subtypes of TOF patients, must be searched, when imaging a case with TOF.<sup>(3)</sup>

This study was undertaken to see up to what extent Cardiac CT can help in assessment of non-conclusive echocardiography in cases of TOF regarding long term morbidity especially pulmonary hypertension and collateral development.

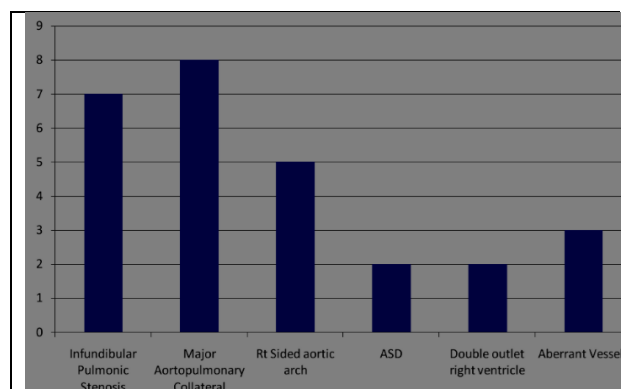
## METHODS

In this case series of retrospective observational study, 21 cases who were clinically diagnosed as Tetralogy of Fallot's (TOF), and had been referred to Sodani Diagnostic Centre, Indore, matching with our aims and objects, were included. Out of 21 subjects, youngest was 9 months old and eldest was 30 year. Among them 12 were male and 9 were female. Most of the study subjects were sent to answer specific queries regarding detailed morphology of heart and great vessels using cardiac CT, due to inability of echocardiography to do so. All studies were performed on 128 slice GE optima after taking consent of patient or relatives in cases of minor. Automated bolus technique with power injector, putting the bolus tracking device on specific morphological parts to solve specific questions of clinical and surgical interest was used to inject non-ionic contrast agent at 1 ml/sec of injection rate and posologically dose was calculated as 1 ml/kg to perform CT angiographic study. In paediatric age group, time factor is an important criteria and it was possible that the sedation time was kept between 2-10 minutes and was adequate for complete CT scanning procedure; it was significantly shorter than 30-45 minutes required for patients of similar age undergoing cardiac MRI.

## RESULTS

In our study, a 128 slice Multidetector CT scanner GE optima was used, to scan 21 patients with TOF. Defect in ventricular septum (VSD) was noted in all cases (n =21). Overriding of aorta was noted in nineteen patients (90%). Right ventricle was mildly hypertrophied (RVH) in 10 patients (47%). 8 patients (33%) were showing major aorto-pulmonary

collateral circulation (collateral diameters ranged from 1 to 3.5 mm) and narrowing of pulmonic infundibulum was seen in 7 patients (28%). Aortic arch was right sided in 5 cases (23%). Complex pulmonary artery morphology was seen in most of the patients. Pulmonary trunk and bilateral pulmonary arteries were significantly narrowed in 3 cases (14%). Stenosis of main trunk and left pulmonary artery were noted in 2 cases (9%). Right pulmonary artery and main trunk narrowing was seen in 4% (n=1). Right pulmonary artery branch narrowing was noted at origin, measuring @ 2.4 mm with normal caliber of main pulmonary artery in 4% (n = 1), main trunk and right pulmonary artery narrowing was observed in 4%(n=1). Additionally, 3 cases (14%) showed aberrant vessels like left vertebral artery originating directly from aortic arch. Right ventricle was showing double outlet in two patients (9%). Associated ASD was noted in 2 cases (9%).



**Table 1. Distribution of Congenital Cardiac Anomalies Associated with TOF (N-21)**

## DISCUSSION

Incidence is more common in premature infants or cases with history of still births and previous sibling affected with some heart disease. Congenital cardiac malformations are result of defective embryonic development. All the fetal heart structures are formed between 3-8 weeks of gestation.<sup>(4)</sup>

### Factors Contributing to CHD

In 85-90% cases of congenital heart diseases, mostly multifactorial inheritance pattern is noted rather than identifying a single cause. Combination of genetic and environmental factors are commonly associated in this condition. In 5-8% cases, maternal factors that can be usually correlated with CHD are intake of drugs like anti convulsants or anti-depressants, family history of CHD in either sibling or parent, Infections, alcohol intake, advanced maternal age, and chromosomal abnormalities.<sup>(4)</sup>

### Tetralogy of Fallot

TOF, constitutes 4-9% of CHD's, and is the commonest cyanotic congenital heart condition. It is defined by combination of ventricular septal defect (VSD), right ventricular outflow tract obstruction (RVOTO), overriding of aorta, and right ventricular hypertrophy. RVOTO and VSD, both are responsible for elevated resistance to right heart emptying and consequently causing Right ventricular hypertrophy.<sup>(5)</sup> The presentation depends mainly upon degree of RVOTO and pulmonary atresia. Pulmonary atresia constitutes about 18% of children with TOF.

Major RVOTO is infundibular stenosis. As stenosis increases, infants and children may develop hypoxic spells (tets spells). Cyanosis may not be apparent (pink tetralogy) in cases where obstruction is minimal, and although rare may be resulting in delayed presentation of cyanosis in adulthood. Unequal growth of the aorto-pulmonary septum is responsible for this anomaly. Due to this defective septal growth the aortic passage becomes relatively large, thus "over-riding" occurs and this "steals" blood from the pulmonary artery. RVOTO and/or pulmonary stenosis add in this phenomenon. This then prevents ventricular wall closure, resulting in VSD, and this increases the pressures on the right heart and so to deal with the increased workload right ventricle becomes hypertrophied.<sup>(5)</sup>

**Echocardiography**

Cardiac abnormal morphology is visualized directly by echocardiography, which remains the primary modality for diagnosis of TOF. However major limitations of echocardiogram are in assessing associated extracardiac anomalies (e.g. peripheral pulmonary stenosis and atresia) which are a must prior to taking a surgical decision.

**CTA**

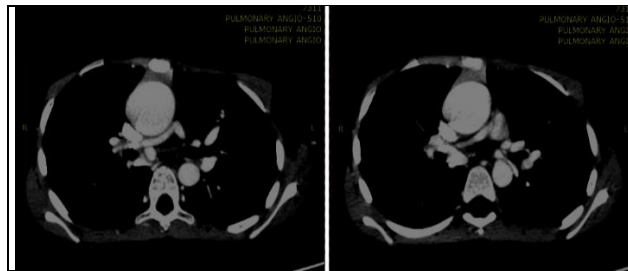
Complex cardiovascular morphology of TOF, anatomy of pulmonary vessels and status of coronary arteries and aortopulmonary collateral vessels (MAPCA's) are all well detected and evaluated by MDCT.<sup>(6)</sup> If pulmonary artery hypoplasia/stenosis are not addressed properly, repair of the cardiac defects will give poor outcome, so preoperative evaluation of pulmonary artery in detail is of paramount importance.<sup>(6)</sup> Comparison of diameter of pulmonary main or right artery must be done with ascending aortic diameter. Primary repair would be unsuccessful with the ratio of <0.3 and such patients may be benefited by bridging shunt operation. In addition surgical planning should include evaluation of coronary morphology.<sup>(7)</sup>

**Major Aorto-Pulmonary Collaterals**

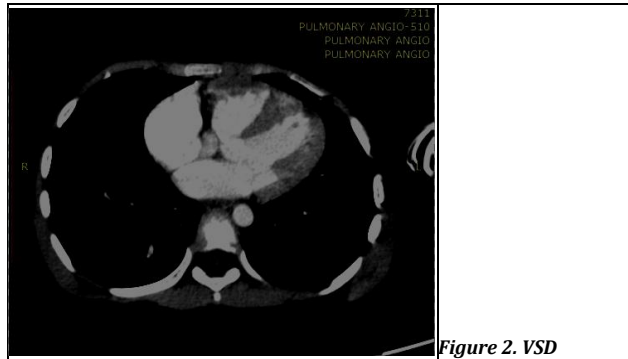
During Embryological development major aortopulmonary collateral arteries (MAPCAs), which originate from descending thoracic aorta to anastomose, with the pulmonary arteries on their posterior aspect, at hilum, develops to supply the lungs. These fetal arteries regress with the normal development of pulmonary arteries or an alternate supply to the pulmonary arteries (e.g. PDA), and such patient does not have persistent MAPCAs. When flow from the right ventricle to the pulmonary arteries is absent or scarce, MAPCAs may persist and become tortuous to supply the pulmonary arteries.<sup>(8)</sup>

**Pulmonary Stenosis**

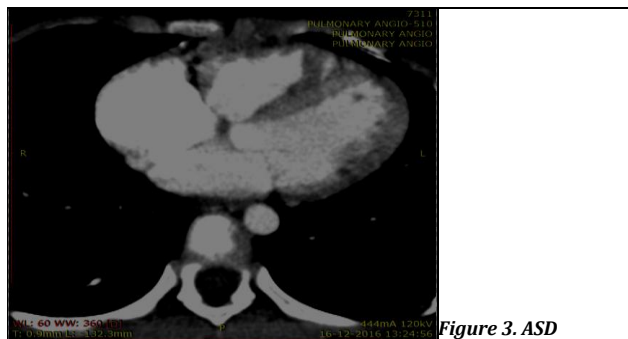
Pulmonic stenosis may be valvular, subvalvular, or supra-valvular. Among them supra-valvular is most common type (60%) and narrowing can occur anywhere from pulmonary trunk to the segmental arteries. Pulmonary valvular stenosis is a congenital disorder in 95% of cases. Pulmonary stenosis can be associated with CHD particularly in TOF, and also in cases of maternal rheumatic heart disease, Infective endocarditis or carcinoid syndrome.<sup>(8)</sup>



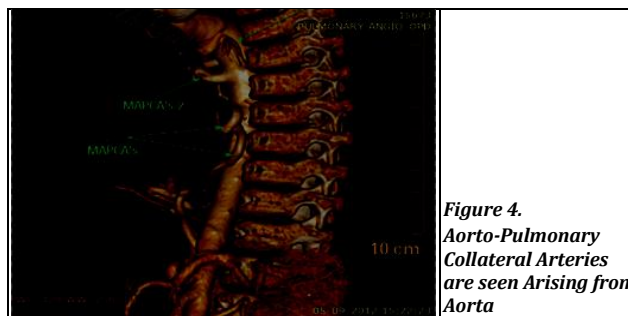**Figure 1. Severely Atretic Main Pulmonary Trunk with Small Calibre Bilateral Pulmonary Arteries**



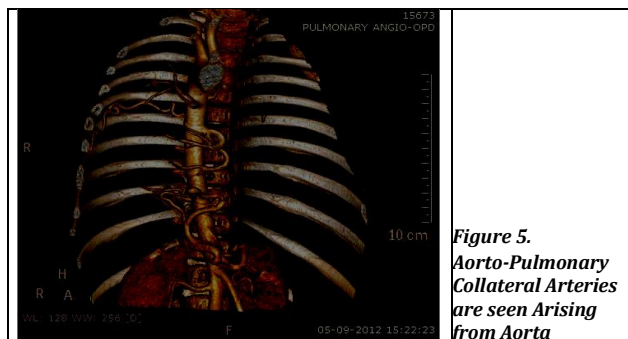
**Figure 2. VSD**



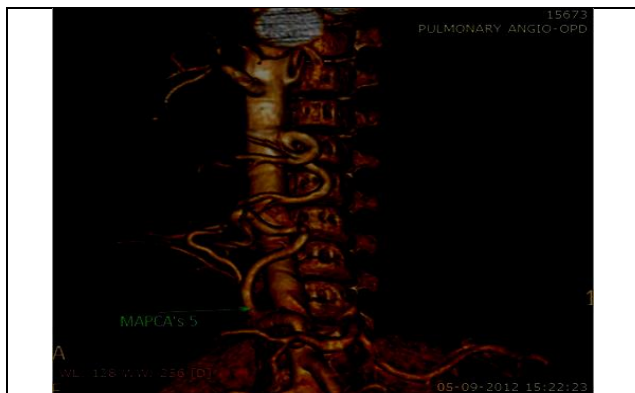**Figure 3. ASD**



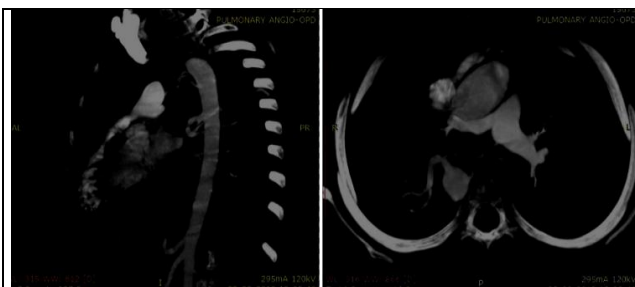
**Figure 4. Aorto-Pulmonary Collateral Arteries are seen Arising from Aorta**



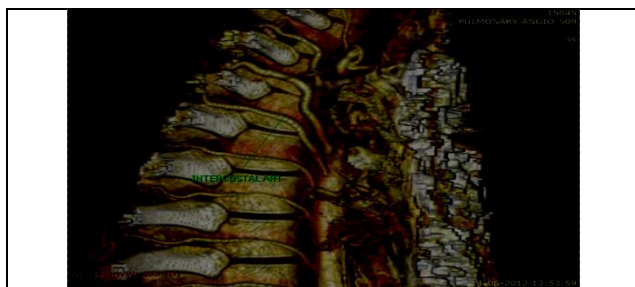**Figure 5. Aorto-Pulmonary Collateral Arteries are seen Arising from Aorta**



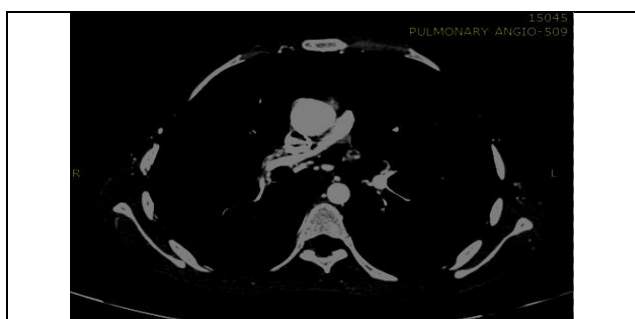
**Figure 6. Aorto-Pulmonary Collateral Arteries are seen Arising from Aorta**



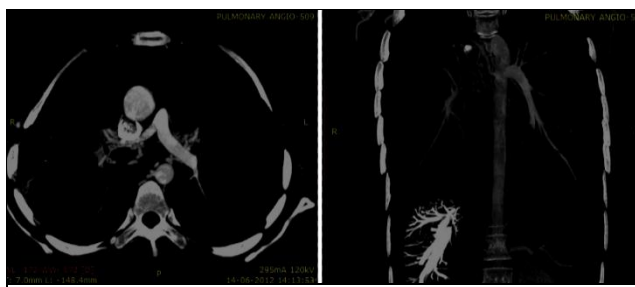
**Figure 7. Aorto-Pulmonary Collateral Arteries are seen Arising from Aorta**



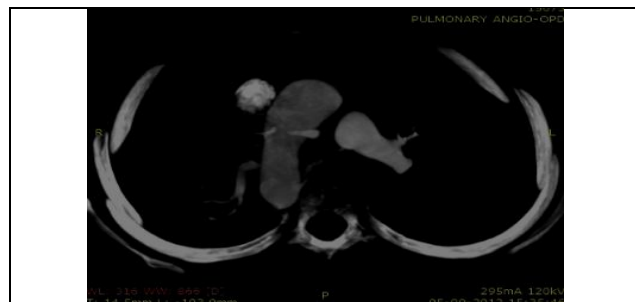**Figure 8. Dilated Intercostal Arteries**



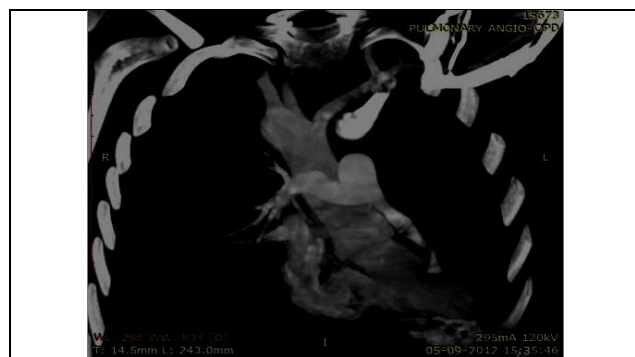**Figure 9. Axial Pulmonary CT Angiography Image Showing Narrowed Right Pulmonary Artery**



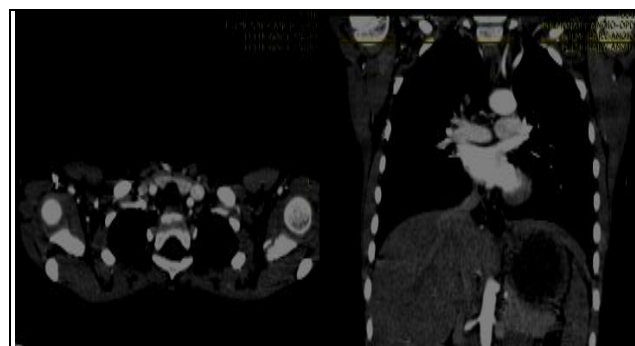
**Figure 10. Axial Pulmonary CT Angiography Image Showing Narrowed Pulmonary Arteries with Multiple Collaterals**



**Figure 11. Axial CT Pulmonary Angiography with Right Sided Aortic Arch**



**Figure 12. Coronal CT Pulmonary Angiography Showing Right Sided Aortic Arch with its 1<sup>st</sup> Branch Left Common Innominate Trunk, 2<sup>nd</sup> Branch Right Common Carotid Artery and 3<sup>rd</sup> Branch Right Subclavian Artery**



**Figure 13. Aberrant Origin of Left Vertebral Artery from Arch of Aorta**

**Aberrant Vessels**

Classically left vertebral artery originates from left subclavian artery; uncommonly it may have a variant origin in @ 5%, most commonly directly from arch of aorta as quoted by Tay KY and associates. (9) However Evan H. Einstein, and associates, analysed 27 cases by pathological autopsy and found that in four female cadavers the left vertebral artery did not originate from left subclavian artery but was originating directly from the aortic arch. So the prevalence rate comes to 14.8 %, and concluded that this anomaly is more prevalent than thought earlier, and may have implications for surgical practice.(10) We also noted this finding in one of our cases.

A series of 216 patients with TOF was investigated by catheterization, and post catheterization analysis was done by Sadia Saeed et al. They found Pulmonary Artery (PA) abnormalities in 84 (38.9%) patients. Isolated Left Pulmonary Artery (LPA) stenosis was noted in 27 patients (32.14%) and was the most common anomaly, second common abnormality was isolated Main Pulmonary Artery (MPA) hypoplasia in 18 patients (21.43%), supra-valvular stenosis was noted in 11



cases (13.1%), 2 patients had both absent right and left PA with segmental pulmonary branch arteries arising directly from MPA, while one patient had absent LPA only. Among associated cardiac lesions, in 34 (15%) cases right aortic arch was noted, muscular VSD found in 13 (5.5%) patients, 11 (6%) Patent had Ductus Arteriosus (PDA) and in 2 (1.9%) patients had Major Aortopulmonary Collateral Arteries (MAPCA). 10 (4.6%) children had significant coronary artery abnormality.<sup>(11)</sup>

A series of 265 patients with tetralogy of Fallot were analysed by Dabizzi RP and associates. These patients were investigated by catheterization and selective coronary angiography. Out of them associated cardiac anomalies were noted in 181 patients (68%). These associated cardiac anomalies had been isolated in 88 cases (49%) while in 93 patients there was associated more than one anomaly. In the cases of an isolated anomaly associated with TOF, the coronary tree was involved in 37.5% and the cardiovascular system in the remaining 62.5%. In the case of two anomalies, the coronary system was involved in 66% of the patients and the cardiovascular apparatus in 34%. In the case of three or more anomalies, the coronary arteries were involved in 71% and the cardiovascular system in 29%. Anomalies in the course and/or distribution of coronary arteries were present in 96 patients (36%): 10 patients had a single coronary ostium, 13 cases had a left anterior descending artery arising from the right coronary artery. In one case a circumflex artery arising from the right coronary artery. Small fistulas between coronary arteries and the pulmonary artery were found in 20 cases. An anastomosis between coronary and bronchial arteries or right atrium was found in 42 cases. In 39 patients they observed a large conus artery or large anterior ventricular branches crossing the right ventricle. 61 (23%) cases had shown an ostium secundum type atrial septal defect (ASD), three had a primum type atrial septal defect (ASD) with cleft of the mitral valve. In 56 patients (21%) a right aortic arch was detected by them. A stenosis of the trunk and/or the peripheral pulmonary artery was noted in 35 patients (13%), and pulmonary artery atresia was found in five patients. A complete atrioventricular canal was detected in four subjects. In 26 (10%) cases a patent ductus arteriosus (PDA) was noted. Anomalies of the systemic venous return were observed in eleven patients. Valvular abnormalities had been observed in 4 patients.<sup>(12)</sup>

A series of 155 patients is documented by Barakat Adeola Animasahun et al as TOF detected by echocardiography who were diagnosed between January 2007 and December 2014, out of a total of 3, 15, 150 patients who attended their study centre during the study period. Accordingly the prevalence of TOF amongst the children was 4.9 per 10 000. In this study, they found that 983 patients had congenital heart disease, out of them 311 patients had cyanotic congenital heart disease, and accordingly TOF was accounted for 15.8% of congenital heart disease and 49.8% of cyanotic congenital heart disease.<sup>(13)</sup>

In a retrospective study, 123 cases of TOF were discussed by Hu, B., and associates. Surgical confirmations of associated 159 extracardiac vascular deformities were noted by them. Patent ductus arteriosus (PDA) was commonest deformity, noted in 36 (22.64%) cases, followed by 29(18.24%) cases with right-sided aortic arch, and 23 (14.47%) cases of stenosis of pulmonary valve, among extracardiac vascular abnormalities. Associated extracardiac anomalies were better

diagnosed by Dual source computed Tomography (DSCT) in comparison to transoesophageal echocardiography (TEE); sensitivity was 92.45% vs. 77.07%; specificity was 99.81% vs. 99.42%, and diagnostic accuracy of 99.13% vs. 97.39% were noted on statistical analysis. Only relatively large aortopulmonary collateral vessels (APCVs) were identified by TEE, whereas regardless of the size of the vessels the DSCT could well visualize the origin, number, and lung lobes supplied by APCVs. Furthermore, among TEE and DSCT, an elaborative view of APCVs and their relationships with the large airways, possibly helpful in surgical planning, was provided only by DSCT. They observed that two cases of bicuspid pulmonary valve were missed by DSCT, whereas two cases of absent pulmonary valve syndrome and one case of quadricuspid pulmonary valve were missed by both modalities. The transfer of digital information to gray-scale images required by DSCT imaging may be a possible explanation for missing of such valvular details. Invasive catheter-related complications and high radiation dose are the major objections against using cardiac catheterization as the gold standard for cardiac hemodynamic evaluation. No association of radiation hazards makes MRI a promising imaging modality, however relatively lower spatial resolution with multiple contraindications such as electronic devices like pacemakers, sedation for longer duration are limiting factors in assessing the smaller extracardiac vascular deformities, particularly CAAs. Good quality images, using post-processing techniques with its high spatial and temporal resolution and rapid acquisition speed, in DSCT, is rapidly making it one of the most valuable modalities for intra and extra cardiac, cardiovascular examination.<sup>(14)</sup>

In our study, a 128 slice Multidetector CT scanner GE optima was used, to scan 21 patients with TOF. Defect in ventricular septum (VSD) was noted in all cases (n =21). Overriding of aorta was noted in nineteen patients (90%). Right ventricle was mildly hypertrophied (RVH) in 10 patients (47%). 8 patients (33%) were showing major aorto-pulmonary collateral circulation (collateral diameters ranged from 1 to 3.5 mm) and narrowing of pulmonic infundibulum was seen in 7 patients (28%), aortic arch was right sided in 5 cases (23%). Complex pulmonary artery morphology was seen in most of the patients. Pulmonary trunk and bilateral pulmonary arteries were significantly narrowed in 3 cases (14%); stenosis of main trunk and left pulmonary artery were noted in 2 cases (9%), right pulmonary artery and main trunk narrowing was seen in 4% (n=1), right pulmonary artery branch narrowing was noted at origin, measuring 2.4 mm with normal caliber of main pulmonary artery in 4% (n = 1), main trunk and right pulmonary artery narrowing was observed in 4%(n=1). Additionally, 3 cases (14%) showed aberrant vessels like left vertebral artery originating directly from aortic arch. Right ventricle was showing double outlet in two patients (9%). Associated ASD was noted in 2 cases (9%).

## CONCLUSIONS

Important additional information is obtained by using technically advanced Multidetector CT. Newer advances have

significantly increased the speed of CT machines, so we can complete the procedure of pulmonary CTA with ease of peripheral venous access and markedly reduced sedation time. No correlation was found between the size of pulmonary trunk and collaterals, which suggest that every patient has different chance of detecting collaterals; however as age increases, chances of getting collaterals also increases. Hence every patient should undergo cardiac CT especially pulmonary CT angiography before undergoing surgery.

#### REFERENCES

- [1] Becker AE, Connor M, Anderson RH. Tetralogy of Fallot: a morphometric and geometric study. *Am J Cardiol* 1975;35(3):402-12.
- [2] Spaziani G, Favilli S, Fonda C, et al. Giant aorto-pulmonary collaterals in pulmonary atresia and ventricular septal defect: long-term survival in unoperated adults. *J Cardiovasc Med (Hagerstown)* 2013;14(8):613-5.
- [3] Lluri G, Aboulhosn JA, Moriarty JM, et al. Applications of cardiac CT in the tetralogy of Fallot patient. *JACC: Cardiovascular Imaging* 2014;7(12):1276-9.
- [4] Fukui D, Kai H, Takeuchi T, et al. Longest survivor of pulmonary atresia with ventricular septal defect: well-developed major aortopulmonary collateral arteries demonstrated by multidetector computed tomography. *Circulation* 2011;124(19):2155-7.
- [5] Farouk A, Zahka K, Siwik E, et al. Individualized approach to the surgical treatment of tetralogy of Fallot with pulmonary atresia. *Cardiol Young* 2009;19(1):76-85.
- [6] Bertranou EG, Blackstone EH, Hazelrig JB, et al. Life expectancy without surgery in tetralogy of Fallot. *Am J Cardiol* 1978;42(3):458-66.
- [7] Boshoff D, Gewillig M. A review of the options for treatment of major aortopulmonary collateral arteries in the setting of tetralogy of Fallot with pulmonary atresia. *Cardiol Young* 2006;16(3):212-20.
- [8] Perloff JK. Congenital heart disease after childhood: an expanding population. 22nd Bethesda Conference, Maryland, October 18-19, 1990. *J Am Coll Cardiol* 1991;18(2):311-42.
- [9] Tay KY, U-King-Im JM, Trivedi RA, et al. Imaging the vertebral artery. *Eur Radiol* 2005;15(7):1329-43.
- [10] Einstein EH, Song LH, Villela NL, et al. Anomalous origin of the left vertebral artery from the aortic arch. *Aorta (Stamford)* 2016;4(2):64-7.
- [11] Saeed S, Hyder SN, Sadiq M. Anatomical variations of pulmonary artery and associated cardiac defects in tetralogy of Fallot. *Journal of the College of Physicians and Surgeons Pakistan* 2009;19(4):211-4.
- [12] Dabizzi RP, Teodori G, Barletta GA, et al. Associated coronary and cardiac anomalies in the tetralogy of Fallot. An angiographic study. *Eur Heart J* 1990;11(8):692-704.
- [13] Animasahun BA, Madise-Wobo AD, Omokhodion SI, et al. Children with tetralogy of Fallot in an urban centre in Africa. *J Cardiovasc Thorac Res* 2015;7(4):168-71.
- [14] Hu BY, Shi K, Deng YP, et al. Assessment of tetralogy of Fallot-associated congenital extracardiac vascular anomalies in pediatric patients using low-dose dual-source computed tomography. *BMC Cardiovasc Disord* 2017;17(1):285.