

# Approach to Lower GI Bleeding in Children

Anupam Ranjan<sup>1</sup>, Sweta Rani<sup>2</sup>, Mahesh Chaudhary<sup>3</sup>

<sup>1</sup>Department of General Surgery, A. N. Magadh Medical College and Hospital, Gaya, Bihar, India. <sup>2</sup>Department of Obstetrics and Gynaecology, A. N. Magadh Medical College and Hospital, Gaya, Bihar, India. <sup>3</sup>Department of General Surgery, A. N. Magadh Medical College and Hospital, Gaya, Bihar, India.

## ABSTRACT

### BACKGROUND

Rectal bleeding in children causes a great deal of anxiety amongst parents and thus requires appropriate assessment, explanation and treatment. Rectal bleeding in children accounts for approx. 10% to 15% of referrals to paediatric gastroenterologists. The incidence and prevalence of rectal bleeding in children are not well understood. Certain conditions like anal fissure and polyp are common in general practice. In majority of the cases, rectal bleeding in children is benign in nature but in some cases may indicate serious underlying pathology. Most common causes of bleeding in neonate are anal fissure, necrotising enterocolitis and malrotation with volvulus. Anal fissure is longitudinal ulceration or tear in distal anal canal epithelial segment. The pathogenesis is still not well understood, and it may differ between adults and children. Anal fissure develops in toddlers who have recent history of diet modification and change in consistency of stool. Necrotizing enterocolitis is common emergency condition among premature healthy infants. Incidence varies 0.3 to 2.4 infants/1000 birth. Pathogenesis remains unclear, it is believed that certain factors like infection, hypoxic condition, prematurity play an important role. The term malrotation refers to abnormalities related to intestinal position and its attachment and it includes the more recent concept of atypical malrotation or malrotation variant. Atypical malrotation results when the ligament of Treitz is to the left of midline. Regardless of the level of the bleeding primary focus of resection should be to restore the circulating volume with urine output of more than 1 mL/Kg/hr. The total blood volume in a newborn is 85 mL/Kg and 65 mL/Kg in infants. Rapid resuscitation can restore circulating volume. Therefore, a rapid push of 30 to 40 mL/Kg is required to restore intravascular volume. Red cell transfusion should be considered after loss of 30% of the circulating volume. In most patients with early shock, an initial fluid bolus of 20 mL/Kg of normal saline or lactated Ringer solution should be given rapidly (5–10 min). Intraosseous infusion should be considered in failed peripheral iv access. I will be dealing here with most common surgical causes of bleeding per rectum in children and their management.

### KEY WORDS

Rectal Bleeding in Children, Polyp, Colonoscopy, Laparotomy

*Corresponding Author:*

*Dr. Sweta Rani,  
Tutor Block-C, Room No. 3,  
A. N. Magadh Medical College and Hospital,  
Gaya-823001, Bihar, India.  
E-mail: swetaraniimt@gmail.com*

*DOI: 10.14260/jemds/2019/782*

*Financial or Other Competing Interests:  
None.*

*How to Cite This Article:*

*Ranjan A, Rani S, Chaudhary M. Approach  
to lower GI bleeding in children. J.  
Evolution Med. Dent. Sci. 2019;8(48):  
3624-3630, DOI:  
10.14260/jemds/2019/782*

*Submission 02-03-2019,  
Peer Review 10-11-2019,  
Acceptance 18-11-2019,  
Published 02-12-2019.2*



Gastrointestinal bleeding in infants and children is common in the practice of general paediatrics accounting for approx. 10% to 15% of referrals to paediatric gastroenterologists. Rectal bleeding in children cause a great deal of anxiety amongst parents and thus requires appropriate assessment, explanation and treatment. In majority of the cases rectal bleeding in children are benign in nature but in some cases may indicate serious underlying pathology [1],[2]. I will be dealing here with most common surgical causes of bleeding per rectum.

**Epidemiology**

The incidence and prevalence of rectal bleeding in children are not well understood. Certain conditions like anal fissure, polyp are common in general practices. Certain causes have to be focused and investigated accordingly.

	Upper GI Bleeding	Lower GI Bleeding
Neonate	Haemorrhagic disease of the newborn Swallowed maternal blood Stress gastritis Coagulopathy Vascular malformations	Anal fissure Necrotising enterocolitis Malrotation with volvulus
Infant (1 month to 2 yrs.)	Gastritis Esophagitis Hypertrophic pyloric stenosis Trauma secondary to gastrostomy tube Drug induced	Anal fissure Milk protein allergy (allergic proctocolitis) Intussusception Duplication of intestine Lymphonodular hyperplasia Infectious diarrhoea Eosinophilic gastroenteropathy
Child (>2 yrs.)/ older child	Peptic ulcer Oesophageal varices Gastric varices Gastritis Esophagitis Mallory-Weiss syndrome Trauma secondary to gastrostomy tube Eosinophilic gastroenteropathy Drug induced	Polyps Meckel's diverticulum Inflammatory bowel disease Lymphonodular hyperplasia Haemolytic uremic syndrome Infectious colitis Solitary rectal ulcer Fissure in ano Haemorrhoids Eosinophilic gastroenteropathy Vascular lesions Varices

**Table 1. Causes of Gastrointestinal Tract Haemorrhage**

**Anal Fissure**

Anal fissure is longitudinal ulceration or tear in distal anal canal epithelial segment. The pathogenesis is still not well stood, and it may differ between adults and children.[3] Anal fissure develops in toddlers who have recent history of diet modification and change in consistency of stool. Constipation often precedes a hard, bulky stool resulting in posterior midline tear below mucocutaneous junction. Fissure lead to further constipation aggravating the symptoms. Anal fissure presents with bright red of blood streaking on stool and Child cry while bowel movement. Split in anoderm most common located on posterior midline especially in male infants and anterior midline in female infants. The goal of treatment is to interrupt the vicious cycle of painful defaecation, stool retention, formation of hard stool and delay in healing of anal fissure. Anal fissure usually managed by sitz bath and an osmotic stool softener. Sitz bath promote good anal hygiene and relax the anal sphincter. A 0.2% nitro-glycerine ointment for 6-8 wks. and botulinum toxin (chemical sphincterectomy) popular treatment in adult. Topical use of Tacrolimus is new therapy. Surgical treatment includes fissurectomy, anal dilatation under GA and lateral internal sphincterectomy.

**Necrotising Enterocolitis**

Necrotizing enterocolitis is common emergency condition among premature healthy infants. Incidence varies 0.3 to 2.4

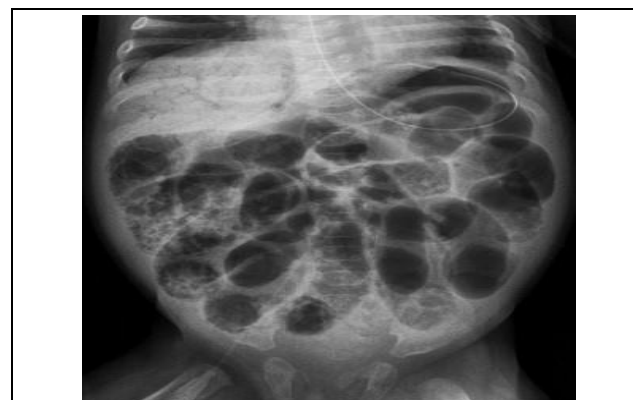
infants/1000 birth. Pathogenesis remains unclear, it is believed that certain factors like infection, hypoxic condition, prematurity plays important role[4]. All these condition leads to production of inflammatory mediators.

**Clinical Presentations**

Infants presents with variable symptoms like abdominal distention, blood in stool, feeding intolerance and are lethargic.

**Imaging**

X- ray abdomen may show Pneumatosis intestinalis (Fig. 1) is diagnostic of NEC. This is due to production of gas (mainly hydrogen gas) by bacterial fermentation. Portal venous air is associated with a worst prognosis. Pneumoperitoneum: - In a supine X-ray, the air will collect anteriorly (near the umbilicus) or might outline the falciform ligament. Bowel perforation may be present in 1/3 patients in the absence of pneumoperitoneum. Nonspecific findings include a localized dilated loop of bowel, thickened loops, ascites or a gasless abdomen.



**Figure 1. Intraluminal Pneumatosis**

**Laboratory Evaluation**

Commonly increased leukocyte counts, thrombocytopenia, electrolyte abnormalities, metabolic alkalosis, hypoxia seen. In approx. 30% cases bacteraemia is present so blood sample should be collected before use of antibiotics.

**Bell Clinical Staging**

- Stage I Suspicious (only clinical sign suggestive)
- Stage II Definite infant having pneumatosis intestinalis.
- (IIA: Mild illness, IIB: Moderately ill)
- Stage III Advance
- (IIIA: Impending perforation, IIIB: with Perforation)

**Treatment**

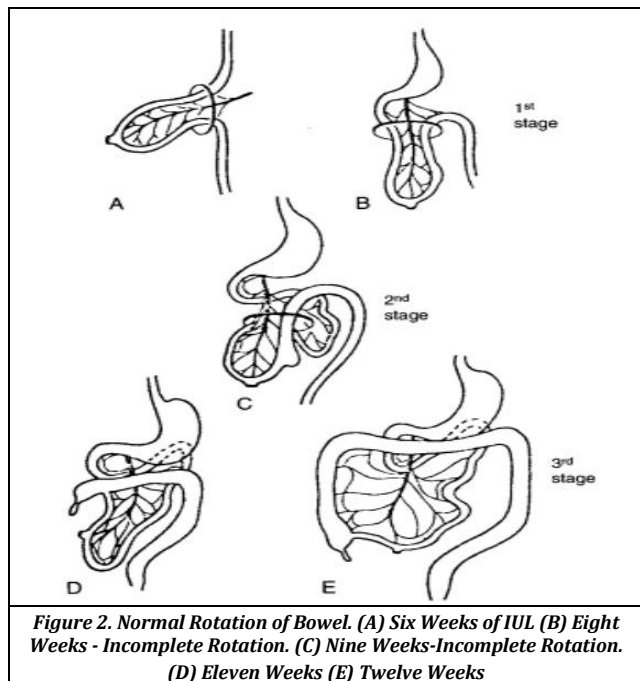
Medical management includes early bowel decompression, intravenous broad-spectrum antibiotic use, maintain volume/perfusion, pain control and early parenteral nutrition [5]. The surgical management of NEC remains controversial. Surgery is done when there is proven bowel perforation or clinical condition deteriorates [6].

**Malrotation with Volvulus**

The term malrotation refers to abnormalities related to intestinal position and its attachment [7] and it includes the more recent concept of atypical malrotation or malrotation

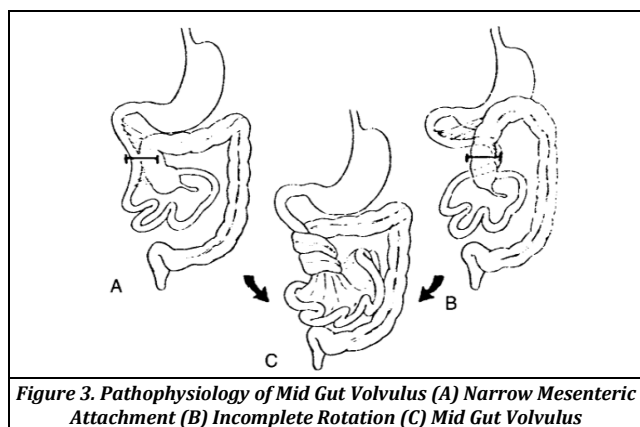
variant. Atypical malrotation results when the ligament of Treitz is to the left of midline.

**Normal Rotation and Fixation**



**Figure 2. Normal Rotation of Bowel. (A) Six Weeks of IUL (B) Eight Weeks - Incomplete Rotation. (C) Nine Weeks-Incomplete Rotation. (D) Eleven Weeks (E) Twelve Weeks**

In 4<sup>th</sup> weeks of fetal life bowel loop is straight tube with mild central bulging. SMA comes forward from posterior abdominal wall to the Centre of bulge thus extending in umbilical cord. The duodenojejunal loop continue to rotate during the extra coelomic phase of intestinal development. The small bowel is the first segment to return in abdominal cavity, the cecum and right colon return to abdomen last. Finally, at 10 weeks the intestines return to the abdomen. Duodenojejunal loop lies above the superior mesenteric artery and rotates 270 degrees in counter clockwise direction whereas cecocolic loop lies below the superior mesenteric artery and rotates 270-degree counter clock wise direction.



**Figure 3. Pathophysiology of Mid Gut Volvulus (A) Narrow Mesenteric Attachment (B) Incomplete Rotation (C) Mid Gut Volvulus**

**Clinical Manifestation**

**Acute Midgut Volvulus**

A narrow pedicle of mesentery predisposes to clockwise rotation from duodenum to transverse colon. Commonly occurs in first month of life.<sup>[8]</sup> Patients usually presents with sudden onset bilious vomiting or bleeding per rectum with on

and off crampy abdominal pain in previously healthy child <sup>[9]</sup>. Clinically lower abdomen may appear scaphoid. High degree of suspicion based on history, clinical findings, investigation either Doppler ultrasonography or upper GI contrast study is required. Laparotomy or laparoscopic evaluation may be required depending upon the general condition of the patient.

**Chronic Midgut Volvulus**

Lymphatic and venous obstruction is seen in intermittent or partial midgut volvulus. Most commonly occurs in children of more than 2 years old child.<sup>[10]</sup> Among the common complaint chronic vomiting is seen in (68%), colicky pain abdomen in (55%), diarrhoea seen in (9%), constipation and haematemesis.

**Imaging**

Ultrasonography is good screening device for infants suspected of having mid gut volvulus. “Whirlpool” flow pattern of the superior mesenteric vein and mesentery around the superior mesenteric artery best seen using colour Doppler imaging. An upper GI contrast study is now a days is the preferred study for evaluating a patient with a possible abnormality of intestinal rotation.

**Treatment**

Preoperative rapid intravenous resuscitation, placement of nasogastric tube, parenteral antibiotics followed by Ladd procedure. The following procedure is carried out in the proper sequence

- a. Evisceration of the bowel and inspection of the mesenteric root.
- b. Counter clockwise de rotation of the midgut volvulus.
- c. Lysis of Ladd’s peritoneal band, with straightening of the duodenum along the right abdominal gutter.
- d. Appendicectomy.
- e. Putting cecum in the left lower quadrant.

**Intussusception**

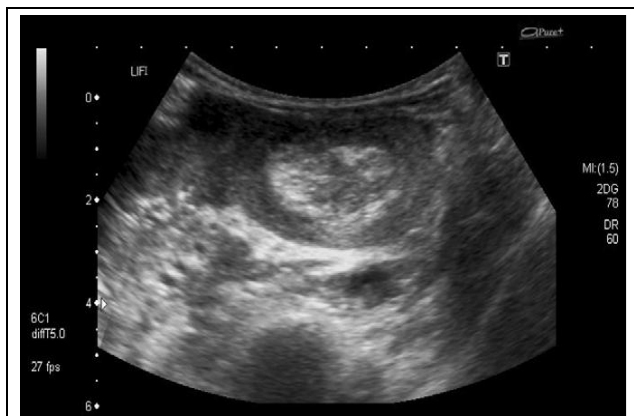Intussusception is defined as the invagination of proximal segment of intestine (intussusceptum) into the distal segment (intussusciptions). Ileo-colic (80%) type is common followed by ileo-ileal, ileo-colic or coli-colic. Intussusception leads to ischaemic necrosis due to bowel obstruction and vascular compromise. The theory says lead point is drawn inside due to peristalsis resulting in telescoping of the bowel segment. Microscopic examination usually shows hypertrophied lymphoid tissue (Peyer’s patches) at the age of weaning <sup>[11]</sup>. Certain pathological ‘lead points’ are Meckel diverticulum, polyps, duplication cyst, lymphoma, cystic fibrosis and haemangioma.

**Presentation**

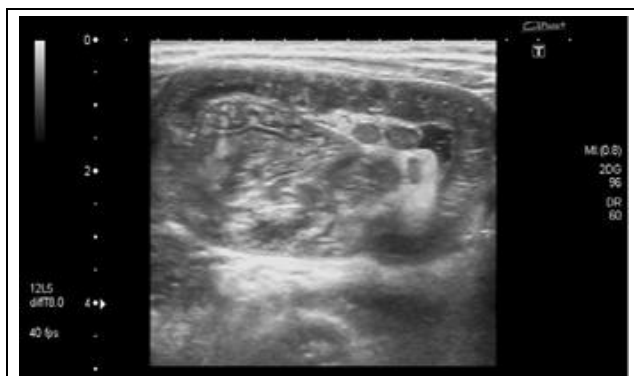Healthy infant present with intermittent colic abdominal pain with classical drawn up legs, screaming, pale look and are inconsolable. Symptoms last for few seconds. Vomiting and passage of blood per rectum (Red Currant Jelly) is seen in 60% of cases <sup>[12]</sup>. On clinical examination a palpable mass in the right upper side of the abdomen with empty Right lower quadrant (movement of cecum out of normal position) dance sign. An intussusception may prolapse or palpable on per rectal examination.

### Imaging

USG is investigation of choice. Cross-section view shows target sign (Figure 4), longitudinally pseudo-kidney sign (Figure 5). On abdominal X-ray features of intussusception include distal small bowel obstruction, a gasless colon and possibly the impression of a mass on the right side [3].



**Figure 4. Ultrasound Scan Showing the 'Target Sign' (Transverse View)**



**Figure 5. Ultrasound Scan Showing the 'Pseudo-Kidney Sign' (Longitudinal View)**

Barium enema shows filling defect (crescent sign), double contrast (air and water soluble) can also be done.<sup>[14]</sup>

### Treatment

The patient requires supplemental oxygen an appropriately sized Nasogastric tube for gastric decompression and intravenous access. Isotonic intravenous fluid such as 0.9% normal saline or Hartmann's solution should be given initially as a 20 ml/Kg bolus and if necessary repeated twice. IV antibiotic (cefuroxime and metronidazole) are started and should be given before reduction is tried.

### Nonoperative Management

Hydrostatic reduction by enema is the diagnostic and therapeutic procedure of choice. It is Contraindicated in peritonitis or hemodynamic instability. Hydrostatic reduction using saline is the mainstay of therapy; however now a days the use of air enema has become more common . In 80% of cases successful reduction is done and can be confirmed by reduction of the mass, along with reflux of air into the proximal ileum. Intussusception reduction by saline enema under ultrasound surveillance is done in order to avoid radiation. Recurrence rates following hydrostatic reduction is

approximately 11% and usually within the first 24 hours. Another attempt of hydrostatic reduction is tried for second recurrence. Operative management is indicated for third recurrence.

### Operative Management

Presence of peritonitis when suspected is indication for operative intervention. Conditions like bowel obstruction, recurrence or failure of reduction require surgical intervention. Laparoscopic evaluation can be done for diagnostic and therapeutic purpose. The recurrence is very low following surgery.

### Milk Protein Allergy

Milk protein allergy leads due to immune reaction to offending antigen like lactoglobulin, case in, bovine serum, albumin, lactalbumin. This leads to occult or severe blood loss, other symptoms include irritability, failure to thrive, diarrhoea, vomiting. Manifests as three type 1. Acute watery diarrhoea 2. chronic diarrhoea 3. excessive blood and protein loss. Peripheral blood and stool examination show eosinophils, biopsy specimen from bowel loop can also be done. Acute and chronic symptoms usually subside 48 hrs or within 2 weeks respectively after cessation of milk intake.

### Intestinal Duplication

Intestinal duplication is the mucosa line structure which are in continuity with the gastro-intestinal tract. Although they can occur at any level in the GI tract, duplications are found most commonly in the ileum. Duplications may be long and tubular but are generally cystic masses. In all cases, they share a common wall with the intestine. Symptoms include recurrent abdominal pain, emesis from intestinal obstruction, and haematochezia. Bleeding occurs from the ulcerated duplication segment or due to presence of ectopic gastric mucosa. A palpable lump is usually found on clinical examination. Children may also develop intestinal obstruction. Torsion may produce gangrene and perforation. Investigations like ultrasonography, CT Scan or technetium pertechnetate, barium meal follow through, barium enema can be done. Excision of segment followed by end to end anastomosis for short segment and for large segment multiple enterotomies and mucosal stripping can be done. An alternative method is to divide the common wall using a linear cutting stapler to form a common lumen.

### Meckel's Diverticulum

Meckel's diverticulum results from failure of the proximal omphalomesenteric duct to obliterate. Abnormal regression can result in cysts, fibrous bands linking the intestine to the abdominal wall, umbilical sinuses and complete persistence (patent vitelline duct) as an omphalo-ileal fistula. Meckel's diverticulum is the most common Vitelline duct anomaly located at anti-mesenteric border of the small bowel; it is a true intestinal diverticulum.

### Rule of 2s (Mnemonic) for Meckel's Diverticulum

The diverticulum is within 2 feet of the end of the small intestine, 2 inches in length, occurs in about 2% of the population, is twice as common in males as in females, is often symptomatic by 2 years of age, and contains two types of Heterotopic mucosa gastric and pancreatic. At least 5 feet

of small bowel should be examined in older children to document the absence of Meckel's diverticulum. Gastric tissue and pancreatic tissue predominate with incidence of approx. 60-85% and 5-16% respectively. Other types of mucosa (Colonic, endometrial, pancreatic islets) are quite rare. Elective resection of incidentally discovered diverticula is indicated in uncomplicated patients with palpable thickening suggestive of heterotopic mucosa in those with a history of unexplained abdominal pain, and in patients with abdominal wall attachments. Elective resection is contraindicated in immunocompromised patients, in patients undergoing insertion of prosthetic material and in babies with Gastroschisis [15]. The most common complication following elective removal is adhesive bowel obstruction, occurring in approx. 5% to 10% of patients.

### Clinical Manifestation

Common presentation of a Meckel's diverticulum are bleeding, obstruction, and inflammation.

### Bleeding

Bleeding is the most common symptom of Meckel's diverticulum. An ulcer is often found at the junction between the ileal and heterotopic gastric mucosa in the diverticulum, but it may be within the heterotopic mucosa or in adjacent normal ileum on the mesenteric side opposite the diverticulum. These ulcers are often small and can be identified only by histopathological examination. Bleeding is generally painless, frequently episodic, and sometimes massive. Stools may be bright red, brick red, or maroon. Tarry stools are uncommon. A significant decrease in the haemoglobin level is often observed.

### Obstruction

Meckel's diverticulum can cause intestinal obstruction by one of several mechanisms: intussusception (Most common), volvulus, internal hernia, an inflammatory process and prolapse through a patent vitelline duct.

### Inflammation

Inflammatory signs of a Meckel's diverticulum usually present at a later age and are often mistaken for appendicitis.

### Investigation

Technetium 99m scans is used to detect heterotopic gastric mucosa. Perchnetate ions carrying the technetium 99m isotope are stored and secreted into the lumen of the bowel by gastric mucosal cells. Bleeding from an intestinal duplication with ectopic gastric mucosa may result in a positive technetium scan.

### Management

A Meckel's diverticulum can be removed either by simple resection of the diverticulum and transverse closure across the base or by resection of a short segment of ileum containing the diverticulum and re anastomosis. Ulceration are usually opposite to diverticulum on mesenteric borders. The feeding (diverticular) artery on the surface of the ileum should be clearly identified and ligated. Concomitant incidental appendectomy is often performed. Overall, the results of diverticulectomy for bleeding are excellent.

In case of obstruction Preoperative preparation consists of intravenous hydration, correction of electrolyte abnormalities, nasogastric decompression, and antibiotics (especially if strangulation is suspected). After resuscitation, end to end anastomosis of the bowel after resection of involved segment.

### Polypoid Diseases of the GI Tract

Polypoid diseases (Juvenile, lymphoid, and adenomatous polyps), uncommon syndromes containing polyps, and disorders (Peutz-Jeghers' syndrome, Gardner's syndrome, and Turcot's syndrome). Most common cause of rectal bleeding in toddler and preschool are polyp of gastrointestinal tract. Most common poly juvenile (80%) followed by lymphoid (15%) and adenomatous (3%).

### Classification of Juvenile Polyp-

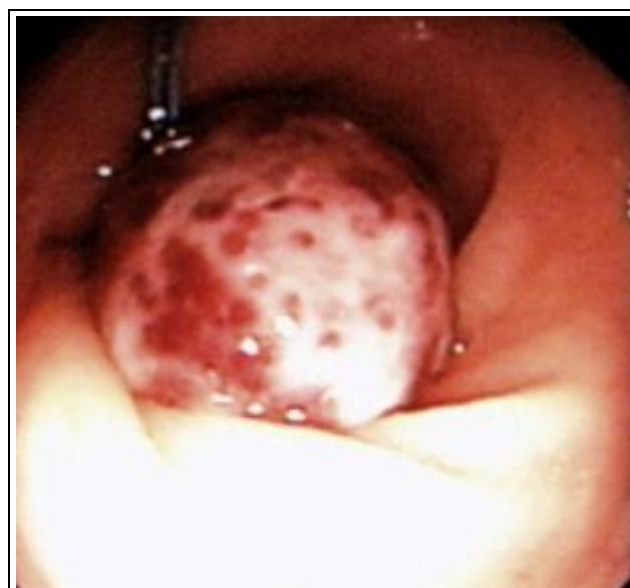1. Isolated Juvenile Polyps (Non-malignant): fewer than five polyps confined to the colon without a family history
2. Juvenile Polyposis Syndromes (Malignant potential)
  - a. Diffuse juvenile polyposis of infancy: patients younger than 6 months of age.
  - b. Diffuse juvenile polyposis: patients 6 months to 5 years of age.
  - c. Juvenile polyposis coli: confined to the distal colon and rectum in patients 5 to 15 years of age.

### Juvenile polyps

Polyps ranges from 2 mm to several centimetre having glistening, smooth surface, long pedicle and often ulcerated surface leading to bleeding. Peak incidence is 3 to 5 year of life.

### Clinical Presentation

The most common presenting symptom is bleeding (93%), Abdominal pain (10%), which is believed to be caused by traction on the polyp from peristaltic activity, and prolapse of the polyp (4%). Many juvenile polyps will auto amputate, resulting in spontaneous cessation of rectal bleeding.



*Figure 6. Colonoscopy in a Child with Rectal Bleeding Revealing a 2 cm Polyp in the Sigmoid Colon*

### Familial Adenomatous Polyposis

It is defined as the presence of at least 100 visible adenomatous polyps in the large intestine. Two types sparse type, which is characterized by hundreds of polyps, and profuse type, which is characterized by thousands of polyps. Most of patients are asymptomatic, mainly identified by routine surveillance because of family history. Malignancy develops in nearly all patients of FAP if left untreated. Most patients are asymptomatic, but some present with increased frequency of defecation, rectal bleeding, anaemia, and abdominal pain. Most (90%) are identified by routine surveillance because of a familial history of adenomatous polyposis. Polyps are found in the stomach in up to 50% of patients with FAP. Irrespective of the age total colectomy with a rectal mucosectomy and an ileoanal pouch procedure has become the preferred operation for children with FAP.

### Peutz-Jeghers Syndrome

It is characterized by melanotic spots on the lips, mouth, and on the buccal mucosa. The polyps are mainly confined in the small intestine (55%), in the stomach and duodenum (30%) and colon and rectum (15%). There is a mutation of a novel serine/threonine kinase (LKB1 or STK11) with loss of kinase activity. Patient present with abdominal pain related to transient intussusception of a polyps and anaemia resulting from occult blood loss and melanotic pigmented spots. Extraintestinal tumours associated with Peutz-Jeghers syndrome include ovarian, cervical, and testicular neoplasms, Cancer of the breast, thyroid, bile duct, pancreas, and gallbladder. All polyps larger than 0.5 mm found at endoscopy should be removed. Laparotomy with intraoperative enteroscopy is recommended for removal of all small bowel polyps greater than 15 mm in diameter.

### Gardner's Syndrome

Colonic FAP an autosomal dominant pattern associated with the extracolonic findings of multiple osteomas, fibromas, and epidermoid cysts. Desmoid tumours of the abdominal wall and mesentery of the small intestine occur in approximately 20% of patients.

### Turcot's Syndrome

Colonic FAP associated with the brain tumour (Glioblastoma and Medulloblastoma) Ependymomas and carcinoma of the thyroid (usually papillary in origin)

### Meckel's Diverticulum.

Discussed above.

### Inflammatory Bowel Disease (IBD)

The term IBD comprises Crohn's disease (CD) and ulcerative colitis (UC). Patients mainly presents with abdominal pain and bloody diarrhoea. Stool culture and duration of diarrhoea differentiate from infectious colitis. Bloody diarrhoea is uniformly present in UC, pain develops when colitis becomes severe whereas in CD presenting symptom is pain abdomen not always associated with diarrhoea. Due to extension of mucosal inflammation to colonic smooth muscle leads to destruction of ganglion cells leading further to toxic megacolon, stricture or fistula formation over period of time. Sigmoidoscopy or colonoscopy, typical biopsy findings,

negative stool culture helps to reach at the diagnosis. In CD bowel wall may be thickened at places with normal intervening tissue giving cobble stone appearance. In UC bowel wall is thin with continuous inflammation with no intervening healthy tissue. In IBD, the mainstay of treatment is 5 ASA medication and corticosteroids. Certolizumab and Adalimumab are currently used in CD.

### Infectious Colitis

A child presenting with diarrhoea and lower GI bleeding should be evaluated for infectious colitis. Symptoms may be indistinguishable from those of inflammatory bowel disease but can easily be excluded with stool cultures. Clostridium difficile should be considered in any child with a history of prior antibiotic therapy. Oral metronidazole (Flagyl) or vancomycin for 10 days is effective in about 95% of patients. Other bacteria such as Escherichia coli (O157:H7), Salmonella, Shigella, and Campylobacter are invasive and can cause bloody diarrhoea. These infections are usually self-limited and require only supportive care, except for those who are severely ill.

### Rarer Causes

- Sexual abuse may present with rectal bleeding. A high index of suspicion in the clinician will be alerted by unusual features in the history or examination.
- Hirschsprung's enterocolitis
- Solitary rectal ulcer syndrome: Usually presents in older children ( $\geq 8$  years old). Mucorrhoea, constipation, tenesmus and rectal prolapse are often seen.
- Vascular lesions: Includes a range of haemangiomas, arteriovenous malformations and angiodysplasias which can be difficult to detect even with new techniques. Colonoscopy and arteriography are used to localise bleeding.
- Henoch-Schonlein purpura.
- Haemolytic uraemic syndrome
- Acquired thrombocytopenia.

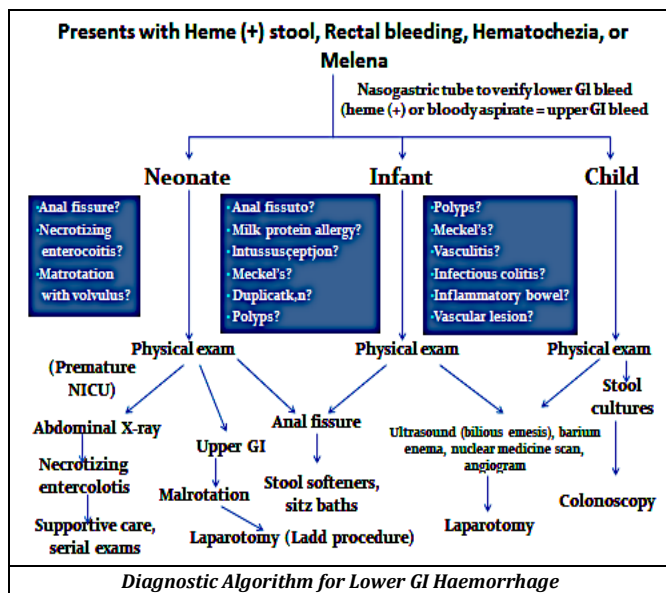
### Management

Management includes resuscitation, investigation and treatment of the cause. Most of the bleeding are simple and self-limiting require proper reassurance and explanation.

### Management of LGIB

- General Management-** Resuscitation and initial assessment.
- Cause Specific Management-** Regardless of the level of the bleeding primary focus of resection should be to restore the circulating volume with urine output of more than 1 mL/Kg/hr. The total blood volume in a newborn is 85 mL/Kg and 65 mL/Kg in infants. Rapid resuscitation can restore circulating volume. Therefore, a rapid push of 30 to 40 mL/Kg is required to restore intravascular volume. Red cell transfusion should be considered after loss of 30% of the circulating volume. In most patients with early shock, an initial fluid bolus of 20 mL/Kg of normal saline or lactated Ringer solution should be given rapidly (5–10 min). Intraosseous

infusion should be considered in failed peripheral iv access.



**REFERENCES**

[1] Bulstrode NW, Cuckow PM, Spitz LS. Neonatal gastrointestinal pseudo-haemorrhage. *J R Coil Surg Edinb* 1998;43(5):355-6.

[2] Teach SJ, Fleicher GR. Rectal bleeding in pediatric emergency department. *Ann Emerg Med* 1994;23(6):1252-8.

[3] Nelson R. Nonsurgical therapy for anal fissure. (Cochrane review). In *The Cochrane Library*, Issue 2. Chichester, UK: John Wiley & Sons 2004.

[4] Caplan MS. Pathogenesis and prevention of neonatal necrotizing enterocolitis. In: Polin RA, Fox WW, Abman SH, eds. *Fetal and neonatal physiology*. 3<sup>rd</sup> edn. Philadelphia: Saunders 2004.

[5] Sato TT, Oldham KT. Abdominal drain placement versus laparotomy for necrotizing enterocolitis with perforation. *Clin Perinatol* 2004;31(3):577-89.

[6] Bell MJ, Ternberg JL, Feigin RD, et al. Neonatal necrotizing enterocolitis. Therapeutic decision based upon clinical staging. *Ann Surg* 1978;187(1):1-7.

[7] Balthazar EJ. Intestinal malrotation in adults. Roentgenographic assessment with emphasis on isolated complete and partial nonrotations. *Am J Roentgenol* 1976;126(2):358-67.

[8] Seashore JH, Touloukian RJ. Midgut volvulus. An ever-present threat. *Arch Pediatric Adolescence Med* 1994;148(1):43-6.

[9] Powell DM, Othersen HB, Smith CD. Malrotation of the intestines in children: the effect of age on presentation and therapy. *J Pediatr Surg* 1989;24(8):777-80.

[10] Spigland N, Brandt ML, Yazbeck S. Malrotation presenting beyond the neonatal period. *J Pediatr Surg* 1990;25(11):1139-42.

[11] Bramson RT, Blickman JG. Perforation during hydrostatic reduction of intussusception: proposed mechanism and review of the literature. *J Pediatr Surg* 1992;27(5):589-91.

[12] Fox VL. Gastrointestinal bleeding in infancy and childhood. *Gastroenterol Clin North Am* 2000;29(1):37-66, v.

[13] Beasley S. Intussusception. *Pediatric Radiology* 2004;34:302.

[14] Campbell JB. Contrast media in intussusception. *Pediatr Radiol* 1989;19(5):293-6.

[15] De Bartolo HM Jr, van Heerden JA. Meckel's diverticulum. *Ann Surg* 1976;183(1):30-3.