

SURGICAL FEEDING GASTROSTOMY - USE OF ENDOTRACHEAL TUBE IN PLACE OF CONVENTIONAL TUBES: OUR EXPERIENCE

N. Srinivasa Rao¹, S. Zwalitha², K. Babji³

HOW TO CITE THIS ARTICLE:

N. Srinivasa Rao, S. Zwalitha, K. Babji. "Surgical Feeding Gastrostomy - Use of Endotracheal Tube in Place of Conventional Tubes: Our Experience". Journal of Evolution of Medical and Dental Sciences 2015; Vol. 4, Issue 28, April 06; Page: 4884-4888, DOI: 10.14260/jemds/2015/708

ABSTRACT: Surgical feeding gastrostomy (FG) is still done for inoperable carcinoma esophagus, corrosive poisoning for enteral feeding. Conventionally a Malecot's catheter or G-tube are used for FG. The Malecot" tube frequently gets frequently blocked. Commercial G-tubes are expensive and not easily available. As an alternative we used cuffed endotracheal tube which is self-retaining and has got a wide diameter throughout and an opening near the tip both of which make it unlikely to get blocked. **MATERIALS AND METHODS:** A total of 42 cases of ca esophagus/ corrosive injury needed FG in two years period. Of which in 23 cases we used endotracheal tube. All the patients are evaluated for quantity and quality of feed that can be given, peristomal pain, peritubal leakage and infection, slipping of tube, and tube blockage. **RESULTS:** In all patients in whom ET tube was used quality and quantity of feeds were more, no slipping of tube and no blockage. In three cases there was minimal leakage which reduced in three days. Peritubal pain due stiffness of tube could be overcome by immersing in boiled saline. Overall patient satisfaction is good which made us to recommend as an economical alternative to costly commercial G-tube.

KEYWORDS: Endotracheal tube, enteral feeding, Surgical Feeding gastrostomy.

INTRODUCTION: Feeding access is needed for enteral feeding in case of difficulty in swallowing due to neurological disease or luminal obstruction on a long term basis. The indications include neurological disorders like bulbar palsy, luminal obstruction like carcinoma esophagus/post cricoid carcinoma or corrosive stricture of esophagus either as preoperative enteral access or as a definitive procedure (In case of inoperable tumors).^{1,2} Though a feeding jejunostomy is preferred FG has got the advantage of large quantity feeds and no need for predigested foods.^{3,2} Though PEG has been established as a preferred procedure, difficulty or impossibility to enter into stomach, inability to approximate anterior wall of stomach to anterior abdominal as in case of ascites or obesity, hepatomegaly makes surgical FG a definite option.^{4,5,6}

In surgical FG the tube used is a Malecot's catheter, Foley's catheter or commercially available G-tube.¹ Malecot's catheter is more commonly used. The disadvantages with Malecot's catheter are that it frequently gets blocked as it has the flower which present at the end of the tube and its lumen is narrow at the tip, preventing use of solid bolus feeds. Moreover as it is made of India rubber, sometimes it produces skin reactions. Added to this, the expulsion rate is high as the self-retaining part i.e., the flower gets destroyed. Foley's has almost the same disadvantages. The commercially available G-tubes are expensive thus preventing their use in govt. hospitals in developing countries and are not available in many parts.

So we started using the cuffed ENDOTRACHEAL TUBE (which is used in anesthesia) in our patients. Which is easily available and inexpensive (Rs. 60-120 vs Rs. 1700-2500 for G-tube) in place of above tubes. The advantages of cuffed ET Tube are that it is self-retaining due to its cuff and its

ORIGINAL ARTICLE

diameter is uniform throughout so that more solid food can be given through it. As the initial results are good we continued using it and here we share our experience with this tube.

MATERIALS AND METHODS: A total of 42 feeding gastrostomies were performed in GGH, Kakinada, in two years period. All are Stamm gastrostomies and by open technique. Indications are:

- ca esophagus - 26,
- Post cricoid carcinomas - 14,
- Corrosive strictures -2. All are adults only.

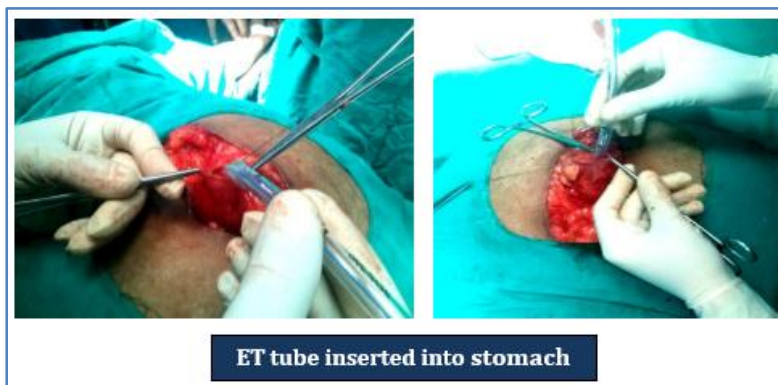
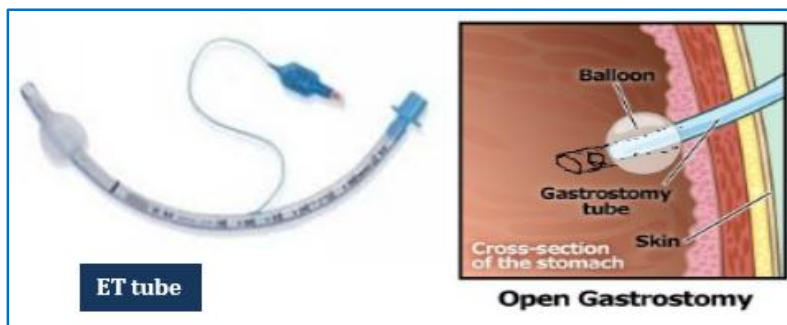Among these cases in 19 we used conventional Malecot's catheter and in 23 we used porcelain endotracheal tubes. Two of them were in whom previously we used Malecot's catheter but it slipped and through gastrostomy wound we introduced ET tube. We did not use G-tube in any patient as our patients could not afford it. Conventional open technique with two layered purse string performed (Stamm).⁷ The tubes are brought thro' a separate incision.

For all these patients, the advantages of the tube are explained and due consent is taken. Approval from the hospital ethical committee is taken.

Post operatively these patients are evaluated for:

1. Peri stomal pain,
2. Peritubal leakage and infection,
3. Slipping of the tube, and
4. Tube blockage.

The quality and quantity of the feed that can be given is also noted as is the overall patient satisfaction.



ORIGINAL ARTICLE

RESULTS: In all the patients the quantity of each feed that can be given is more by 250- 300 ml. More solid and non-predigested food (which is very expensive) could be given. No patient has reported blockage of the tube in spite of more solid food. In none of the cases there was slipping of gastrostomy tube. In three cases there was minimal leakage peri- tubally which has subsided in three days.

In the initial part of the study 4 patients reported more peri-tubal pain probably due to stiffness of the tube. We could overcome this problem by immersing the tube in boiled saline for 10 minutes which makes it suppler. The results are depicted in the following table.

| | |
|----------------------------------------------------|---------------|
| 1. Total no of patients under went FG | 42 |
| 2. Endotracheal tube used as FG tube in | 23 |
| 3. Quantity that can be given in each feed | 500 ml-700 ml |
| 4. Peritubal leak | 3 (13. 8%) |
| 5. Peri tubal pain | 4 (17. 3%) |
| 6. Tube blockage | 0 |
| 7. Tube slipping | 0 |
| 8. Peritubal skin reactions | 0 |
| 9. Early death -due to aspiration (within 30 days) | 2 (8.69%) |

TABLE 1

DISCUSSION: Enteral nutrition is proved to be better and safer whenever it is possible and should be route of choice if absorptive GI tract is adequate.^{8,6} The indications for enteral nutrition include difficulty in swallowing by neurological conditions or facial trauma, and luminal obstruction caused by malignant or benign strictures of esophagus and head and neck tumors. Nasogastric tube feeding can be done for short term needs but an enteric access is needed for long term need.² Enteric access can be secured by either a feeding jejunostomy FJ or a feeding gastrostomy FG. Though FJ is safer has got limitations of smaller tubes, lesser quantity of feeds and need for predigested formulas which are costly.³ FG has got the advantage of larger reservoir capacity of stomach hence larger quantity of feeds.

Presently Feeding gastrostomy can be performed by Endoscopy (PEG) or by surgery (Laparoscopic or Open). PEG (percutaneous endoscopic gastrostomy) is performed through endoscopy and is least invasive and most preferred.^{9,2,4,5} It has got limitation of endoscopic access and cannot be performed in case of obstructive tumors of esophagus and pharynx and maxillofacial injuries. More importantly the stomach has to be approximated to anterior abdominal wall.¹⁰ So in cases of ascites, hepatomegaly and adhesions due to previous surgery prevents performing PEG. In all the above conditions surgical FG is the only option available, be it open or laparoscopic.

Routinely while performing open FG, the tubes used are a Malecot's catheter, a Foley's catheter or the more expensive G-Tube.^{1,11} G-tube is ideal, but it is very expensive (Rs. 1700- 2500) and is not easily available. Malecot's catheter and Foley's are more frequently used. However, these tubes also have their limitations, such as obstruction by diet residues, easy displacement, the need for periodic replacement.¹¹ More over the quantity of each feed is small for fear of blockage and overflow. They have also disadvantage of skin reaction to the material with which they are made.

ORIGINAL ARTICLE

ENDOTRACHEAL TUBE is made of PVC, has got a cuff for self-retention, and has a uniform diameter which makes it suitable for larger volumes. It is non-sticky, has got two openings at its end (One at end, another near the end on the opposite side). This makes it unlikely to block even with thickest of residues. Hence a larger bolus of feed which contains near normal food can be given. The quantity of feed is also considerably larger.

All our 23 patients are able to take feeds in excess of 500 ml (up to 750 ml). More importantly they are able to take their normal food in a grinded form which was not possible with our other patients in whom other tubes were used. This significantly added to their nutritional status. Whatever the type of food they received, none of the tubes blocked any time during its usage. This is in contrast to our patients in whom we used Malecot's or Foleys.

Tube displacement/slipping is a frequent problem with FG patients with use of Malecot's as the flower frequently gets macerated. Many a time this leads to replacement of the tube which may need a repeat surgery. ET tube has got a cuff which snugly fits to the inner surface of stomach and hence less likely to slip. We did not find a single case of slipping of tube among all 23 cases. This is clear advantage over the other tube FGs.

We found peritubal leakage in 3 patients (13.8%) which reduced in three days. We managed this by further inflating the cuff by another 2ml of air. None had any signs of peritonitis.

The initial four of our patients, there is significant peritubal pain even after fourth day of surgery. This can be attributed to stiffness of the ET tube which made of PVC. We overcome this by immersing the tube in boiled saline for 10 mts. which made it suppler. In later cases we did not find this problem. Surprisingly the cuff is intact.

Our patients suffered other complications of FG like aspiration pneumonia, lung collapse and GERD just like in any other patients with FG. Usage of the ET tube neither decreases nor adds to these complications. We do not claim that this improves survival. Our early mortality rates (8.69%) are comparable with other studies.¹²

CONCLUSION: As a whole usage of ET tube in FG has increased total enteral intake, improved nutritional status and decreased minor complications. This definitely adds to the quality of life and makes the patients more suitable for other modalities of therapy like Radiotherapy and chemotherapy. We found majority of our patients belong to lower socio economic group and cannot afford costly devices like G-tube and hence ET tube can be considered as an economical alternative to costly G-tube and Malecot's or Foley's catheter which have more complications.

REFERENCES:

1. ASGE Technology Committee, Kwon RS, Banerjee S, Desilets D, Diehl DL, Farraye FA, et al. Enteral nutrition access devices. *Gastrointest Endosc.* 2010; 72 (2): 236-48.
2. Enteral feeding. Nasogastric, nasojejunal, percutaneous endoscopic gastrostomy, or jejunostomy: its indications and limitations C B Pearce and H D Duncan, *Postgrad Med J* 2002 78: 198-204.
3. Burtch GD, Shatney CH, feeding jejunostomy vs gastrostomy, *The American Surgeon* [1987, 53 (1): 54-57].
4. Gauderer MW, Ponsky JL, Izant RJ Jr. Gastrostomy without laparoscopy: a percutaneous endoscopic technique. *J Pediatr Surg.* 1980; 15 (6): 872-5.

ORIGINAL ARTICLE

5. Ljungdahl M, Sundbom M. Complication rate lower after percutaneous endoscopic gastrostomy than after surgical gastrostomy: a prospective, randomized trial. *Surg Endosc.* 2006; 20 (8): 1248-5.
6. Advantages of enteral nutrition over parenteral nutrition, David S. Seres, Monika Valcarcel, Alexandra Guillaume, *Therap Adv Gastroenterol.* 2013 March; 6 (2): 157-167.
7. Stamm M. Gastrostomy: a new method. *Med News.* 1894; 65: 324.
8. Mac Fie, J. (2000), Enteral versus parenteral nutrition. *Br J Surg*, 87: 1121-1122.
9. Grant JP. Comparison of percutaneous endoscopic gastrostomy with Stamm gastrostomy. *Ann Surg.* 1988; 207 (5): 598-603.
10. Pisano G, Calò PG, Tatti A, Farris S, Erdas E, Licheri S, et al. Surgical gastrostomy when percutaneous endoscopic gastrostomy is not feasible: indications, results and comparison between the two procedures. *Chir Ital.* 2008; 60 (2): 261-6.
11. Farquharson's textbook of operative surgery, 7th edition: 362.
12. Christophe Bezerra AnselmoI; Valdir Tercioti Junior, TCBC-SPII; Luiz Roberto Lopes, TCBC-SPIII; João de Souza Coelho Neto, TCBC-SPIV; Nelson Adami Andreollo, TCBC-SPV, Surgical gastrostomy: current indications and complications in a university hospital, *Rev. Col. Bras. Cir.* vol. 40 no. 6 Rio de Janeiro Nov. /Dec. 2013.

AUTHORS:

1. N. Srinivasa Rao
2. S. Zwalitha
3. K. Babji

PARTICULARS OF CONTRIBUTORS:

1. Associate Professor, Department of General Surgery, Siddhartha Medical College, Vijayawada.
2. Assistant Professor, Department of General Surgery, Siddhartha Medical College, Vijayawada.

FINANCIAL OR OTHER

COMPETING INTERESTS: None

3. Professor, Department of Surgery, Rangaraya Medical College, Kakinada.

NAME ADDRESS EMAIL ID OF THE CORRESPONDING AUTHOR:

Dr. N. Srinivasa Rao,
10-4-38, RR Pet,
Kakinada,
Andhra Pradesh, India
E-mail: nsraokkd@gmail.com

Date of Submission: 09/03/2015.
Date of Peer Review: 10/03/2015.
Date of Acceptance: 23/03/2015.
Date of Publishing: 04/04/2015.