

## THE MENACE OF PERSISTING RIGHT ILIAC FOSSA PAIN AFTER APPENDECTOMY- ARE WE OVERDOING IT?

Tanusree Chakraborty<sup>1</sup>, Snehansu Pan<sup>2</sup>

<sup>1</sup>Assistant Professor, Department of General Surgery, Shadan Institute of Medical Sciences, Hyderabad.

<sup>2</sup>Associate Professor, Department of General Surgery, Burdwan Medical College, Burdwan.

### ABSTRACT

#### BACKGROUND

Considering the huge proportion of patients presenting with persistent or recurrent right iliac fossa pain following appendectomy we studied 56 such patients presenting in the surgical outpatient department of R. G. Kar Medical College and Hospital and evaluated them for the causes using various imaging and interventional procedures.

#### MATERIALS AND METHODS

Following history and clinical examination patients were followed with urine examination, x-ray lumbar spine, ultrasound abdomen and if required CT scan abdomen. Diagnostic laparoscopy was performed where specific diagnosis could not be reached and followed with laparoscopic management.

#### RESULTS

The results showed that more than half the patients studied were females (72%). Of the 56 cases, 54 patients (96%) were in the age group 15 - 44 years. Almost half of the patients presented within the 1<sup>st</sup> year following appendectomy. The most common laparoscopic findings were adhesions (21%). Other findings include mesenteric adenitis (7%), subacute intestinal obstruction (7%), stump appendicitis (4%), hernia (7%) and gynaecological disorders (17%) in the form of pelvic inflammatory disease and endometriosis. Other diagnoses were urinary tract infection and stones and lumbar degenerative disc disease.

#### CONCLUSION

The results indicate that some pathologies leading to typical presentation might have been present from before appendectomy leaving a space for diagnostic errors. Most of the post-operative complications present early after surgery suggesting that a more meticulous evaluation of the patients initially before surgery to rule out other causes and well planned surgery may reduce the burden of such patients presenting with post appendectomy right iliac fossa pain.

#### KEYWORDS

Appendectomy, Post-operative Pain, Laparoscopy, Right Iliac Fossa Pain.

**HOW TO CITE THIS ARTICLE:** Chakraborty T, Pan S. The menace of persisting right iliac fossa pain after appendectomy- are we overdoing it? J. Evolution Med. Dent. Sci. 2017;6(21):1731-1735, DOI: 10.14260/jemds/2017/380

#### BACKGROUND

Appendicitis is one of the most common surgical problems worldwide and appendectomy is the most common abdominal operation performed as an emergency as well as an elective procedure. All the patients are not relieved of their symptoms following surgery and a very distressing problem is that a large number of patients continue to visit surgical outpatient department for continuous incapacitating pain in right iliac fossa even months to years following surgery. This presents a diagnostic challenge. Post-appendectomy complications are quite common and account for a substantial percentage of such cases. Wound infection, haemorrhage, intra-abdominal abscess formation and late complications including adhesions, intestinal obstruction, incisional hernia and very seldom stump appendicitis may occur. But a part of the subjects are diagnosed with completely different pathologies raising a question mark on the initial diagnosis and subsequent surgical management.

#### Aims and Objectives

The aims of the current study are- to detect the causes of persisting post-operative right iliac fossa pain and to identify methods of treating them.

#### MATERIALS AND METHODS

##### Study Area

Department of General Surgery, R. G. Kar Medical College and Hospital.

##### Study Population

All patients attending In-patient or Out-patient Department of General Surgery, R. G. Kar Medical College and Hospital with complaint of right iliac fossa pain following appendectomy.

##### Study Period

January 2014 to Aug 2015.  
Sample Size - 56.

##### Sample Design

##### Inclusion Criteria

- All patients presenting with persistent or recurrent right iliac fossa pain following appendectomy.
- Pain interfering with daily activities.

##### Exclusion Criteria

- Pregnant patients.

Financial or Other, Competing Interest: None.

Submission 11-01-2017, Peer Review 28-02-2017,

Acceptance 07-03-2017, Published 13-03-2017.

Corresponding Author:

Dr. Snehansu Pan,

G. T. Road, Police Line Bazar,

Burdwan-713103.

E-mail: snehansu.pan@gmail.com

DOI: 10.14260/jemds/2017/380



- Unwilling patients.
- Patients presenting with severe comorbidities, terminal illness.

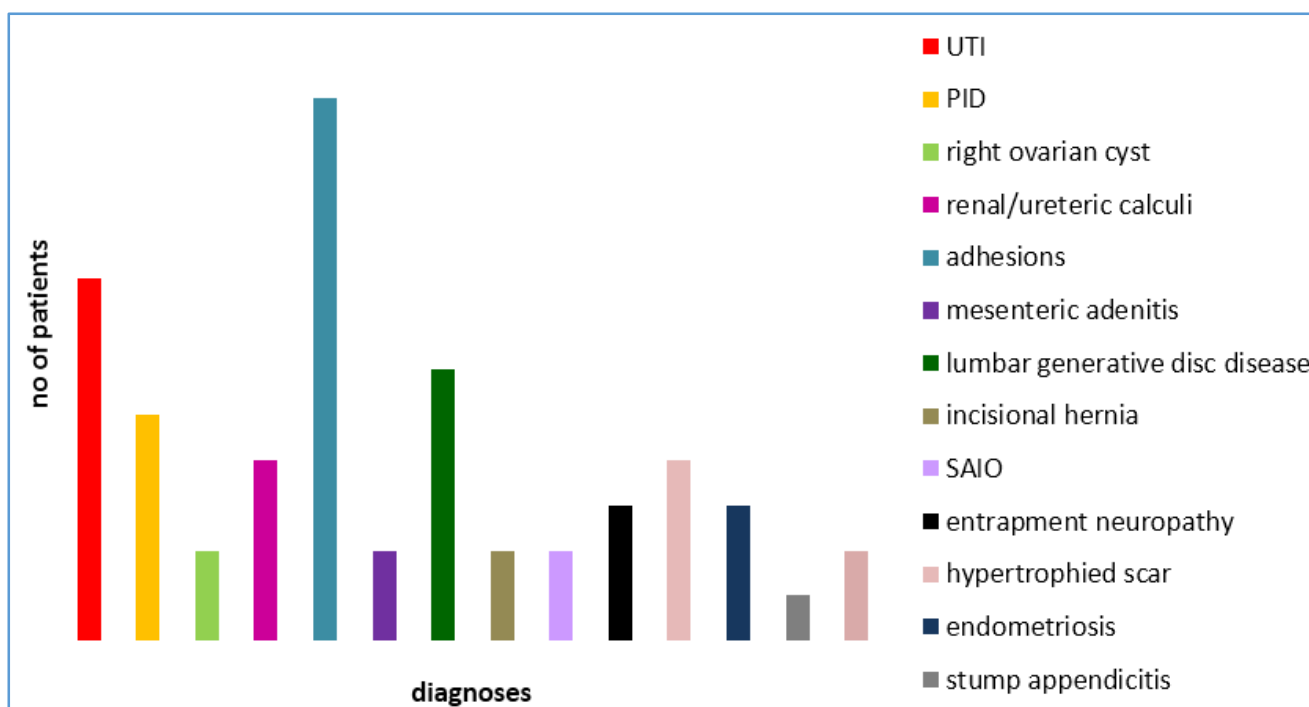
**Parameters Studied**

Age, sex, OPD tickets, discharge certificates, histopathology reports, imaging (USG, x-ray, +/- CT scan), operative intervention (diagnostic laparoscopy), blood tests, urine examination, scar (tenderness, hernia, infection, keloid), G and O evaluation.

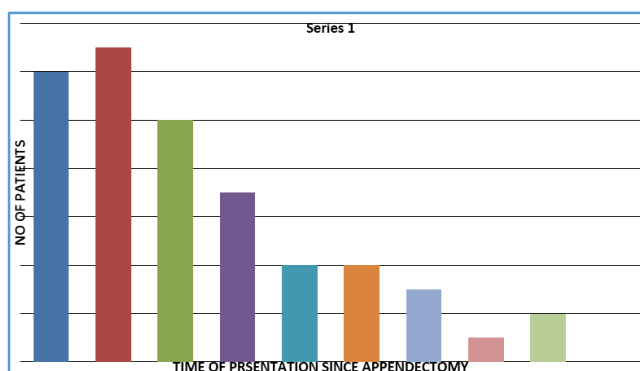
**RESULTS**

The patients included in the study belonged to the age group of 5 yrs. to 50 yrs. The mean age being 31.33 years and 54 patients (96%) were in the age group 15 - 44 years; 40 patients (71%) were females. Almost half of the patients presented within the 1<sup>st</sup> year following appendectomy. (Bar Diagram 2). Most common laparoscopic findings were adhesions (21%), other included mesenteric adenitis (7%),

subacute intestinal obstruction (7%), stump appendicitis (4%), hernia (7%), gynaecological disorders (17%) in the form of pelvic inflammatory disease and endometriosis. Laparoscopic management included adhesiolysis (33), hernia repair (2), lymph node biopsy (5), stump appendectomy (4) and diagnostic aspiration from Pouch of Douglas (2). (Photographs 1 to 4). Specific diagnoses could not be made in 2 patients and were referred for psychiatric evaluation. Among the patients in 0 to 25 years' age group adhesions were present in 2 (9%) cases, gynaecological disorders in 7 (32%) and urinary tract pathology in 5 (22.7%). (Bar Diagram 1). Out of all the patients of 25 to 45 years of age group 5 (14.7%) cases had adhesions, 6 (17.6%) cases had gynaecological disorders, 7 (20.5%) cases had urological problems; 6 (17.6%) patients in 25 to 45 years' age group had lumbar degenerative disc disease. Post-operative pain relief at 2 months and 6 months was 62.5% and 67.8% in 0 to 25 years' and 25 to 45 years' age groups respectively.



**Bar Diagram 1. Distribution of Causes of Post Appendectomy Pain in a Study of 56 Patients**



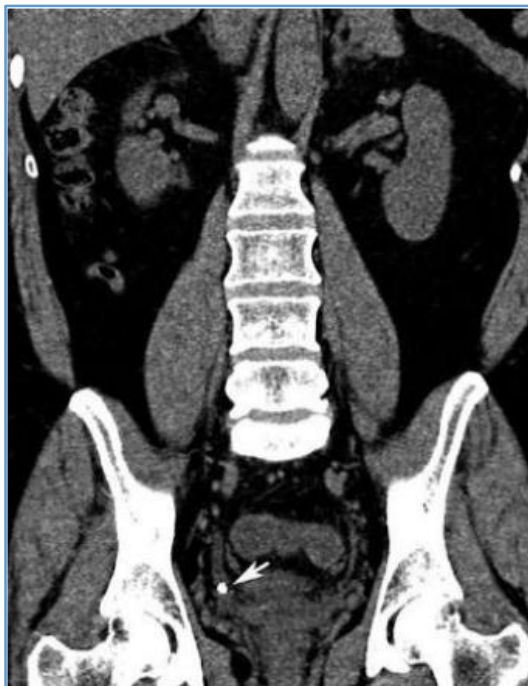**Bar Diagram 2. Distribution of Cases by 'Time of Presentation'**

Approximately, a quarter of the patients presented during the period of 6 months to 1 year following appendectomy and

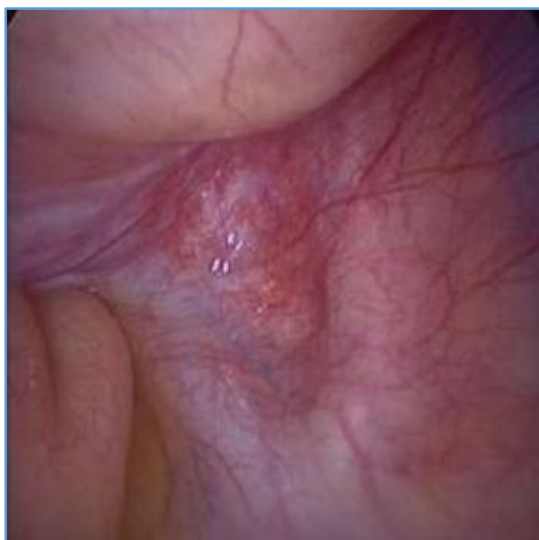almost half of the patients presented within 1 year of their surgery.

Laparoscopic Findings	No. (%)
Adhesions	12 (41%)
Stump appendicitis	1 (4%)
Hernia	2 (7%)
Mesenteric lymphadenopathy	2 (7%)
Pelvic inflammatory disease	2 (7%)
Endometriosis	3 (10%)
Subacute intestinal obstruction	2 (7%)
Right ovarian cyst	2 (7%)
No abnormality detected	5 (17%)
<b>Total</b>	<b>31 (100)</b>

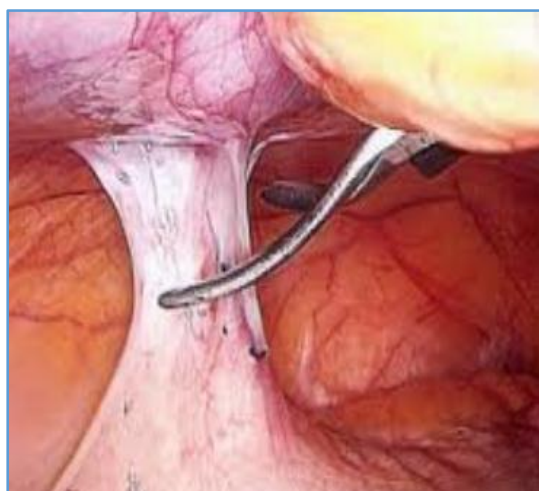
**Table 1. Diagnostic Laparoscopic Findings**



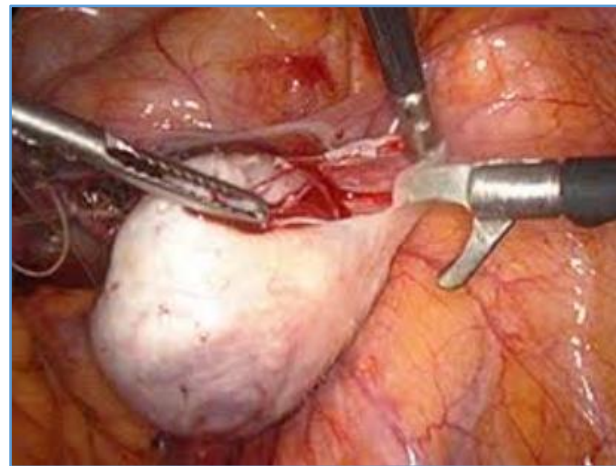
**Image 1. Right Ureteric Calculus**



**Image 2. Laparoscopic View of Mesenteric Lymphadenopathy**



**Image 3. Laparoscopic Adhesiolysis**



**Image 4. Right Ovarian Cystectomy**

#### DISCUSSION

This study was done to evaluate the causes of right iliac fossa pain following appendectomy using various diagnostic tools and also to provide a management for the causes including some therapeutic procedures in certain selected cases. It has brought out several facts, most of which are in accordance with the literature, while others differ.

The incidence of diagnostic inaccuracy observed in this study is comparable with the results of Piper et al,<sup>[1]</sup> who have also shown that the diagnostic accuracy for appendicitis is low in female patients than in males. Their study on 1018 patients showed that the diagnosis was correct in 77.7% of the males with only 58% in the females with error in diagnosis of 22.3% with males and as high as 42% in females. The main reason for this sex discrepancy, they concluded, was due to the presence of gynaecological disorders in as high as 15.5% of cases in females. Jinxing et al<sup>[2]</sup> in 1981 suggested errors in diagnosis of around 15%. Similarly, in this study 72% female patients presented with recurrent symptoms as against 28% in male patients suggesting that the diagnostic accuracy was less in females with as high as 8 (14.3%) patients with gynaecological problems in form of pelvic inflammatory disease and endometriosis.

Of the 56 cases, 54 patients (96%) were in the age group of 15 - 44 years. The preponderance of patients in this age group can be explained by the fact that this is the age group in which patients are subjected to maximum stress and strains of life and hence more prone for psychological trauma. Similar findings were also observed by Ingram et al. They stated that out of 118 young patients who were subjected to appendectomy, only 24% of them got relief of symptoms. This discrepancy was due to possibly doubtful clinical diagnostic accuracy in this age group or the association of other pathologies. The study of Piper et al<sup>[1]</sup> have also shown that diagnostic accuracy falls to 52.7% in the patients in the age group 10 to 39 years. They found out a variety of other conditions in 139 patients, which included mesenteric adenitis (63 patients), gynaecological disorders (26 patients), gastroenteritis (24 patients) and urinary tract infection or stones (12 patients), thus explaining the large number of young patients presenting with recurrent pain.

Out of total 56 patients, 49 were operated during emergency hours with diagnosis of acute appendicitis, 7 were operated as elective cases with diagnosis of chronic or recurrent appendicitis. This observation may lay emphasis on

the incomplete preoperative diagnostic work-up of the patients presenting with acute appendicitis and the low threshold for operative intervention maintained to avoid complications of missed appendicitis. The continuing symptoms even after removal of inflamed appendix can be explained by Greene J M,<sup>[3]</sup> who had shown that incomplete removal of appendix result in case of failure of the surgeon to locate true appendicocaecal junction due to abnormally situated ileocaecal fold or an inflammatory process that conceals the proximal portion of the appendix. This remaining stump may be a seat for subsequent inflammation. In his study, Greene presented three cases who presented either with stump appendicitis and/or with perforation. In our study, 1 patient was diagnosed with stump appendicitis on laparoscopy. Although accounting for a small percentage in our study, it may be the reason for a number of patients presenting with right iliac fossa pain in post appendectomy period. Goode J V<sup>[4]</sup> has raised the possibility of "Caecal pocket abscess" following the method of invagination of ligated appendiceal stump with purse string suture.

In the present study, 2 cases of incisional hernia (3.5%) were found - both of them being a case of herniation from the McBurney's incision following emergency open appendectomy. John Garlock<sup>[5]</sup> found incisional hernia in 6.4% of cases in a study of 624 cases of appendectomies with right McBurney's incision. Gue S<sup>[6]</sup> studied 51 cases of indirect inguinal hernia with previous history of appendectomies.

This may be attributable to wound infection in the post-operative period due to intraoperative appendicular abscess or perforation in the emergency scenario.

In this study, all 56 patients' ultrasound could diagnose 3 (5%) patients with pelvic inflammatory disease, 4 (7%) patients having renal/ureteric calculi and 1 patient with right ovarian cyst. This is in accordance with Piper et al,<sup>[1]</sup> who had found urinary tract infection and stones as the cause for persistent right iliac fossa pain in 12 out of 139 patients with 8.6% prevalence.

In our study 31 patients underwent diagnostic laparoscopy, out of whom 12 (41%) had intra-abdominal adhesions and underwent adhesiolysis. This was in accordance with the study in which Cuadra S A<sup>[7]</sup> suggested that post-operative intestinal adhesions are the most common clinical entity causing recurrent pain after appendectomy.

Another study conducted in Department of General Surgery, Faculty of Medicine, Suez Canal University, Ismailia, Egypt revealed adhesions to be the most common finding (63.3%).<sup>[8]</sup> In this study, laparoscopy revealed the presence of mesenteric lymphadenopathy in 2 (7%) of the 31 patients and lymph node biopsy was performed. Of these two cases, one biopsy report showed tubercular lymphadenitis and another showed non-specific reactive lymphadenitis. Mesenteric adenitis represents a benign infection or inflammation of the lymph nodes within the mesentery that results in abdominal pain, often mimicking appendicitis clinically.

One patient was diagnosed of inflammation of the appendiceal stump accounting for 8% of the total 31 patients. Various case reports have documented appendicitis of the remnant appendicular stump or stump appendicitis, if the appendix stump is left too long. In 2006, Liang et al<sup>[9]</sup>

reported 36 reported cases in the world literatures and since then there have been other single case reports in both English and non-English literature. These cases of stump appendicitis have been reported by Baek et al<sup>[10]</sup> and Mentis et al<sup>[11]</sup> following open and laparoscopic appendectomy in both children and adults. The typical presentation of stump appendicitis are similar to those of acute appendicitis; however, there is a high risk of perforation in stump appendicitis.

In our selected group of patients, laparoscopic evaluation has been associated with a positive outcome in terms of less pain or no pain; 8 out of 33 patients with adhesions (24.24%), 4 patients with stump appendicitis, 2 patients with hernia, 2 out of 5 patients with mesenteric lymphadenopathy and 1 patient with pelvic inflammatory disease had positive outcome at 2 and 6 months. Thus, out of 50 patients 17 (34%) had positive outcome.

In a study by Salky B A and Edey M B<sup>[12]</sup> with persistent abdominal pain following appendectomy on 265 patients, the aetiology was established laparoscopically in 201 cases (76%). A definitive therapeutic laparoscopic procedure was performed in 128 patients (48%). There was a normal laparoscopic examination in 64 patients (24%).

In our study positive finding was seen in 54 patients (96%), out of a total of 56 patients and procedures were performed on 48 patients (96%). In 2 patients (4%), no positive findings were detected. Out of this, majority of the cases accounting for 54% were neither due to pathologies involving the appendix nor due to any post-operative complications, but had entirely different aetiologies. This may raise a question "were these pathologies present from before the surgeries?"

From this study, it also comes into view the fact that 12 (21%) patients presented with symptoms of right iliac fossa pain within 6 months of appendectomy indicating that the pathology might have been present during their surgery. There are many conditions that mimic appendicitis. Thus, clinical diagnostic error has been reported by various authors varying from 10% to 42% even with recent advances in radiological diagnosis. Per Jess<sup>[13]</sup> in 1998 reported diagnostic accuracy in 70%.

In this study, 2 patients could not be diagnosed of any organic cause for their pain and thus were subjected to psychological evaluation. This may also be attributed to the small sample size leading to discrepancies. Joan Gomez and Peter Dally<sup>[14]</sup> evaluated 96 patients complaining of persistent abdominal pain following appendectomy, out of which in 81 patients (84%) psychological factors were considered to be primary cause of pain.

In our study, out of the 56 post appendectomy patients, positive findings were found in 96% of the patients and 70% of the patients could be relieved of their pain after our conservative management or surgical intervention. That means a significant number of patients (30%) still continue to have persistent pain abdomen in spite of this second surgical intervention.

In spite of the errors due to small number of cases studied, the results are in tune with comparable studies undertaken all over the world. To delve deeper into the cause of this menacing issue, large scale studies may be undertaken in high volume centers which will lend more insight into this problem had help surgeons all over the world take right decisions in patients presenting with right lower abdominal pain.

**CONCLUSION**

Taking into consideration, the huge burden of patients presenting with this complaint we cannot overemphasise the relevance of this study in today's scenario. The results showing a major chunk of the cases are due to pathologies other than those involving the appendix mostly presenting within 1 year of surgery. The symptom complexes of appendicitis- pain, vomiting and temperature needs meticulous preoperative evaluation especially in female patients, in the young age group and in doubtful cases before undertaking the first surgery so that the incidence of the so called 'right iliac fossa pain following appendectomy' and its associated morbidity can be brought down to the minimum.

A special note- following this study we are of the opinion that a new term- 'Post Appendectomy Syndrome' may be introduced in surgery.

**REFERENCES**

- [1] Pieper R, Kager L, Näsman P. Acute appendicitis: a clinical study of 1018 cases of emergency appendectomy. *Acta Chir Scand* 1982;148(1):51-62.
- [2] Yu J, Fulcher AS, Turner MA, et al. Helical CT evaluation of acute right lower quadrant pain: part I, common mimics of appendicitis. *AJR Am J Roentgenol* 2005;184(4):1136-42.
- [3] Green JM. Incomplete removal of appendix: its complications. *Journal of Int Col Surg* 1958;29:141.
- [4] McLeanan I, Watt JK. Justification for appendectomy in chronic appendicitis. *Br Med Journal* 1954;2(4890):736-8.
- [5] Garlock JH. Appendectomy wound repair and hernia. *Ann Surg* 1992;89(2):282-6.
- [6] Gue S. Development of right inguinal hernia following appendectomy a 10-year review of cases. *Br Med Journ* 1972;59(5):352-3.
- [7] Cuadra SA, Khalife ME, Char DJ, et al. Laparoscopic lysis of adhesions for post appendectomy pain. *Surg Endosc* 2002;16:21.
- [8] El-labban GM, Hokkam EN. The efficacy of laparoscopy in the diagnosis and management of chronic abdominal pain. *Journal of Minimal Access Surgery* 2010;6(4):95-9.
- [9] Liang MK, Lo HG, Marks JL, et al. Stump appendicitis: a comprehensive review of literature. *American Surgery* 2006;72(2):162-6.
- [10] Baek SK, Kim MS, Kim YH, et al. A case of stump appendicitis after appendectomy. *Korean J Gastroenterology* 2008;51(1):45-7.
- [11] Montes O, Zeybek N, Oysul A, et al. Stump appendicitis, rare complication after appendectomy: report of a case. *Ulus Travma Acil Cerrahi Derg* 2008;14(4):330-2.
- [12] Salky BA, Edey MB. The role of laparoscopy in the diagnosis and treatment of abdominal pain syndromes. *Surg Endosc* 1998;12(7):911-4.
- [13] Jess P, Bjerregaard B, Brynitz S, et al. Acute appendicitis. Prospective trials concerning diagnostic accuracy and complications. *Am J Surg* 1981;141(2):232-4.
- [14] Gomez J, Dally P. Psychologically mediated abdominal pain in surgical and medical outpatients clinic. *Br Med Journ* 1977;1(6074):1451-3.