

**DESCEMET'S STRIPPING ENDOTHELIAL KERATOPLASTY - A PROSPECTIVE STUDY**

Rajesh Goel<sup>1</sup>, Akshi Agarwal<sup>2</sup>, Jugal Kishor Chouhan<sup>3</sup>, Pankaj Sharma<sup>4</sup>

<sup>1</sup>Assistant Professor, Department of Ophthalmology, SMS Medical College and Hospital, Jaipur, Rajasthan.

<sup>2</sup>Assistant Professor, Department of Obstetrics and Gynaecology, SMS Medical College and Hospital, Jaipur, Rajasthan.

<sup>3</sup>Professor, Department of Ophthalmology, SMS Medical College and Hospital, Jaipur, Rajasthan.

<sup>4</sup>Professor, Department of Ophthalmology, SMS Medical College and Hospital, Jaipur, Rajasthan.

**ABSTRACT****BACKGROUND**

DSEK (Descemet's Stripping Endothelial Keratoplasty)<sup>1,2,3</sup> refers to keratoplasty in which Descemet's membrane and diseased endothelium are removed from the recipient cornea and a lenticule of posterior donor stroma and healthy endothelium is implanted.

**MATERIALS AND METHODS**

A prospective study of 24 cases who underwent Descemet's Stripping Endothelial Keratoplasty (DSEK) was conducted at SMS Medical College and Hospital, Jaipur. We had a followup period of 6 months.

**RESULTS**

Preoperative Visual Acuity: Preoperatively Visual Acuity ranged from PL + PR Accurate to HM-CF in 19 cases (79%) and 1/60 to 3/60 in 5 cases (20%).

Astigmatism - In our study 8 cases had astigmatism < 1 dioptre; 10 cases had astigmatism between 1 - 4 diopters and only 2 cases had astigmatism more than 5 diopters. Postoperatively, Best Corrected Visual Acuity (BCVA) ranged from 2/60 to 6/60 in 8 cases; 6/36 to 6/18 in 4 cases and 6/12 or better in 8 cases.

**CONCLUSION**

Thus, visual returns are comparable to that of Penetrating Keratoplasty (PK) with less complications. Although, the learning curve is a bit steep,<sup>4,5,6,7</sup> but in DSEK visual recovery is rapid, the procedure is essentially refractive - neutral. There are less chances of suture related problems and structural integrity of the eye is retained, so it has a major advantage over PK.

**KEYWORDS**

DSEK (Descemet's Stripping Endothelial Keratoplasty), Penetrating Keratoplasty (PK).

**HOW TO CITE THIS ARTICLE:** Goel R, Agarwal A, Chouhan JK, et al. Descemet's stripping endothelial keratoplasty - a prospective study. J. Evolution Med. Dent. Sci. 2016;5(104):7680-7683, DOI: 10.14260/Jemds/2016/1732

**BACKGROUND**

DSEK (Descemet's Stripping Endothelial Keratoplasty)<sup>1,2,3</sup> refers to keratoplasty in which Descemet's membrane and diseased endothelium are removed from the recipient cornea and a lenticule of posterior donor stroma and healthy endothelium is implanted.

Descemet's Stripping Endothelial Keratoplasty is one of the most recent techniques of lamellar endothelial corneal transplantation. A successful outcome depends on minimising the intraoperative trauma to the corneal endothelium utilising appropriate techniques of graft insertion and graft positioning and also on reducing the postoperative complications like graft dislocation.

**Evolution of Endothelial Keratoplasty**

Endothelial keratoplasty techniques were initially proposed over 40 years ago, but only recently have become widely adopted.

*Financial or Other, Competing Interest: None.*

*Submission 03-11-2016, Peer Review 16-12-2016,*

*Acceptance 22-12-2016, Published 29-12-2016.*

*Corresponding Author:*

*Dr. Rajesh Goel,*

*#21/278, MLA Quarters,*

*Madhyam Marg, Mansarovar,*

*Jaipur-302020, Rajasthan.*

*E-mail: dr.goyalrajesh@gmail.com*

*DOI: 10.14260/Jemds/2016/1732*



The current success of endothelial keratoplasty is largely attributable to a series of breakthroughs by Melles, who demonstrated that air could be used to press the dissected donor graft against the dissected recipient cornea, and the graft would adhere without any sutures, a technique he called posterior lamellar keratoplasty. Melles further showed that lamellar dissection of the donor and recipient corneas could be facilitated if the anterior chamber was filled with air, because air creates a light reflection that helps the surgeon to estimate the dissection depth.

The most difficult aspect of deep lamellar Endothelial Keratoplasty technique was lamellar dissection of the recipient cornea and excision of posterior recipient tissue using small curved scissors with or without the aid of trephine. Melles made yet another breakthrough when he showed that Descemet's membrane with dysfunctional endothelium could simply be stripped from recipient cornea prior to implanting the donor graft - a technique he called descemetorhexis. Price found that lightly scoring Descemet's membrane with a modified Sinsky hook along the perimeter of area to be stripped could facilitate removal of the membrane and they called the procedure Descemet's Stripping with Endothelial Keratoplasty (DSEK).

Donor detachment is the most frequent complication after DSEK, so a number of techniques have been developed to help promote graft attachment to the exquisitely smooth stromal interface exposed after Descemet's membrane removal.

Gorovoy found that DSEK could be facilitated by using a microkeratome to dissect the donor cornea and named this technique as Descemet's Stripping Automated Endothelial Keratoplasty (DSAEK). Subsequently, number of eye banks have begun to provide microkeratome dissected donor tissue to the surgeons.

Descemet's Membrane Endothelial Keratoplasty (DMEK) was presented in 2006. With this procedure only, donor Descemet's membrane and endothelium are transplanted on to the posterior corneal surface of the recipient eye. Manual stripping and dissection by means of specially designed micro instruments are employed to separate the donor Descemet's membrane together with the endothelium from the overlying stroma. The donor endothelial graft can then be preserved, rolled up in a special syringe and shipped for transplantation.

To date several technical problems have limited the popularity of DMEK among corneal surgeons, particularly waste of donor tissue when detaching Descemet from overlying stroma and difficulties manipulating the tissue during delivery and positioning.

### Instrumentation

#### Instruments for Donor Preparation

- Artificial anterior chamber.
- Dissecting blades.
- Microkeratome.
- Trephine.

#### Instruments for Recipient Preparation

- Anterior chamber maintainer.
- A 23-gauge needle to provide continuous infusion of Balanced Salt Solution.
- Cohesive viscoelastic to maintain chamber.
- Modified Sinsky hook to score Descemet's membrane.
- Trypan blue to improve visualisation of Descemet's membrane.
- Stripping instruments.
- Inspiration/Aspiration device to strip Descemet's membrane.

#### Instruments for Graft Insertion and Positioning

##### Spatula

If inserting open donor lenticule.

Single point fixation forceps - if inserting folded donor lenticule.

##### Microforceps

If pulling the donor lenticule into the eye.

Lasik flap roller.

#### Combined Procedures

Endothelial Keratoplasty can be combined with a variety of other intraocular procedures such as phacoemulsification, intraocular lens implantation or exchange, secondary lens implantation, pars plana vitrectomy or anterior vitrectomy, etc.

In particular performing cataract extraction and intraocular lens implantation prior to endothelial keratoplasty is particularly advantageous, because it helps deepen the anterior chamber and facilitates unfolding the endothelial keratoplasty donor graft.

This represents a paradigm shift from how cataract surgery is staged relative to standard penetrating keratoplasty.

Refractive outcomes are so unpredictable after penetrating keratoplasty that cataract surgery is usually postponed, so that it can be used to help correct the final refractive error; after penetrating keratoplasty sutures are removed. This is much less of a concern with endothelial keratoplasty, because it is essentially refractive neutral. Performing cataract surgery beforehand both facilitates the endothelial keratoplasty surgery and avoids subsequent surgical trauma to the graft endothelium.

#### Postoperative Care and Complications

The most frequent complication with endothelial keratoplasty is donor detachment after 1 to 7 days after surgery. If this happens, air can be reinjected into the anterior chamber to once again press the donor graft firmly against the recipient cornea. Usually, the graft reattaches without any problem. Patients should be cautioned that they should not rub their treated eyes, because eye rubbing can dislodge the donor graft in the early postoperative period.

While ocular surface complications are relatively common after standard penetrating keratoplasty, they are rarely encountered after endothelial keratoplasty procedures because endothelial keratoplasty retains corneal innervation and requires no corneal sutures.

#### Indications

DSEK (Descemet's Stripping Endothelial Keratoplasty) can be successfully performed to treat corneal pathologies affecting the corneal endothelium<sup>8,9</sup>

- Pseudophakic Bullous Keratopathy.
- Aphakic Bullous Keratopathy.
- Fuchs' Dystrophy.
- Endothelial failure of existing Penetrating Keratoplasty.
- Repeat Endothelial Keratoplasty grafting.
- Corneal oedema associated with Iridocorneal Endothelial Syndrome.
- Congenital Hereditary Endothelial Dystrophy.

#### Contraindications

- Significant anterior corneal scarring.
- Full thickness opacity.
- High irregular astigmatism.

#### Aims and Objectives

- To assess and evaluate problems encountered while switching from penetrating keratoplasty to DSEK (Descemet's Stripping Endothelial Keratoplasty).
- To assess ultimate visual outcome and complications in these patients.

#### MATERIALS AND METHODS

A prospective study of 24 cases who underwent Descemet's Stripping Endothelial Keratoplasty (DSEK) was conducted at SMS Medical College and Hospital, Jaipur.

#### We had a followup Period of 6 Months

##### Inclusion Criteria

- Pseudophakic Bullous Keratopathy.
- Aphakic Bullous Keratopathy.
- Fuchs' Dystrophy.

- Endothelial failure of existing PK (Penetrating Keratoplasty).
- Repeat Endothelial Keratoplasty grafting.
- Corneal oedema associated with Iridocorneal Endothelial Syndrome.
- Congenital Hereditary Endothelial Dystrophy.

**Exclusion Criteria**

- Significant anterior corneal scarring.
- Full thickness opacity.
- High irregular astigmatism.
- Any pre-existing posterior segment pathology.
- Any significant ocular surface abnormality (severe dry eye, limbal stem cell deficiency).

**Procedure**

A detailed history and clinical examination of the eye was done. Routine preoperative investigations were ordered and then Descemet’s Stripping Endothelial Keratoplasty (DSEK) was carried out:

Intravenous Mannitol 1 to 1.5 mg/kg of body weight was given preoperatively.

Peribulbar anaesthesia was given in cooperative patients. In uncooperative patients, general anaesthesia was given.

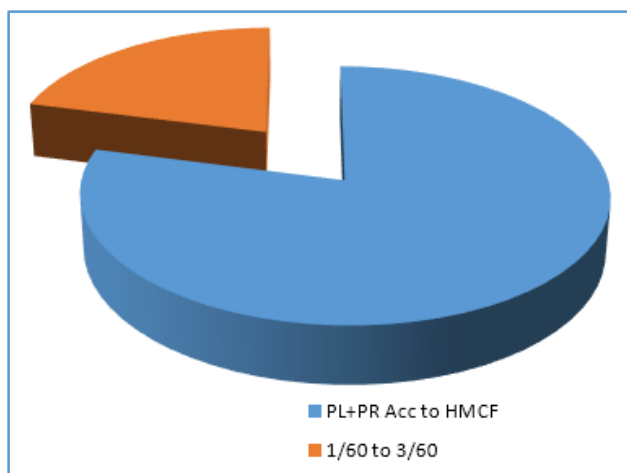
**Donor Preparation**

1. Donor graft was mounted on artificial anterior chamber.
2. (Endothelial cell count of the graft should be at least 2500 cells/mm<sup>2</sup> and should have a sclera rim of 3 mm circumferentially).
3. Using guarded knife, 450 micron thickness groove was made and then by using crescent knife straight and curved dissectors deep stroma of donor tissue was separated from Descemet’s membrane and endothelium.
4. By placing the graft on the corneal punch with endothelial side up and using Trepphine of 8 mm size; 8 mm graft containing deep stroma, Descemet’s membrane and endothelium was obtained.

After making a corneoscleral tunnel and stripping the Descemet’s membrane, donor tissue was placed inside the eye by sliding technique and air bubble was injected in the eye. Patient was kept in supine position for 24 hours.

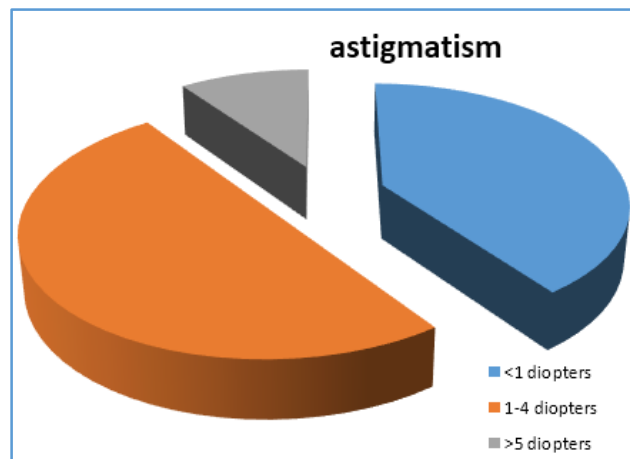
**Observations**

Preoperative Visual Acuity: Preoperatively, Visual Acuity ranged from PL + PR Accurate to HM-CF in 19 cases (79%) and 1/60 to 3/60 in 5 cases (20%).



**Astigmatism**

In our study 8 cases had astigmatism < 1 dioptre; 10 cases had astigmatism between 1 - 4 diopters and only 2 cases had astigmatism more than 5 diopters.

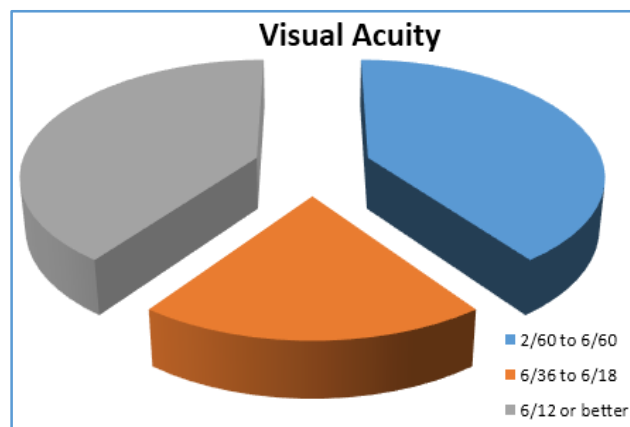


**Complications**

1 case underwent graft decentration, which was refloated and centered again.

4 cases had graft failure; they underwent penetrating keratoplasty, so they were excluded from the study.

In remaining 20 cases postoperatively Best Corrected Visual Acuity (BCVA) ranged from 2/60 to 6/60 in 8 cases; 6/36 to 6/18 in 4 cases and 6/12 or better in 8 cases.



**SUMMARY AND CONCLUSION**

Thus, visual returns are comparable to that of Penetrating Keratoplasty (PK) with less complications. Although, the learning curve is a bit steep,<sup>4,5,6,7</sup> but in DSEK visual recovery is rapid, the procedure is essentially refractive - neutral, there are less chances of suture related problems and structural integrity of the eye is retained, so it has a major advantage over PK.

**REFERENCES**

1. Price FW, Price MO. Descemet’s stripping with endothelial keratoplasty in 50 eyes: a refractive neutral corneal transplant. J Refrac Surg 2005;21(4):339-45.
2. Terry MA. Endothelial keratoplasty: history, current state & future directions. Cornea 2006;25(8):873-8.

3. Terry MA, Hoar KL, Wall J, et al. Histology of dislocations in endothelial keratoplasty: a laboratory based, surgical solution to dislocation in 100 consecutive DSEK cases. *Cornea* 2006;25(8):926-32.
4. Vajpayee RB, Agarwal T, Jhanji V, et al. Modification in descemet's stripping automated endothelial keratoplasty: "Hitch suture" technique. *Cornea* 2006;25(9):1060-2.
5. Jhanji V, Greenrod E, Sharma N, et al. Modifications in surgical techniques of descemet's stripping automated endothelial keratoplasty. *Br J Ophthalmol* 2008;92(10):1311-68.
6. Chen ES, Terry MA, Shamie N, et al. Descemet's stripping automated endothelial keratoplasty: insertion using a novel 40/60 underfold technique for preservation of donor endothelium. *Cornea* 2008;27(8):941-3.
7. Mehta JS, Por YM, Beuerman RW, et al. Glide insertion technique for donor cornea lenticule during descemet's stripping automated endothelial keratoplasty. *J Cataract Refrac Surg* 2007;33(11):1846-50.
8. Hjortdal J, Ehlers N. Descemet's stripping automated endothelial keratoplasty & penetrating keratoplasty for fuch's endothelial dystrophy. *Acta Ophth* 2009; 87(3):310-4.
9. Covert DJ, Koenig SB. Descemet's stripping automated endothelial keratoplasty in eyes with failed penetrating keratoplasty. *Cornea* 2007;26(6):692-6.