

Comprehensive Physiotherapy Rehabilitation on a Complex Case of Combination of Subcoracoid, Subacromial, Subdeltoid, and Supraspinatus Tendinitis

Mitushi Kishorao Deshmukh¹, Tejaswini Banduji Fating², Pratik Arun Phansopkar³

^{1,3}Department of Musculoskeletal Physiotherapy, Ravi Nair Physiotherapy College, Datta Meghe Institute of Medical Sciences, Wardha, Maharashtra, India. ²Department of Community and Health Physiotherapy, Ravi Nair Physiotherapy College, Datta Meghe Institute of Medical Sciences, Wardha, Maharashtra, India.

INTRODUCTION

The shoulder can be considered as one of the largest and most flexible joints in the human body. Bursa is a liquid-filled sac that can be found between tissues (bone, skin, tendons and muscle). Bursa reduces the pressure and tension between the tissues. If the bursa isn't disturbed, joints work quickly and without discomfort. So, if it becomes bloated and inflamed, patient will experience pain during physical activity.¹

Subcoracoid bursa is located between the scapula's coracoid process and the shoulder joint capsule. Subcoracoid bursitis should be seen as a potential cause of painful snapping of the anterior shoulder.² Inflammation of the sub acromial - sub deltoid bursa (SASD) has lately been indicated as a key radiological predictor indicating shoulder joint discomfort and chronic restriction in operation in both operated patients and general patients. The SASD bursa is an extra-articular synovial gap between the tendons of the rotator cuff and the under surface of the acromion, the acromioclavicular joint and the deltoid muscle, which forms the bicipital groove. Friction between the neighbouring structures or rotator cuff impingement can result in inflammation and bursitis.³ Supraspinatus tendinitis is also one factor that allows discomfort to radiate over the shoulder. Supraspinatus tendinitis progresses to tendinitis supraspinatus, specific impingement location arises in both the cycles of acromion and the bursa.⁴

Physiotherapy modalities and manual techniques are the preferred choice of management in such musculoskeletal disorders.

The shoulder can be considered as one of the largest and most flexible joints in the human body. Occurrence of shoulder discomfort in individuals is enhanced as different pathologies exist in shoulder joint systems. Shoulder bursitis is a debilitating form with shoulder joint inflammation. It is natural, treatable and found more in the young and middle-aged population. In this case, the recorded pain progression had been gradual; there was no history of fall or trauma. Pain was sharp during external rotation, abduction and flexion of the left shoulder and reported NPRS was 9 / 10 on activity. The patient was managed conservatively with PRP therapy and physiotherapy. The patient underwent 4 weeks rehabilitation and follow up for 2 weeks period in preparation for return to normal daily activities.

Corresponding Author:

Dr. Pratik Arun Phansopkar.

Department of Musculoskeletal Physiotherapy, Ravi Nair Physiotherapy College, Datta Meghe Institute of Medical Sciences, Wardha, Maharashtra, India.

E-mail: drpratik77@gmail.com

DOI: 10.14260/jemds/2020/675

How to Cite This Article:

Deshmukh MK, Fating TB, Phansopkar PA. Comprehensive physiotherapy rehabilitation on a complex case of combination of subcoracoid, subacromial, subdeltoid, and supraspinatus tendinitis. J Evolution Med Dent Sci 2020;9(41):3075-3078, DOI: 10.14260/jemds/2020/675

Submission 08-07-2020,

Peer Review 01-09-2020,

Acceptance 08-09-2020,

Published 12-10-2020.

Copyright © 2020 Mitushi Kishorao Deshmukh et al. This is an open access article distributed under Creative Commons Attribution License [Attribution 4.0 International (CC BY 4.0)]

PRESENTATION OF CASE

A 50-year-old male ward boy in hospital, right hand dominance, complained about difficulties in activity of daily livings (ADL's) and occupational jobs due to pain in left shoulder joint since one month. He was unable to lift heavy loads, push or pull heavy objects and all overhead activities were restricted due to pain.

There was a gradual increase in pain day by day; but because of low economic condition and family burden he was trying to ignore it. But the pain was unbearable during any heavy tasks. So, he went to the hospital and further investigation was done in which X-ray, MRI and USG report reveals minimal subcoracoid bursitis with subacromial and subdeltoid bursitis along with supraspinatus tendinitis (Figure 1). Orthopaedic consultant suggested PRP therapy but there was no improvement. So, patient came for physiotherapy. PRP therapy was started on 18th March 2020 and physiotherapy was continued till 1st May 2020.

Patient came to the physiotherapy OPD with chief complaints of pain and swelling over left shoulder. Pain was dull aching type over anterior region of left shoulder joint and radiating to upper arm, which was aggravated during activity, with difficulty in overhead activities, unable to pull or push or carry out any heavy loads. Discomfort was present during occupational tasks and ADL's.

ROM	Left		Right
Shoulder Joint	Active	Passive	
Flexion	0 - 30°	0 - 35°	Normal
Extension	0 - 15°	0 - 20°	Normal
Abduction	0 - 30°	0 - 35°	Normal
Adduction	30 - 0°	35 - 0°	Normal
External rotation	0 - 10°	0 - 15°	Normal
Internal rotation	0 - 20°	0 - 25°	Normal

Table 1. Range of Motion

Muscles of Shoulder	Left	Right
	Shoulder Joint	
Flexors	Grade 3	Normal
Extensors	Grade 3	Normal
Abductors	Grade 3	Normal
Adductors	Grade 4	Normal
External Rotator	Grade 3	Normal
Internal Rotator	Grade 3	Normal
Scapular Protractor	Grade 4	Normal
Scapular Retractors	Grade 3	Normal
Scapular Elevator	Grade 3	Normal
Scapular Depressor	Grade 4	Normal

Table 2. Manual Muscle Testing in Available Range

On observation, patient came with a rounded shoulder, left upper arm is adducted, slightly internally rotated and shrugging of shoulder joint was present. On inspection, sulcus sign was present on left side. On palpation of joint, grade 3 tenderness was present over anterior region of left shoulder joint, on movement, firm end feel was present (Figure 2).

On assessment of left shoulder joint, Dugas test was positive. Patient was unable to place the hand on the opposite shoulder joint and difficulty to attempt lower elbow to the chest (Table 1). Empty can test was positive, patient complained of pain to bring the arm 30 degree forward and internally rotate. Neer's impingement and Hawkins- Kennedy test was positive; pain and discomfort were present. Painful arch syndrome was positive on left shoulder joint (Table 2).

Assessment of pain and functions of shoulder joint was measured by (SPADS) shoulder pain and disability scale. On shoulder pain and disability scale (SPADS) pain score was 86 % and disability score was 75 % before the treatment.



Figure 2.
Pre-Treatment
Photograph of Patient

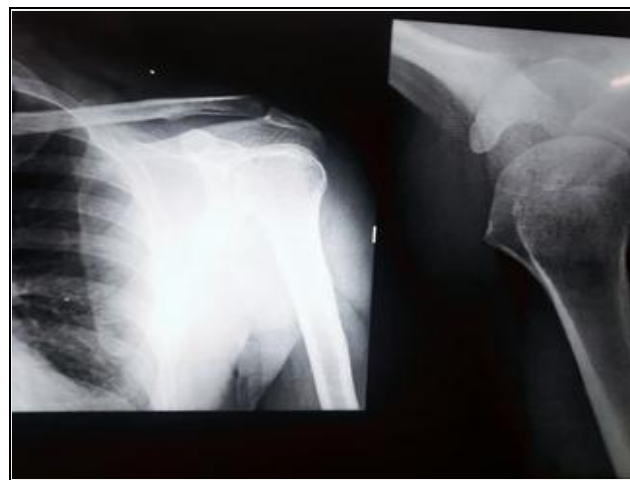


Figure 1. Radiograph of the Shoulder Joint

PHYSIOTHERAPY INTERVENTION

1st - 3rd Day

Initial treatment included interferential therapy (IFT) for 15 - 20 min. Cryotherapy was given prior and after the treatment for 7 min. US was given for 10 mins.

4th - 7th Day

IFT, US was continued with cryotherapy pack for 7 minutes. Isometric rhythmic stabilization exercises to left shoulder joint in each plane. Grade 1 Kaltenborn mobilisation, 3 sets of 10 - 15 repetitions as per patient's tolerance started.

2nd Week

In the second week, range of motion improved but pain was still there; so, physiotherapy was continued with IFT and US and hot fermentation. Rhythmic stabilization exercise and active range of motion exercise with capsular stretch was given. Grade 1 Kaltenborn mobilization technique, 3 sets of 15 repetitions to reduce the pain and increase range of motion. Tender point therapy over the hypertonic and tender muscle point were started (trapezius). Shoulder pulley was started in available range with shoulder retracted. Home exercise planning was given which includes wand exercise and pendular exercise, 10 repetitions in each plane.

3rd Week

Hydrocollator pack and active ROM exercises was continued; Active assisted stretching for the surrounding muscles of the left shoulder joint was taught to the patient. With including the Finger Ladder and wand range of motion exercise, wall push-ups home program exercises were planned.

4th Week

From the end of the third week, strengthening exercises was started. Initially by including the half Kg weight cuff during active range of motion exercises in all plane for shoulder. Along with these multi-angle isometric exercise and scapular strengthening exercise was given in corrected position of shoulder.

rotator cuff muscles of left shoulder. All active range of motion exercises with good ergonomics advised in daily activities.

Post treatment, patient was able to raise his hand. Patient was able to do ADL's without discomfort; improvement was seen on SPAD (Shoulder Pain and Disability Scale) post treatment the score was very good. On SPADS pain score was 36 % and disability score was 24 % after the treatment. (Table 3, Table 4) (Figure 3). Range of motion and strength was increased after the treatment.

ROM	Left	Right
Shoulder Joint	Active	Passive
Flexion	0 - 100	0 - 110
Extension	0 - 20	0 - 25 ^o
Abduction	0 - 90 ^o	0 - 100 ^o
Adduction	30 - 0 ^o	35 - 0 ^o
External Rotation	0 - 40 ^o	0 - 50 ^o
Internal Rotation	0 - 70 ^o	0 - 70 ^o

Table 3. Post-Treatment Range of Motion

Muscles of Shoulder	Left	Right
	Shoulder Joint	
Flexors	Grade 5	Normal
Extensors	Grade 5	Normal
Abductors	Grade 5	Normal
Adductors	Grade 5	Normal
External Rotator	Grade 5	Normal
Internal Rotator	Grade 5	Normal
Scapular Protractor	Grade 5	Normal
Scapular Retractors	Grade 5	Normal
Scapular Elevator	Grade 5	Normal
Scapular Depressor	Grade 5	Normal

Table 4. Post-Treatment Manual Muscle Testing

DISCUSSION

Shoulder is the location of several distressing symptoms. Correct diagnosis relies on a comprehensive medical background and on an extremely detailed physical test. Fortunately, most shoulder disorders respond to, or can resolve spontaneously. Consequently, physical therapists probably will continue to play an integral role in treating patients with shoulder pain.⁵

Ferdinando Draghi¹, et al conducted an analysis that involves a sequence of sequential shoulder joint movements. Both test results conducted for shoulder discomfort have been checked. The involvement of subacromial-subdeltoid (SASD) bursa inflammation was recently suggested as a key radiological predictor indicating chronic weakness and discomfort in both controlled and general population patients.⁶ Effusion in the SASD bursa is frequently correlated with shoulder discomfort, sometimes independently of the underlying pathology.

Physiotherapy was more often used after surgery than as part of initial non-surgical treatment, where less than half of the patients received physiotherapy. Use of physiotherapy was less common among men than among women, whereas, unequal use of physiotherapy in relation to education level was not noticeable. Overall, the use of physiotherapy with exercises in initial non-surgical treatment was relatively limited.⁸

Khurana N, et al reported that the initial objectives of the rehabilitation program were to reduce pain through the use of modalities; and to restore the range of motion, first passively and progressing to full AROM. No findings that recommend best practice for physical therapy interventions have been

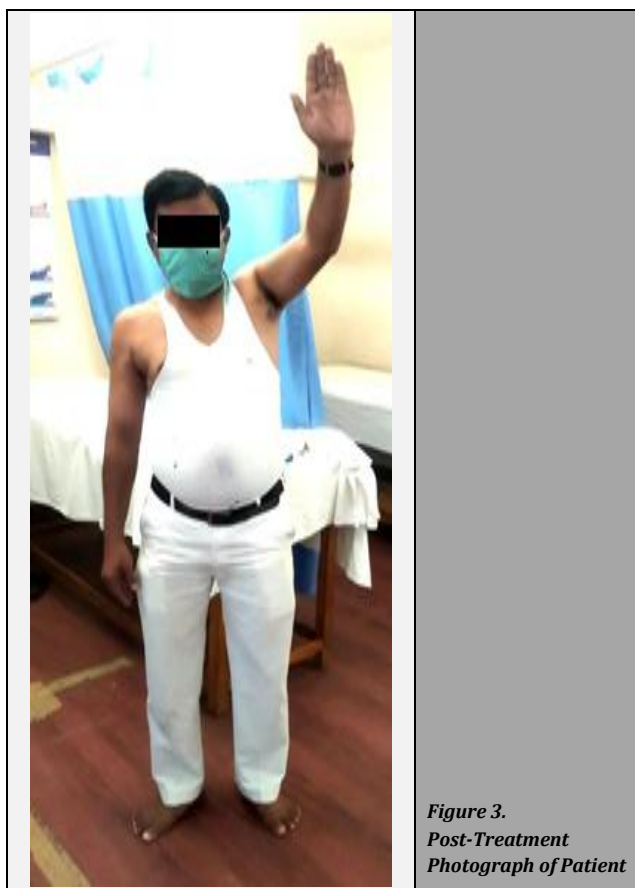

Figure 3.
Post-Treatment Photograph of Patient

Follow Up Phase

Above mentioned exercises were taught to the patient with 1 Kg dumbbells. Advised TheraBand strengthening exercises for

established. Other medical methods used to manage a person with rotator cuff lesion include physical treatment, electrical modalities, constructive movements and numerous simple and specialized procedures for joint mobilization.⁵ Ryans, et al included hot pack, light shoulder mobilization exercises that were prescribed to patient for pain reduction. Davies & Durall, et al stated that the rotator cuff resistance training was initiated once sufficient range of motion had been achieved.⁷ The rotator cuff both centralizes and approximates the humeral head within the glenoid. Myers et al reported that this glenohumeral-scapulothoracic coordination and synchronized shoulder movement is interrupted by erratic scapulohumeral motion by the scapular stabilisers. With this humeral head orientation broken, there is a likelihood of the higher tuberosity impinging on subacromial structures.⁹

Post-pain reduction the workout routine involved strengthening of the rotator cuff, as well as a scapular recovery system. The scapular stabilisers perform a crucial function in the reconstruction of the rotator cuff. Movements of the scapulothoracic articulation are essential for fluent, coordinated shoulder movement post-pain reduction the workout routine involved strengthening of the rotator cuff, as well as a scapular recovery system. The scapular stabilisers perform a crucial function in the reconstruction of the rotator cuff. Movements of the scapulothoracic articulation are essential for fluent, coordinated shoulder movement.¹⁰

CONCLUSIONS

Subcoracoid combing with subacromial and subdeltoid bursitis and supraspinatus tendinitis is a very rare condition. We didn't find proper physiotherapy protocol for the same. In this case report we found bad posture (rounded shoulder) which further aggravated the condition. We tried to reduce bursitis pain by ultrasound and IFT for 3 weeks; 4th week onwards, we gradually started strengthening exercise for shoulder and scapula in correct shoulder posture to strengthen weak muscle. This protocol helps to reduce shoulder pain, improve strength and ROM.

During the intervention period the patient showed great cooperation and now the subject can maintain the range of motion at shoulder joint and is able to perform activities of daily living and is back to his occupation.

List of Abbreviations

1. SASD – Sub-Acromial-Sub-Deltoid (bursa)
2. ADL - Activity of Daily Living
3. MRI - Magnetic Resonance Imaging
4. USG - Ultrasonography
5. PRP - Platelet-Rich Plasma Therapy

Appropriate consent forms were obtained from the patient.

Financial or Other Competing Interests: None.

REFERENCES

- [1] Singh VP, Khandelwal B, Sherpa NT. A difficult case of subacromial bursitis in diabetes treated by steroid injection and physiotherapy combined with yoga. *Indian J Pain* 2013;27(2):98-102.
- [2] Charłusz M, Gasztych J, Irzmański R, et al. Comparative analysis of analgesic efficacy of selected physiotherapy methods in low back pain patients. *Ortop Traumatol Rehabil* 2010;12(3):225-36.
- [3] Faruqi T, Rizvi TJ. Subacromial Bursitis. In: *Stat Pearls Treasure Island (FL): Stat Pearls Publishing* 2020. <http://www.ncbi.nlm.nih.gov/books/NBK541096/>
- [4] Ryans I, Montgomery A, Galway R, et al. A randomized controlled trial of intra-articular triamcinolone and/or physiotherapy in shoulder capsulitis. *Rheumatology (Oxford)* 2005;44(4):529-35.
- [5] Khurana N, Hanspal SS, Singh G. Rotator cuff lesions: a case report. *J Exerc Sci Physiother* 2011;7(1):56-63.
- [6] Ginn KA, Herbert RD, Khouw W, et al. A randomized, controlled clinical trial of a treatment for shoulder pain. *Phys Ther* 1997;77(8):802-9.
- [7] Lombardi I, Magri ÁG, Fleury AM, et al. Progressive resistance training in patients with shoulder impingement syndrome: a randomized controlled trial. *Arthritis Rheum* 2008;59(5):615-22.
- [8] Lazaro R. Shoulder impingement syndromes: implications on physical therapy examination and intervention. *J Jpn Phys Ther Assoc* 2005;8(1):1-7.
- [9] Davies GJ, Durall C. Typical rotator cuff impingement syndrome-1- typical rotator cuff impingement syndrome: it ' s not always typical. *Semantic Scholar* 2000.
- [10] Christiansen DH, Frost P, Frich LH, et al. The use of physiotherapy among patients with subacromial impingement syndrome: impact of sex, socio-demographic and clinical factors. *PLoS One* 2016;11(3):e0151077.