

## IMAGING OF HIP JOINT PATHOLOGIES

Parul Dutta<sup>1</sup>, Trailakya N. Sonowal<sup>2</sup>, Santosh Limbaji Shahare<sup>3</sup>, Karan Asthana<sup>4</sup>

<sup>1</sup>Professor, Department of Radiology, Gauhati Medical College and Hospital, Guwahati.

<sup>2</sup>Assistant Professor, Department of Radiology, Gauhati Medical College and Hospital, Guwahati.

<sup>3</sup>Post Graduate Student, Department of Radiology, Gauhati Medical College and Hospital, Guwahati.

<sup>4</sup>Post Graduate Student, Department of Radiology, Gauhati Medical College and Hospital, Guwahati.

### ABSTRACT

The hip joint is a large and complex articulation and can be involved by numerous pathologic conditions like congenital and developmental, infective, arthritic, and neoplastic. Early diagnosis and characterisation of pathology has vital role in proper management and follow up of the disease for the clinicians. Present study was conducted in 45 patients who underwent clinical, radiological, and pathological examination in GMCH. Maximum no of patient between age group of 10-30 yrs. male-female ratio was 1.8:1 and 30% cases are unilateral. FSE STAIR images were most useful in delineating pathologies. Gadolinium-enhanced scan were used to evaluate the extent of the disease and the pattern of involvement. AVN was the most common pathology detected comprising 29%. The next common abnormality detected was infective arthritis found in 26% of cases. In case of Legg-Calve-Perthes disease, there was abnormal linear increase in the signal intensity at junction of the epiphyseal cartilage. Ultrasonography is useful for the screening of paediatric hip cases and also for guided aspiration for histopathology. CT scan shows better resolution of soft tissue than the radiograph. The importance of early diagnosis can be gauged from the fact that early initiation of treatment creates the difference between a responsible, worthwhile life, and a cripple handicapped life. The role of imaging can never be undermined considering the fact that early suspicion and detection is within the realms of imaging.

### KEYWORD

AIIS-Anterior inferior iliac spine, AVN-Avascular necrosis, BM-Bone marrow, BMOS-Bone marrow oedema syndrome, Ca-Carcinoma, DDH-Developmental dysplasia of hip, FSE-First spin echo, Gd-Gadolinium, MRI-Magnetic resonance imaging, ON-Osteonecrosis, PVNS-Pigmented villonodular synovitis, SPECT-Single positron CT, STIR-Short T inversion, T-Tesla, T1 relaxation time, T1W-T1 weighted, T2-Spin echo, TC-Technetium, TE-Time of echo, T I-Time of inversion.

**HOW TO CITE THIS ARTICLE:** Dutta P, Sonowal TN, Shahare SL, et al. Imaging of Hip joint pathologies. J. Evolution Med. Dent. Sci. 2016;5(63):4430-4436, DOI: 10.14260/jemds/2016/1012

### INTRODUCTION

The hip joint is a large and complex articulation and can be involved by numerous pathologic conditions like congenital and developmental, infective, arthritic, and neoplastic. Early diagnosis and characterisation of pathology has vital role in proper management and followup of the disease for the clinicians.<sup>1</sup>

There are many modalities for the evaluation of hip pathologies such as ultrasound, bone scintigraphy, conventional radiography, conventional arthrography, CT scan, and MR imaging. Radiographs remain the initial imaging technique, which have great role in screening of hip joint pathologies.<sup>2</sup>

However, in most instances, they detect the pathologies late only when the bony changes are obvious. Also, the soft tissue extent of the lesion cannot be ascertained. At times, they are inconclusive or do not explain the patients' complaints.

Radionuclide imaging of painful hip, although sensitive is not specific for increased uptake of the isotope and hence the exact nature and extent of the pathology cannot be judged.

Ultrasonography have important role in screening and diagnosis of paediatric hip diseases as developmental

dysplasia of hip. USG is increasing used mainly to detect intra-articular joint fluid and to evaluate para-articular masses and tendon disorders.<sup>3</sup>

CT scan can demonstrate bony pathology well, but not as early as MRI. As far as the soft tissues are concerned, the contrast resolution of MRI is unsurpassed. CT scan also has the disadvantage of radiation; however, it can show bony over growth or calcified lesions very well.

MRI is often the problem solving technique bypassing bone scintigraphy and CT scanning. The appearance of the hip on MRI varies depending on the type of sequence and the skeletal maturity of the patient.

### AIMS AND OBJECTIVES

1. To study the different appearances of hip joint pathologies using x-rays, USG, CT scan, and MRI.
2. To establish a statistical categorisation of cases in terms of age, sex, and the imaging findings.

### MATERIAL AND METHODS

The institutional ethical committee approved the study and all patients provided informed written consent. The present study included 45 patients who presented with pain in one or both the hips. They underwent radiographic, sonographic, MR evaluation, or CT scan of both the hips in the Department of Radiodiagnosis in Gauhati Medical College and Hospital from July 2010 to November 2011.

### Selection of Patients

The bulk of patients in the present study were referred from various clinical departments mainly the Department of Orthopaedics with pain or swelling in one or both the hips.

Financial or Other, Competing Interest: None.

Submission 29-01-2016, Peer Review 21-07-2016,

Acceptance 28-07-2016, Published 06-08-2016.

Corresponding Author:

Dr. Parul Dutta,

Ashirwad House No. 16,

Bonkanwar Tila, Kharguli,

Guwahati-781004,

Assam.

E-mail: parul.dutta@rediffmail.com

DOI: 10.14260/jemds/2016/1012

**Instrumentation**

Plain radiographs were done on Siemens 800 mAs machine. USG is done using Siemens Antares machine. The machine for CT scan used is Somatom dual slice CT (Siemens). Before the scans were performed, the procedure was explained to the patient so as to allay any apprehensions. An informed consent was there after taken from the patient as well as the attendant.

**Position**

Most patients were scanned in the supine position with arms out of the field. Patients who had difficulty lying supine were scanned in the prone position. First, a topogram of the region of interest is taken and the CT scan protocol is planned on it in the console room.

We took serial axial 2 or 3 mm thick slices in the region of interest and 1 or 2 mm axial slices at the level from bilateral iliac crests to lesser trochanter. Extra-spiral sections of the area of interest as identified in the earlier scans were taken using 10 mm slice thickness and 15 mm table feed for reformatting purposes. Coronal, sagittal, and parasagittal reformats were studied using Surface Shaded Display (SSD) and Multiplanar Reconstruction (MPR) techniques.

**RESULTS AND OBSERVATIONS**

Title	Total	Male		Female	
		Number	Percentage	Number	Percentage
Total Cases	45	29	65%	16	35%

**Table 1: Distribution of Pathologies - the Studies Population**

**Sex Distribution**

Out of the patients that were included in the study, 29 are males (65%) and 16 were females (35%).

Age Group	Total Cases	Percentage
<10 years	5	11
11-20 years	12	27
21-30 years	15	33
31-40 years	5	11
41-50 years	4	9
51-60 years	2	4.5
61-71 years	2	4.5

**Table 2: Age Group Distribution of the Studied Population**

**Graphic Representation of Total Pathologies Detected in Each Age Group**

The majority of the patients were in the age group 11-30 years (50%). 5 patients (11%) were below 10 years of age while same number of patients (11%) were above between 31-40 years age group. 18% patients were above 40 years of age.

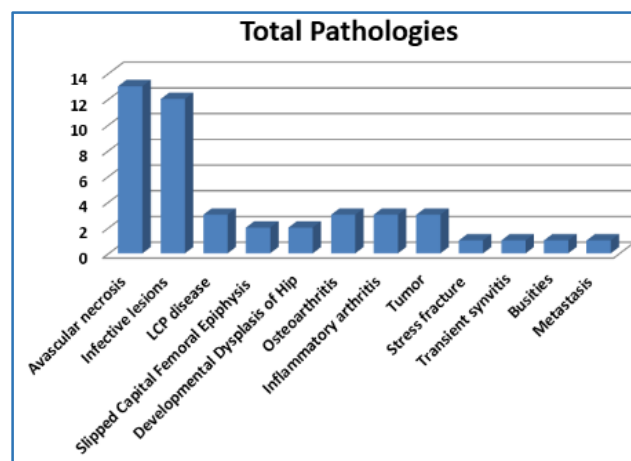
Title	Total Cases	Percentage
Benign	43	95.5
Malignant	2	4.5

**Table 3: Showing Pathologies Benign vs. Malignant**

In 43 patients (95.5%), the patient's pathology was benign while one patient had femoral metadiaphyseal sarcoma and one metastatic disease from carcinoma lung.

Pathology	No. of Cases	Percentage
Avascular Necrosis	13	29
Infective Lesions	12	26.4
LCP Disease	3	0.67
Slipped Capital Femoral Epiphysis	2	0.45
Developmental Dysplasias of Hip	2	0.45
Osteoarthritis	3	0.67
Inflammatory Arthritis	3	0.67
Tumour	3	0.67
Stress Fracture	1	0.22
Transient Synovitis	1	0.22
Bursitis	1	0.22
Metastasis	1	0.22

**Table 4: Showing Various Pathologies Detected and Their Percents in the Studied Population**



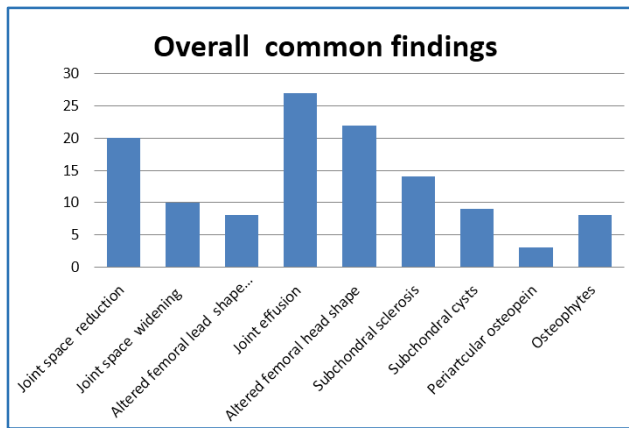
The majority of the cases were that of avascular necrosis (13 in number i.e. 29% followed by infective lesions (12. i.e. 26.4%). There were 3 cases (0.67% each) of LCP, osteoarthritis, inflammatory arthritis, and tumour respectively. There were 2 cases (0.45% each) of SCFE and DDH respectively. Other pathologies as stress fracture, pathological fracture, transient synovitis, and bursitis were single in number.

Title	Total Cases	Percentage
Unilateral	30	66.6
Bilateral	15	33.3

**Table 5: Pathologies Detected-Unilateral vs. Bilateral**

Changes	Cases	Percentage
Joint Space Reduction	20	44%
Joint Space Widening	10	22%
Altered Femoral Lead Shape Erosion	8	18%
Joint Effusion	27	60%
Altered femoral Head Shape	22	49%
Subchondral Sclerosis	14	31%
Subchondral cysts	9	20%
Periarticular Osteopenia	3	7%
Osteophytes	8	18%

**Table 6: Classified Changes in Total Pathologies**

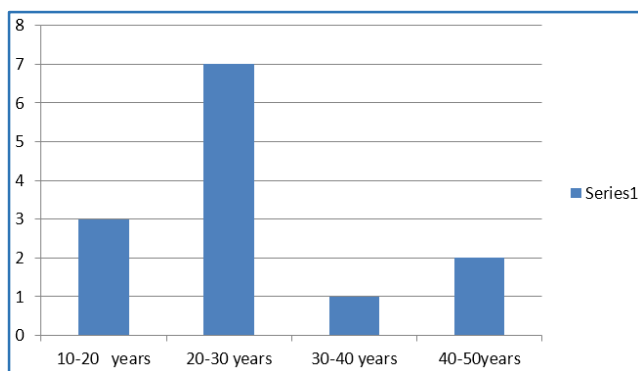


Total Pathologies	AVN	Percentage
45	13	29%

**Table 7: Comparison Between Total Pathologies and AVN**

Age Group	Total Cases	Percentage
10-20 years	3	23
20-30 years	7	53
30-40 years	1	8
40-50 years	2	16

**Table 8: Distribution of AVN Various Age Group**



The most common pathology detected in our study was avascular necrosis. It comprised 13 of the 45 cases (29%). The majority of the patients of AVN were in the age group of 20-30 years (53%).

Title	Total Cases	Percentage
Male	7	54
Female	6	46

**Table 9: AVN Detected-Male vs. Female**

Title	Total Cases	Percentage
Unilateral	5	39
Bilateral	8	61

**Table 10: AVN Detected - Unilateral vs. Bilateral**

AVN was bilateral in 8 (61%) out of the 13 patients and unilateral in 5 (39%) patients. 7 (54%) with AVN were males while 6 (46%) were females.

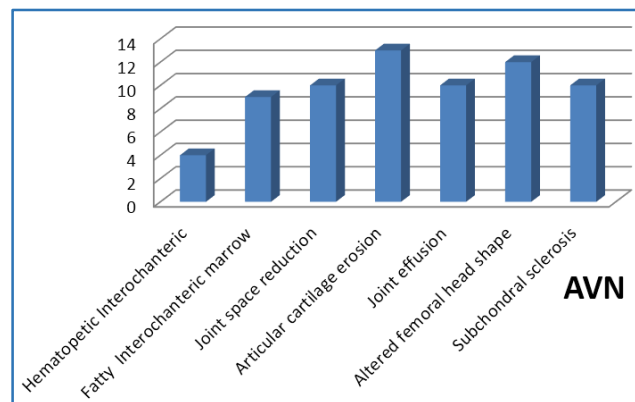
Title	Total Cases	Percentage
Steroids	4	30
Idiopathic	5	39
Alcohol	2	15
Trauma	1	8
Sickle Cell Disease	1	8

**Table 11: Showing Teleological Factors Associated With AVN**

AVN was idiopathic in 5 (39%) cases. It was associated with steroids and alcohol use in 4 (30%) and 2 (16%) patients respectively. One patients (8%) had trauma and another was a known cases of sickle cell disease. Of the 13 patients, less than 50 years of age with avascular necrosis, only 4 patients (30%) M in the present study predominantly haematopoietic intertrochanteric marrow.

Findings	No. of Cases	Percentage
Haematopoietic Intertrochanteric	4	30%
Fatty Intertrochanteric Marrow	9	7%
Joint Space Reduction	10	77%
Articular Cartilage Erosion	13	100%
Joint Effusion	10	77%
Altered Femoral Head Shape	12	92%
Subchondral Sclerosis	10	77%

**Table 12: AVN Findings**



Pattern	No. of Cases	Percentage
Focal Areas of Poorly-Enhancing Tissues Surrounded a Bright Enhancing Rim	6	50%
Diffuse Enhancement of Femoral Head and Neck	1	8%
Combination of the above two Patterns	4	33%
Altered Femoral Head Shape	12	92%
Subchondral Sclerosis	10	77%

**Table 13: Patterns of Contrast Enhancement Cases of AVN**

Changes	Cases	Percentage
Joint Space Reduction	5	42%
Joint Space Widening	4	33%
Articular Cartilage Erosion	13	58%
Joint Effusion	10	83%
Marrow Oedema	10	83%
Soft Tissue Changes	12	100%
Synovial Enhancement	11	92%

**Table 14: Changes In Infective Pathologies**

Patterns of Contrast	No. of Cases	Percentage
Rim Enhancement	11	92%
Uniform Enhancement	1	8%

**Table 15: Patterns of Contrast Enhancement in Bones Cases of Infective Lesions**

MRI Findings	Tuberculosis	Pyogenic
Thin and Smooth	8 (89%)	0 (0)
Thick and Irregular	1 (11%)	3 (100%)

**Table 16: Abscess Wall**

Finding	Cases	Percentage
Cartilage Irregularity and Femoral Head Fragmentation	3	100%
Metaphysical Irregularity	3	100%
Marrow Oedema	2	67%
Joint Effusion and Widening	2	67%
Joint Effusion and Widening	3	100%

**Table 17: Perthes Disease**

In cases of Perthes disease, femoral head fragmentation, metaphysical irregularity, and joint effusion was seen in all cases out of three.

Finding	Cases	Percentage
Slipped Femoral Head	2	100%
Widening of Epiphysis	2	100%
Bilateral	1	50%
Marrow Oedema	1	50%

**Table 18: Slipped Capital Femoral Epiphysis (SCFE)**

Two cases of SCFRE were studied both showing slipped femoral head widening of epiphysis with bilateral involvement in one case.

Finding	Cases	Percentage
Slipped Head	2	100%
Joint Space Widening	2	100%
Dislocated Head	1	50%

**Table 19: Developmental Dysplasia of Hip**

Small-sized femoral head and joint space widening seen in both cases of DDH while one showed dislocation of head.

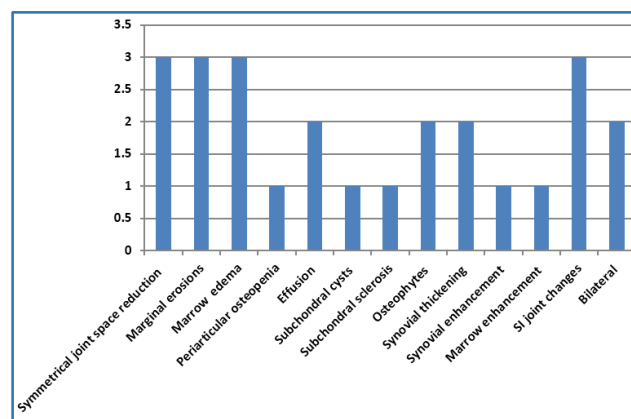
Finding	Cases	Percentage
Superolateral Joint Space Narrowing	3	100%
Articular Erosion	2	67%
Subchondral Cyst	2	67%
Osteophytes	3	100%

**Table 20: Osteoarthritis**

There were three cases of osteoarthritis showing superolateral space narrowing and osteophytes in all three (100%), articular erosion in 2 (67%), and subchondral cysts in 2 cases (67%).

Findings	Cases	Percentage
Symmetrical Joint Space Reduction	3	100%
Marginal Erosions	3	100%
Marrow Oedema	3	50%
Periarticular Osteopenia	1	33%
Effusion	2	67%
Subchondral Cysts	1	33%
Subchondral Sclerosis	1	33%
Osteophytes	2	67%
Synovial Thickening	2	67%
Synovial Enhancement	1	33%
Marrow Enhancement	1	33%
SI Joint Changes	3	100%
Bilateral	2	67%

**Table 21: Inflammatory Arthritis**



In three cases of inflammatory arthritis with evidence of bilateral SI joint changes, symmetrical joint space reduction, marginal erosions, and marrow oedema was observed in 100% cases. Joint effusion, osteophytes, and synovial thickening was seen in 2 cases (67%). Three tumour cases were observed two of which were aneurysmal bone cyst involving femoral neck. Other cases as stress fracture of femoral neck, transient synovitis, greater trochanteric bursitis and metastatic deposit involving femoral neck were seen each single in number.

**DISCUSSION**

With the lack of specificity in clinical examination and the imprecise result of conventional radiography and computed tomography, Magnetic Resonance Imaging (MRI) emerged as modality of choice in early diagnosis.

The hip joint is a large and complex articulation and can be involved by numerous pathologic conditions. There are many modalities for the evaluation of hip pathologies such as ultrasound, bone scintigraphy, conventional radiography, conventional arthrography, CT scan, and MR imaging.

Although, radiographs remain the initial imaging technique in most instances. They detect the pathologies late only when the bony changes are obvious. The soft tissue extent of the lesion cannot be ascertained. Radionuclide imaging of

painful hip, although sensitive, is not specific for increased uptake of the isotope and hence the exact nature and extent of the pathology cannot be judged.

CT scan can demonstrate bony pathology, can show bony overgrowth, or calcified lesions very well. The soft tissue resolution is better than the radiographs and involvement of surrounding structures can be commented. As far as, the soft tissues are concerned, the contrast resolution of MRI is unsurpassed. MRI is often the problem solving technique bypassing CT scanning. The appearance of the hip on MRI varies depending on the type of sequence and the skeletal maturity of the patient.

In our study, both the bony and soft tissue structures about the hip joint were clearly visualised on T1W images while the pathologies were well demarcated on FSE STIR images. FSE STIR proved to be the most useful sequence being able to detect presence or absence of abnormality in 100% of the cases. This is similar to what Khoury NJ et al<sup>4</sup> observed who assessed the role of a limited MR protocol (Coronal STIR) as the initial part of the MR examination in patients with hip pain and concluded that a normal coronal STIR study of the hips in patients with hip pain and normal radiographs precludes the need for further pelvic MR sequences. Any abnormality detected on this limited protocol should be further assessed by additional MR sequences.

In our study, out of all pathologies detected, which 65% were males and 35% were females. The most common abnormality detected in our study was avascular necrosis of the femoral head.

In the present study, there were 13 cases of avascular necrosis of femoral head, out of which 7 were males (54%) and 6 were females (46%). Thus, the gender ratio was approximately 1.2:1.

Mitchell DG et al<sup>5</sup> got a sex ratio of 1.43:1 and Beltran et al<sup>6</sup> got 1.7:1. Thus, in our study, we got a slightly lower sex ratio. In our study, more cases were bilateral, which is consistent with the other previous studies as shown in the table below.

	Mitchell DG et al <sup>5</sup>	Beltran et al <sup>6</sup>	Present Study
Unilateral (%)	17	36	39
Bilateral (%)	83	64	61

Thus, our findings are correlating with those of Beltran et al.<sup>6</sup> The most common causative association in the present study was the use of steroids, which is consistent with the findings obtained by Mitchell DG et al<sup>7</sup> and Beltran et al.<sup>6</sup>

The conversion of haematopoietic to fatty marrow is known to correlate with physiologic decreases in intramedullary blood flow and the risk of AVN. Of the 12 patients, less than 50 years of age with avascular necrosis only 5 patients (42%) in the present study had predominantly haematopoietic intertrochanteric marrow, which is in par with Mitchell DG and colleagues<sup>5</sup> who found haematopoietic intertrochanteric marrow in only 33% of cases Other important imaging findings that were particularly assessed were as follows.

Imaging Findings Assessed	Mitchell DG et al <sup>5</sup> (Radiology 1986)	Beltran et al <sup>6</sup> (Radiology 1986)	Present Study
Focal Defects	96%	100%	92% (12 Cases)
Low Signal Margin	97%	80%	85% (11 Cases)
Double Line Sign	80%	71%	69% (9 Cases)

Focal defects involving the anterosuperior aspects of the femoral head were seen in 92% of cases in the present study.

A line of low signal intensity surrounding the focal defects was seen in 85% of cases in the present study while Mitchell DG et al<sup>5</sup> (Radiology 1986) and Mitchell DG et al<sup>6</sup> (Radiology 1987) found it in 97% and 80% of the cases respectively.

A double line sign seen as an outer low signal intensity rim and an inner high intensity band on T2W images was seen in 69% of cases, which is consistent with the previous studies- Mitchell DG et al<sup>5</sup> (Radiology 1986) and Mitchell DG et al<sup>7</sup> (Radiology 1987) found it in 80% and 71% of the cases respectively. They concluded that while a margin of low signal intensity might be seen around any bone lesion with a sclerotic rim. The double line sign was more consistent with the distinctive histopathology of AVN.

**The Patterns of Contrast Enhancement were studied with Respect to Three Major Patterns as follows.**

Pattern	Li and Hiette et al <sup>8</sup>	Present study
Focal Areas of Poorly Enhancing Tissues Surrounded by a Bright Enhancing Rim	39%	50%
Diffuse Enhancement of Femoral Head and Neck	16%	8%
Combination of the above Two Patterns	45%	33%

Thus, in the present study, we found a slightly higher percentage of the pattern of focal areas of poorly-enhancing tissues surrounded by a bright enhancing rim. The rim represents the zone of hyperaemia while the poorly-enhancing areas represent necrotic areas. This data supports the hypothesis that early nontraumatic osteonecrosis is associated with hyperaemia and/or an increase in capillary permeability rather than acute devascularisation and that diffuse marrow oedema is the initial finding in early nontraumatic osteonecrosis.<sup>8</sup>

In our study, evidence of hip joint infective pathologies on MRI consisted of abnormalities of the bone marrow with decreased signal intensity on T1W1 and increased signal intensity on T2W1 or STIR images as described in the previous studies by Unger E. et al.<sup>9</sup>

Associated cellulitis and soft tissue infection had increased signal on T2W1 infiltrating the fat and in some cases the muscles.

On post-contrast studies, there was evidence of rim enhancement of 11 out of 12 lesions (92%) in the bones and soft tissues around a central focus of low signal intensity. In one case (8%), there was uniform enhancement of the marrow and the soft tissue. This is in agreement with the study by Morrison WB et al<sup>10</sup> who found rim enhancement in 95% of the cases. They concluded that fat suppressed contrast enhanced MR imaging was more sensitive and significantly more specific than nonenhanced MR imaging.

Out of the 12 cases of infection, all had evidence of arthritis. Arthritis was assessed for the various imaging features as Follows.

MRI Findings	Tuberculosis		Pyogenic	
	Hong SH et al <sup>11</sup>	Present Study	Hong SH et al <sup>11</sup>	Present Study
Bona Erosion	83%	44%	46%	0%
Marrow Signal Abnormality	59%	78%	92%	100%
<b>Bony Abnormalities</b>				

In our study, we found bone erosion to be much more common with tuberculous than with pyogenic arthritis. The marrow signal abnormality change is seen in accordance to the findings obtained by Hong SH et al<sup>11</sup> who found significantly larger percentage of marrow signal abnormalities in pyogenic arthritis.

MRI Findings	Tuberculosis		Pyogenic	
	Hong SH et al <sup>11</sup>	Present Study	Hong SH et al <sup>11</sup>	Present study
High	17%	11%	46%	33%
Intermediate	83%	100%	54%	67%
<b>Prominent Signal Intensity of Synovial Abnormalities on T2-Weighted Image</b>				

In agreement with the study by Hong SH et al,<sup>11</sup> the present study found no significant differences in the signal characteristics of the synovium between tuberculous and pyogenic arthritis.

MRI Findings	Tuberculosis		Pyogenic	
	Hong SH et al <sup>11</sup>	Present Study	Hong SH et al <sup>11</sup>	Present Study
Smooth Margin	70%	78%	17%	0%
Irregular Margin	30%	22%	83%	100%
<b>Extra-articular extension</b>				

Gadolinium-enhanced images delineate true infection boundaries. Contrast enhancement is particularly useful for distinguishing between abscesses and the surrounding myositis.

Hong SH et al<sup>11</sup> found that extra-articular lesions in tuberculous arthritis usually consist of abscesses and tend to have smooth boundaries while in contrast. A large number of lesions with pyogenic arthritis showed irregular boundaries of

extra-articular extension with or without abscesses. Our present study too matched these findings.

MRI Findings	Tuberculosis		Pyogenic	
	Hong SH et al <sup>11</sup>	Present Study	Hong SH et al <sup>11</sup>	Present Study
Thin and Smooth	100%	89%	29%	0%
Thick and Irregular	0%	11%	71%	100%
<b>Abscess Wall</b>				

In our study, MR imaging showed well-defined tuberculous abscesses, which usually had thin and smooth walls. In contrast, pyogenic abscesses had thick and irregular walls.

This is in similarity to what Hong SH et al<sup>11</sup> concluded as the most useful information in the differentiation of tuberculous arthritis and pyogenic arthritis. There were three cases of Legg-Calve-Perthes disease. Also, abnormalities in the contour of the cartilage seen as irregularity and focal thickening was seen in all the cases. This increased thickness was asymmetrical and it was most prominent in the medial and lateral aspects of the head with almost no thickening superiorly. These similar findings were also seen by Jaramillo D et al<sup>12</sup> (In 59% of cases) and by Rush BH et al<sup>13</sup> (In 70% of cases). There were two cases of slipped capital femoral epiphysis out of which both show slip of epiphysis and one show oedema involving the epiphysis. Similar findings are also seen by Umans et al.<sup>14</sup>

There were two cases of developmental dysplasia of hip referred from Paediatrics Department studied with ultrasound. Both cases showed small-sized femoral epiphysis and joint space widening.

Three cases of osteoarthritis were seen showing superolateral joint space narrowing and osteophytes.

In all three (100%), articular erosion in 2 (67%) and subchondral cysts in 2 cases (67%).<sup>15</sup>

Three patients referred with hip joint pain were found to have changes involving bilateral sacroiliac joints along with hip joint findings. All three cases showed symmetrical joint space reduction, marginal erosions, and marrow (100%). Joint effusion and synovial thickening was observed in two cases (67%).<sup>16</sup> These patients were diagnosed as inflammatory arthritis. One case of metastasis was detected on evaluation of painful hip and was seen as an ill-defined lesion, which was hypointense on T1W and hyperintense on T2W images involving neck, part of head, and trochanteric region of the left femur. This was confirmed on biopsy.<sup>17</sup>

Hence, in our study compared to MRI, x-ray proved to be a good investigation for diagnosing hip joint pathologies in paediatric as well as geriatric conditions. However, for early diagnosis of pathologies like osteonecrosis, detection of infections, and stress fractures, MRI proved to be superior in contrast resolution and without being harmful. USG examination proved to be an important modality for diagnosing developmental dysplasia of head of femur and it also can characterise the presence of joint fluid with ease.

**SUMMARY AND CONCLUSION**

1. It is the most accurate non-invasive investigation for the evaluation of various hip pathologies in their early/occult stage.
2. It is safe. Non-ionising, non-operator dependent with multiplanar capability.
3. It can be performed in all groups of patients including pregnant women.
4. The superior spatial and contrast resolution provided by MR imaging makes it very sensitive and specific in delineating hip pathologies.
5. The soft tissues around the hip joint including the articular cartilage, symposium, and labrum are clearly depicted by MRI.
6. Based on signal intensity changes, MRI can be helpful in tissue characterisation of the lesion e.g. fat, fluid, blood, etc. Hence, it is helpful in staging the lesion on which the clinical/surgical management is dependent.

In conclusions, the importance of early diagnosis can be gauged from the fact that the early initiation of treatment creates the difference between a responsible, worthwhile life, and a crippled handicapped life. It is really a culpable offense if a potentially curable disease is not diagnosed early as rehabilitative measures are also considerably delayed. The role of imaging can never be undermined considering the fact that early suspicion and detection is within the realms of imaging.

From a basic modality in the form of x ray to the highest modality in the form of MRI, each of them has a definite role to play. However, cheap as it is, even the humble plain radiograph retains the ability to lead a clinician to a reasonably good diagnosis to facilitate early treatment. As is evident in our study, the combined modalities of x ray, USG, CT, and MR along with adequate clinical information are often self-sufficient for establishing a diagnosis of spinal tuberculosis.

The wide availability of CT has brought it within the reach of the common people and is gradually replacing x-ray as the modality of choice. This has largely occurred due to the undeniable superiority of CT in detecting small bony destructions characterising soft tissue lesions and in the accurate delineation of exact extent of disease and squeal thereby narrowing the differential diagnosis.

MRI has the important role of resolving these diagnostic dilemmas by virtue of its inherent soft tissue contrast, unparalleled imaging of the cartilage and symposium, delineation of the ligaments and bursa. If the cost factor and the limited availability of MRI can be neutralised, then MRI represents the zenith in the imaging of hip joint pathologies. In our study, it can be inferred that MRI can be complete investigation by itself. As of now, MRI has still a long way to go before it becomes a common man's modality. CT and MR are gradually displacing x rays as the modality of choice in those centres where affordability is not an issue. However, x ray remains the modality of choice particularly in the Indian setting where MRI is not easily available.

**REFERENCES**

1. Berquist TH. Pelvis, hips, and thigh. In: Berquist TH, ed. MRI of musculoskeletal system. 4<sup>th</sup> edn. Philadelphia, USA: Lippincott Williams and Wilkins 2001:195-291.
2. Mitchell DG, Rao VM, Dalinka M, et al. Haematopoietic and fatty bone marrow distribution in the normal and ischaemic hip: new observations with 1.5-T MR imaging. *Radiology* 1986;161(1):199-202.
3. Williams PL. *Gray's Anatomy*. 37<sup>th</sup> ed. Edinburgh: Churchill Livingstone 1989:1631-1637.
4. Mitchell DG, Rao VM, Dalinka MK, et al. Femoral head avascular necrosis: correlation of MR imaging, radiographic staging, radionuclide imaging, and clinical findings. *Radiology* 1987;162(3):709-15.
5. Johnson ND, Wood BP, Jackman KV. Complex infantile and congenital hip dislocation: assessment with MR imaging. *Radiology* 1988;168(1):151-6.
6. Beltran J, Herman LJ, Burk JM, et al. Femoral head avascular necrosis: MR imaging with clinicopathologic and radionuclide correlation. *Radiology* 1988;166(1Pt 1):215-20.
7. Turner DA, Templeton AC, Selzer PM, et al. Femoral capital osteonecrosis: MR findings of diffuse marrow abnormalities without focal lesions. *Radiology* 1989;171(1):135-40.
8. Li KCP, Hiette P. Contrast enhanced fat saturation MRI for studying the pathophysiology of osteonecrosis of the hips. *Skeletal Radiology* 1992;21(6):375-9.
9. Lang P, Mauz M, Schorner W, et al. Acute fracture of the femoral neck: assessment of femoral head perfusion with gadopentetate dimeglumine-enhanced MR imaging. *AJR* 1993;160(2):335-41.
10. Haramati N, Staron RD, Barax C, et al. Magnetic resonance imaging of occult fractures of the proximal femur. *Skeletal Radiology* 1994;23(1):19-22.
11. Morrison WB, Schweitzer ME, Bock GW, et al. Diagnosis of osteomyelitis: utility of fat-suppressed contrast-enhanced MR imaging. *Radiology* 1993;189(1):271-7.
12. Hong SH, Kim SM, Ahn JM, et al. Tuberculous versus pyogenic arthritis: MR imaging evaluation. *Radiology* 2001;218(3):848-53.
13. Feldman F, Staron RB. MRI of seemingly isolated greater trochanteric fractures. *AJR* 2004;183(2):323-9.
14. Lida S, Harada Y, Shimizu K, et al. Correlation between bone marrow oedema and collapse of the femoral head in steroid-induced osteonecrosis. *AJR* 2000;174(3):735-43.
15. Froberg PK, Braunstein E, Buckwalter KA. Osteonecrosis, transient osteoporosis, and transient bone marrow oedema: current concepts. *Radiologic Clinics of North America* 1996;34(2):273-91.
16. Hofmann S, Engel A, Neuhold A, et al. Bone marrow oedema syndrome and transient osteoporosis of the hip: an MRI controlled study of treatment by core decompression. *J Bone Joint Surgery* 1993;75(2):210-6.
17. Kaplan SS, Stegman CJ. Transient osteoporosis of the hip. *J Bone Joint Surg Am* 1985;67(3):490-92.