

CASE REPORT

REVERSIBLE HEMICHOREA IN NONKETOTIC HYPERGLYCEMIA: A CASE REPORT

Jasmine Kaur Sachdeva¹, Davinder Singh Mahajan², Harsh Chalana³, Kulvinder Singh⁴, Ranjeet Kaur⁵

HOW TO CITE THIS ARTICLE:

Jasmine Kaur Sachdeva, Davinder Singh Mahajan, Harsh Chalana, Kulvinder Singh, Ranjeet Kaur. "Reversible hemichorea in nonketotic hyperglycemia: a case report". *Journal of Evolution of Medical and Dental Sciences* 2013; Vol2, Issue 32, August 12; Page: 6047-6049.

INTRODUCTION: Chorea is a rare manifestation of primary diabetes mellitus, and nonketotic hyperglycemia can unusually cause chorea. These choreiform movements have been described with lesions in the basal ganglia. **CASE REPORT:** We report a similar case of a 50 year old woman presenting to our institute with nonketotic hyperglycemia and hemichorea which improved with normalization of blood glucose. MRI showed significant changes correlating to her symptoms. **Discussion:** We support the hypothesis that chorea in patients with nonketotic hyperglycemia might be due to direct effects of hyperglycemia on basal ganglia.

INTRODUCTION: Chorea is a rare manifestation of primary diabetes mellitus, and nonketotic hyperglycemia can unusually cause chorea. These choreiform movements have been described with lesions in the basal ganglia. Positive MRI findings in nonketotic hyperglycemia may help to identify structural lesions that could cause chorea and may also guide prompt appropriate therapy. There have been a few case and case series reports but long term follow up is lacking. We report a similar case presenting to our hospital with significant MRI changes which were found to be related to hyperglycemia.

CASE REPORT: A 50 year old woman, presented to Emergency department of Sriguru Ramdas Institute of Medical Sciences and Research with history of sudden onset involuntary, non rhythmic, semi directed movements of right upper and lower limb for past two days. They were aggravated with movement and improved during sleep. She was not able to walk due to these movements. No such movements were noted on trunk or face. Her movements were diagnosed as hemi choreiform type. She was a known case of diabetes mellitus for past 9 years, but on irregular treatment (metformin 1000 mg/day, glimepiride 2mg/day). There was no past history of transient ischemic attacks, rheumatic fever, headache, skin rash or fever, cigarette smoking or alcohol abuse. She denied taking any other medication like levodopa, neuroleptics, antiepileptics, or domperidone. On clinical examination she was moderately build and nourished, well oriented to time, place and person. Her higher mental functions including memory, attention and concentration, and judgement were normal. There was no speech disorder. Muscles showed mild hypotonia with normal power and deep tendon reflexes. Cranial nerves showed no deficit. Her vitals were within range with blood pressure 132/78 mm Hg, pulse rate 87/min, resp. rate 11/min. Ophthalmology opinion was taken and on slit lamp examination, Kayser Fleischer rings were not found. In lab investigations, hemoglobin was 12.1 g%, total white cell count 9,600 /mm³, with differential count of N 79 L19 E1. Liver function tests, BUN, serum creatinine, serum osmolality and serum ceruloplasmin levels were within normal range. Blood film did not show any acanthocytes. Blood glucose concentration was

CASE REPORT

503 mg% with HbA1C of 9.3%. Her serum sodium was 131 mEq/L, potassium 3.9 mEq/L, serum calcium 8.9 mEq/L, and magnesium 2.7 mEq/L. Urine examination showed 3+ for glucose and absent ketones. Her MRI Brain (image 1) showed e/o well defined T1W hyperintensity seen involving left lentiform nuclei and caudate head with sparing of anterior limb of internal capsule; on T2W there was inhomogeneous hypointensity. Electroencephalogram was normal. She was started on regular Insulin with hourly blood glucose monitoring for next 24 hours, after which glucose level subsided to 236 mg%. After 48 hours, her blood glucose was 136 mg% and her choreiform movements also improved completely and did not recur throughout the hospital stay. She was discharged after 5 days on Mixtard insulin. At monthly follow up visits for next 3 months, she remained asymptomatic with normal blood glucose levels and no relapse of choreiform movements.

DISCUSSION: Chorea has been reported to be due to depletion or supersensitivity of dopamine receptors, as in Huntington's chorea and tardive dyskinesia respectively. However, correlation between chorea and hyperglycemia has not been well established, though there have been various case reports and hypothesis to support the same. Hyland & Froman¹ reported that as hypertension and diabetes mellitus greatly increase the risk of stroke, lacunar infarction in the contralateral basal ganglion might be the cause of movement disorder in patients with nonketotic hyperglycemia. In hyperglycemia, cellular energy demand shifts towards anaerobic metabolism, which inhibits the function of the tricarboxylic acid cycle and causes the brain to metabolize gamma-aminobutyric acid as an alternative energy source. Patients with ketosis would have an abundant source of acetoacetate from which gamma-aminobutyric acid might be resynthesized, but in non-ketotic patients, it would be rapidly depleted. In animal studies, gamma-aminobutyric acid antagonists can cause a lesion in the subthalamic nucleus inducing contralateral hemichorea. Therefore depletion of gamma-aminobutyric acid in the brain may play an important part in the pathogenesis of the non-ketotic hyperglycemia. Chorea has also been linked to direct effects of changes in blood glucose levels (Newman & Kinkel², Hamide et al³), and to serum osmolality changes (Lin & Chang⁴).

However, in our case osmolality was normal and patient responded well to blood glucose normalization. In our case, MRI suggests involvement of caudate head and lentiform nuclei as evident in image 1. Lai et al⁵ reported a case series of neuroimaging findings in chorea in which CT studies showed a hyperdense putamen and/or caudate nucleus; and T1-weighted MR images showed hyperintense lesions without significant T2 signal alternation at the basal ganglia. Yerdelen et al⁶ presented a patient with generalized chorea associated with nonketotic hyperglycemia without cerebral magnetic resonance imaging features, but with single photon emission computed tomography findings. However, we were not able to perform SPECT study.

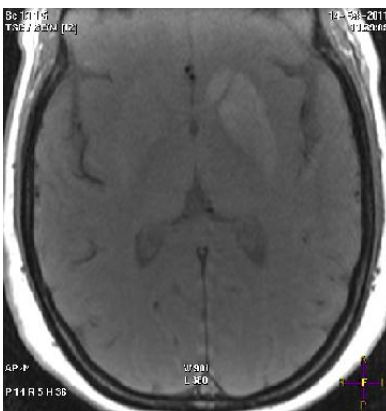
We support the hypothesis that chorea in patients with nonketotic hyperglycemia might be due to direct effects of hyperglycemia on basal ganglia which is suggested by temporal correlation of symptoms with hyperglycemia and their amelioration with treatment.

REFERENCES:

1. Hyland H, Froman DM. Prognosis in hemiballism. *Neurology* 1957;7:381-91
2. Newman RP, Kinkel WR. Paroxysmal choreoathetosis due to hypoglycemia. *Arch Neurol* 1984; 41 : 341-42

CASE REPORT

3. Hamide A, Kumarsamy R, Srimannarayana J, Mathew J, Das AK. Chorea due to nonketotic hyperglycemia. Neurology India 2002; 50(2): 213-4.
4. Juei-Jueng Lin, Ming-Key Chang. Hemiballism-hemichorea and non-ketotic Hyperglycaemia. Journal of Neurology, Neurosurgery, and Psychiatry 1994;57:748-50
5. Ping-Hong Lai, Robert D. Tien, Ming-Hong Chang, Michael M. H. Teng, Chien-Fang Yang, Huay-Ben Pan, Clement Chen, Jiing-Feng Lirng, Koon-Wah Kong. Chorea-Ballismus with Nonketotic Hyperglycemia in Primary Diabetes Mellitus. Am J Neuroradiol 1996 June; 17:1057-64.
6. Yerdelen Deniz , Karatas Mehmet , Aydin Mehmeý . Generalized Chorea Associated With Nonketotic Hyperglycemia: Cerebral MRI and SPECT Findings. Neurosurgery Quarterly. 2008 March; 18(1):72-3.



AUTHORS:

1. Jasmine Kaur Sachdeva
2. Davinder Singh Mahajan
3. Harsh Chalana
4. Kulvinder Singh
5. Ranjeet Kaur

PARTICULARS OF CONTRIBUTORS:

1. Assistant Professor, Department of Medicine, SGRDIMSR, Amritsar.
2. Professor, Department of Medicine, SGRDIMSR, Amritsar.
3. Assistant Professor, Department of Psychiatry, SGRDIMSR, Amritsar.
4. Assistant Professor, Department of Radiodiagnosis, SGRDIMSR, Amritsar.

5. Assistant Professor, Department of Medicine, SGRDIMSR, Amritsar.

NAME ADDRESS EMAIL ID OF THE CORRESPONDING AUTHOR:

Dr. Jasmine Kaur Sachdeva,
Assistant Professor,
Department of Medicine,
Shriguru Ramdas Institute of Medical Sciences &
Research, Vallah, Amritsar.
Email – jasmine_sachdeva79@yahoo.com

Date of Submission: 26/07/2013.

Date of Peer Review: 27/07/2013.

Date of Acceptance: 05/08/2013.

Date of Publishing: 08/08/2013.