

CHRONIC XANTHOMATOUS CHOLECYSTITIS

Iyad Anabtawi¹, Raad Dowais², Malavalli Venkataramu Damodhar³

¹Consultant Surgeon, Security Forces Hospital, Dammam.

²Registrar Surgeon, Security Forces Hospital, Dammam.

³Resident Surgeon, Security Forces Hospital, Dammam.

ABSTRACT

BACKGROUND

Xanthogranulomatous Cholecystitis is a rare inflammatory disease of the gallbladder characterised by a focal or diffuse destructive inflammatory process with accumulation of lipid laden macrophages, fibrous tissue and acute and chronic inflammatory cells. Its importance lies in the fact that it is a benign condition that may be confused with carcinoma of the gallbladder, which is associated with a poor prognosis. It was initially described as a variant of chronic cholecystitis; it has an active destructive process that can lead to significant morbidity as the inflammatory process usually extends into the gallbladder wall and adjacent structures.^[1]

KEYWORDS

Gallbladder, Acute Cholecystitis, Chronic Xanthogranulomatous.

HOW TO CITE THIS ARTICLE: Anabtawi I, Dowais R, Damodhar MV. Chronic xanthomatous cholecystitis. J. Evolution Med. Dent. Sci. 2017;6(19):1552-1554, DOI: 10.14260/jemds/2017/340

BACKGROUND

Xanthogranulomatous cholecystitis (XGC). It is a benign condition that may be confused with carcinoma of the gallbladder, which is associated with a poor prognosis. Gallstones may have an important role in the pathogenesis, since they appear to be present in most patients. The clinical and laboratory findings of cases are similar to those of acute or chronic cholecystitis. Patients are frequently misdiagnosed with imaging studies and even during the operation as having carcinoma of the gallbladder.^[2] We would like to share a case of xanthogranulomatous cholecystitis that was associated with focal adenomyosis, which was presented to our clinic which is also an unusual presentation.

Case Report

A 61-year-old male presented with chronic abdominal pain; patient was admitted previously one month back for the same complaints. Pain was associated with nausea, but no vomiting. Patient is allergic to egg and is a known smoker. Patient had previously undergone lateral sphincterotomy or rectopexy many years back, which he faintly remembers. Patient had normal vital signs. Abdominal examination revealed midline incisional hernia which is reducible, tenderness in right hypochondrium and epigastric region without any palpable lump. Laboratory tests revealed Haemoglobin 13.5 g/dL, leucocytic counts 12,600, Bilirubin Total/Direct 3.68/3.35 mg/dL, AST 230 IU/L, ALT 216 IU/L and Alkaline Phosphatase 272 IU/L.

Financial or Other, Competing Interest: None.

Submission 12-12-2016, Peer Review 19-02-2017,

Acceptance 25-02-2017, Published 06-03-2017.

Corresponding Author:

Dr. Malavalli Venkataramu Damodhar,

Security Forces Hospital, Dammam,

Abu Hadriya Road,


King Fahd Suburb,

Ad Dammam - 31413,

Kingdom of Saudi Arabia.

E-mail: damun7@hotmail.com

DOI: 10.14260/jemds/2017/340



Abdominal Ultrasonography showed contracted gallbladder containing multiple small stones, heterogeneous mass-like lesion measured about 2.7 x 2.6 cms at the fundus of the gallbladder. No pericholecystic fluid with dilated common bile duct measuring about 11 mm (Figure 1).

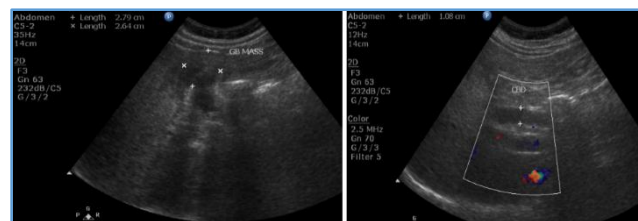

Figure 1. Abdominal Ultrasonography showing the Gallbladder Mass

CT scan of the abdomen with IV contrast showed mild increase in wall thickness of the gallbladder with lobulated mass-like lesion at the fundus of gallbladder. This mass shows peripheral contrast enhancement with central hypodensity. This picture goes with differential diagnosis of gallbladder carcinoma versus focal chronic cholecystitis.

In addition to dilatation of both cystic and CBD duct associated with recurrent paraumbilical hernia (Figure 2).

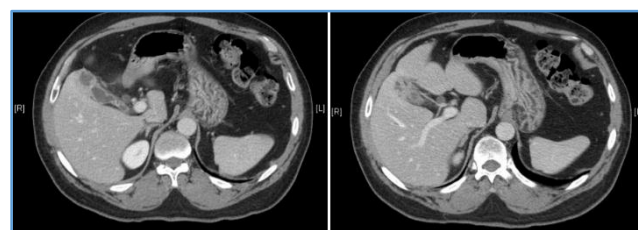


Figure 2. Arrow showing the Increase in Gallbladder Wall Thickness

Magnetic Resonance Cholangiopancreatography (MRCP) showed mild dilatation of intrahepatic biliary radicles, dilated tortuous cystic duct and dilated CBD with two small stones at its distal part measured about 6 x 6 and 3 x 2 mm, Figure 3.

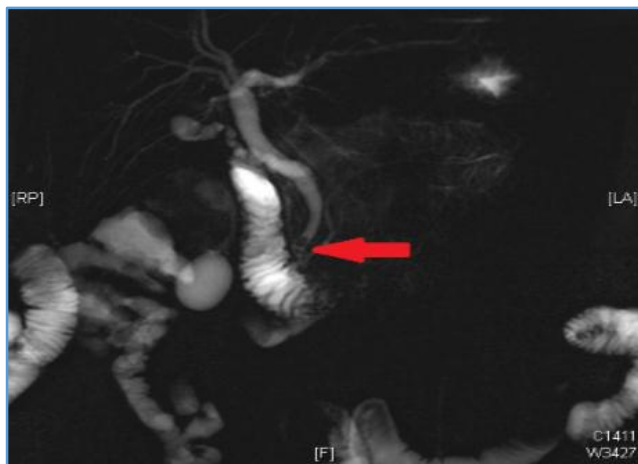


Figure 3. Arrow Pointing to the Stones in the Common Bile Duct

Patient on the second day underwent Endoscopic Retrograde Cholangiopancreatography (ERCP), sphincterotomy was done and two stones were retrieved from CBD. Two weeks later after patient's discharge, laboratory tests were normalised and patient was admitted and underwent Open Cholecystectomy removing part of the liver bed surrounding the gallbladder as local invasion was observed intraoperatively. Mesh repair for the incisional hernia was done. The patient's course postoperatively went smooth with no significant morbidities.

On gross examination, gallbladder received open measures 4 x 1.5 x 0.5 cm with attached piece of liver tissue measuring about 2.5*2*3 cm. Microscopic examination reveals a thickened gallbladder wall with massive infiltration of all wall layers by mixed inflammatory cells mainly plasma cells, lymphocytes histiocytes, neutrophils and myofibroblasts. The glandular epithelium is found insinuated deeply in the wall; some of which is partially destroyed by inflammatory cellular reaction which is also present around nerve trunks. Many foamy histiocytes were present forming sheets of cells with focal multinucleate cell non-caseating granuloma formation. Some glands show moderate dysplasia. The liver tissue show mild focal compression changes with fibroinflammatory adhesions.

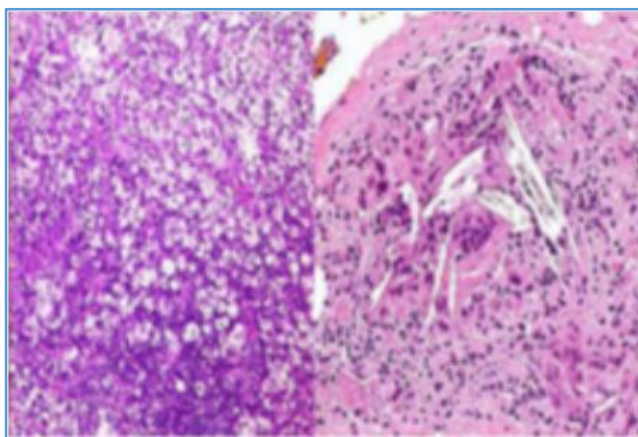


Figure 4. Xanthogranulomatous Cholecystitis - Note Numerous Vacuolated Macrophages and Cholesterol Clefts

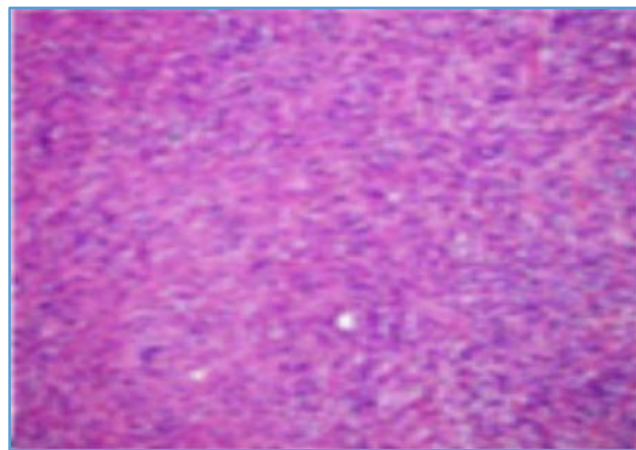


Figure 5. Inflammatory Pseudotumours

Patient was discharged on 5th postoperative day in a satisfactory condition. Patient is currently being followed up regularly in the General Surgery Clinic, Patient has no new complaints.

DISCUSSION

Introduction

It is an uncommon inflammatory disease of the gallbladder, which appears in 0.7% of population in the United States of America.

Pathogenesis

The pathogenesis is thought to be related to extravasation of bile into the gallbladder wall from rupture of Rokitansky-Aschoff sinuses or by mucosal ulceration.^[2] This event incites an inflammatory reaction in the interstitial tissue, whereby fibroblasts and macrophages phagocytose the biliary lipids in bile such as cholesterol and phospholipids leading to the formation of xanthoma cells. Gallstones may have an important role in the pathogenesis, since they appear to be present in all patients.^[3]

Pathology

On gross examination, the gallbladder is thickened and the serosa is covered with dense fibrous adhesions. The mucosal surface is ulcerated and cross sections through the wall reveals xanthogranulomatous foci, which appear as yellow nodules or plaques. These yellowish foci extended into adjacent structures such as the liver, duodenum, transverse colon and omentum.^[3]

Microscopically, the xanthogranulomatous foci are composed of abundant lipid laden macrophages, fibroblasts and inflammatory cells. The lipid laden macrophages are of two morphological types: rounded foamy macrophages and spindle-shaped cells with more granular cytoplasm and elongated nuclei.^[4]

Clinical Features

Clinical findings on physical examination and the results of laboratory tests do not appear to be of use in differentiating this gallbladder disorder from other more frequent types.^[5] The vomiting, upper right quadrant pain, positive Murphy's sign on sonography and leucocytosis observed in our patients are similar to the findings described in other types of cholecystitis.

A history of repeated episodes of biliary colic or pancreatitis is also fairly common. Physical examination is usually unremarkable except possibly for a positive Murphy's sign when acute cholecystitis is present. A right hypochondriac mass may be more common in Xanthogranulomatous Cholecystitis than in acute cholecystitis, mimicking carcinoma of the gallbladder.^[6]

Complications

There is a fairly high incidence of complications in Xanthogranulomatous Cholecystitis, amounting to more than 30 percent in one report.^[6] Local complications in the gallbladder include perforation and the development of strictures. Prolonged cystic duct obstruction and gallbladder distension under pressure during the acute inflammatory phase can lead to extension of the xanthogranulomatous inflammation beyond the gallbladder with formation of hepatic abscesses and fistulas into adjacent structures.

Diagnosis

The diagnosis is usually made by histological examination of the resected gallbladder. The possibility of Xanthogranulomatous Cholecystitis should be considered in any patient presenting with a right upper quadrant mass and/or a biliary fistula. There are no consistent trends in biochemical or haematological findings that aid in the diagnosis. Imaging studies and fine needle aspiration cytology may be suggestive, but no reports on their utility exist. Confirmatory diagnosis is made only at surgery, sometimes requiring a frozen section.

Ultrasonography often shows a thickened gallbladder wall (which may be focal or diffuse) with gallstones. Other findings on ultrasonography include a gallbladder mass, subhepatic fluid collection, obscure border between the gallbladder and liver, intramural hypoechoic nodules and rarely gas in the biliary tree in patients with a biliary fistula.^[6]

As with sonography, thickening of the gallbladder wall was also the most frequent CT finding. Two patients presented with a hypoattenuated band around the gallbladder similar to that described by Chun et al^[7] and homogeneous uptake of contrast material by the gallbladder mucosa. In these patients, CT was performed during an acute episode of cholecystitis. The most specific CT finding in a review of 26 patients was a hypodense band in the gallbladder wall, which was seen in 33 percent of patients.

Magnetic Resonance Imaging (MRI) - Data on the accuracy of MRI in diagnosing xanthogranulomatous cholecystitis are limited, the addition of diffusion-weighted

MRI enabled better differentiation of xanthogranulomatous cholecystitis from gallbladder cancer.

Fine-needle aspiration biopsy has been used in several cases with good results.

Treatment

The only definitive treatment for xanthogranulomatous cholecystitis is surgery. The general principles for the management of acute cholecystitis should be followed in patients who present with acute cholecystitis.

Because of the inflammatory and invasive nature of xanthogranulomatous cholecystitis, a complete resection of adjacent xanthogranulomatous tissue should be attempted, even if this includes resection into the hepatic bed.^[6]

Open cholecystectomy is the preferred surgical technique in most patients due to dense fibrosis, extensive local inflammation and concerns of possible coexistent malignancy.^[8]

REFERENCES

- [1] Dixit VK, Prakash A, Gupta A, et al. Xanthogranulomatous cholecystitis. *Dig Dis Sci* 1998;43(5):940-2.
- [2] Belekar D, Verma R. An unusual case of acute-on-chronic xanthogranulomatous cholecystitis. *The Internet Journal of Surgery* 2008;19(2):1-3.
- [3] Yildirim M, Oztekin O, Akdamar F, et al. Xanthogranulomatous cholecystitis remains a challenge in medical practice: experience in 24 cases. *Radiol Oncol* 2009;43(2):76-83.
- [4] Krishna RP, Kumar A, Singh RK, et al. Xanthogranulomatous inflammatory strictures of extrahepatic biliary tract: presentation and surgical management. *J Gastrointest Surg* 2008;12(5):836-41.
- [5] Houston JP, Collins MC, Cameron I, et al. Xanthogranulomatous cholecystitis. *Br J Surg* 1994;81(7):1030-2.
- [6] Srinivas GN, Sinha S, Ryley N, et al. Perfidious gallbladders - a diagnostic dilemma with xanthogranulomatous cholecystitis. *Ann R Coll Surg Engl* 2007;89(2):168-72.
- [7] Chun KA, Ha HK, Yu ES, et al. Xanthogranulomatous cholecystitis: CT features with emphasis on differentiation from gallbladder carcinoma. *Radiology* 1997;203(1):93-7.
- [8] Reed A, Ryan C, Schwartz SI. Xanthogranulomatous cholecystitis. *J Am Coll Surg* 1994;179(2):249-52.