

CASE REPORT

A CASE REPORT ON ORBITAL BOTRYOMYCOSIS

H. N Sowbhagya, Pooja Patil, M. S Smitha Gowda, Kiran Kumar L, Aisha Rafi

1. Professor. Department of Ophthalmology, Kempegowda Institute Of Medical Sciences & Research Centre.
2. Post Graduate. Department of Ophthalmology, Kempegowda Institute Of Medical Sciences & Research Centre.
3. Post Graduate. Department of Ophthalmology, Kempegowda Institute Of Medical Sciences & Research Centre.
4. Assistant Professor. Department of Ophthalmology, Kempegowda Institute Of Medical Sciences & Research Centre.
5. Post Graduate. Department of Ophthalmology, Kempegowda Institute Of Medical Sciences & Research Centre.

CORRESPONDING AUTHOR:

Dr H. N. Sowbhagya,
No 41-42/45 Sri Guru Krupa,
7th Cross, Saraswathipuram,
Nandini Lay Out Main Road,
Bangalore- 560 096.
E-mail: drhnsowbhagyaappaji@gmail.com

ABSTRACT: BOTRYOMYCOSIS; also known as **bacterial pseudomycosis** is a rare chronic granulomatous bacterial infection that affects the skin, and sometimes the viscera. Here we report a rare case of orbital botryomycosis in a patient who presented with painful nodular lesion in right eye following repair of tissue for Road Traffic Accident(RTA). MRI revealed foreign body granuloma or pseudotumour subsequent histopathology proved botryomycosis and she was treated with antibiotics and surgery .

INTRODUCTION: Botryomycosis; also known as **bacterial pseudomycosis** is a rare chronic granulomatous bacterial infection that affects the skin, and sometimes the viscera.⁽¹⁾ Botryomycosis is an uncommon chronic bacterial infection that generally presents as cutaneous lesion or rarely with visceral involvement. It was first considered a fungal infection, thus the term botryomycosis (from Greek, botrys – bunch of grapes, mycosis – fungal origin). Later, the bacterial etiology was discovered and other terms were reported, including actinophytosis, staphylococcal actinophytosis, bacterial pseudomycosis and granular bacteriosis ^(2,3). Many species of bacteria have been implicated most commonly staphylococcus aureus, but also pseudomonas aeruginosa, E coli & streptococcus species. ⁽⁵⁾

Winslow summarized the literature and subcategorized botryomycosis into integumental and visceral forms.⁽⁴⁾The integumental form is more common and is characterized by localized granulomatous skin infections often associated with trauma, foreign body and wound contamination. It usually involves the exposed parts. Visceral effects liver, lung, kidney, prostate, caecum, brain, lymph tissue.

Surgery, abrasions and lacerations in road accidents, piercing of pinna are documented etiological factors that may lead to the development of botryomycosis. Chronic cutaneous irritation and lichenified lesions of the scalp often predispose to botryomycosis. Diabetes, alcoholism, poor hygiene, cystic fibrosis and general debility are the known predisposing factors. Botryomycosis is also reported in children. In most cases infection remains localized,

CASE REPORT

although occasionally it spreads to other organs like the liver, kidney, lungs, heart and prostate, and lymph nodes. It is increasingly being reported from AIDS cases.⁽⁶⁾

CASE REPORT: 45 year old lady presented with a painful nodular lesion in right eye. On examination she had nodular lesion at supero-temporal part of right eye ball measuring 1cmx1cm with limitation of extraocular movements in both upward and lateral gaze, pupil was reactive and vision 6/18 in right eye. Left eye was normal vision 6/6. She had met with road traffic accident one and half years back. Impact of injury lead to lifting of soft tissue of the right side of the face, pre auricular region, periorbital tissue, nose and forward displacement of right eyeball along with periorbital tissue and associated with uncomplicated blow out fracture of right orbit. She was treated by suturing the soft tissue and skin in layers. Later patient had drooping of right upper lid, depressed globe and deformity of right part of face. MRI- showed blowout fracture of floor of right orbit with Minimally enhancing lesion in the region of lacrimal gland and a clinical diagnosis of foreign body granuloma or pseudotumor or chronic hematoma was made. Excision of the visible mass done and sent for histopathological examination.

Histopathological examination showed it as – fragments of fibrocollagenous tissue with numerous well formed histiocytic granuloma with foreign body as well as Langhans' type giant cells . Colonies of fine granular hematoxyphilic structures exhibiting splendor hoppeli phenomenon are seen. These are surrounded by neutrophils and eosinophils along with granular tissue. Lacrimal gland structures are not identified. Section was negative for malignancy[FIG -1]

Culture sensitivity yielded bacillus species heavy growth, sensitive to ampicillin, amoxicillin ,piperacillin, ceftazidime, amikacin, erythromycin and clindamycin.

Patient was treated with parenteral antibiotics inj. Amikacin 15mg/kg/day for 10 days, Azithromycin 500mg once daily for 3 months, and systemic anti-inflammatory drugs, topical drugs included lubricants, moxifloxacin (0.5%)and predacetate1.0% q i d for 3 months. Patient complained of progressive increase in pain with disturbed sleep and low grade fever. Examination revealed redness and dry frothy material discharge. Globe was depressed and mass was felt involving along lateral and superior orbital margin. Cornea showed decreased sensation and Inferior corneal opacity . vision 6/36. Extraocular movement were limited and diplopia was present

MRI after 3 months- revealed evidence of nodular soft tissue mass in the superolateral aspect of the extraconal compartment of right orbit measuring 25mm x17mm x 14mm with lesion embedded in the right lacrimal gland. Herniation of infraorbital fat and inferior rectus muscle through the inferior orbital ridge to the right maxillary sinus noted. There was No evidence of intracranial extension [FIG-2]

A diagnosis made of progression of botryomycosis .

Treated by exploratory orbitotomy and excision of the mass under general anesthesia . Material sent for gram stain, Giemsa stain, KOH stain, HPE and culture sensitivity.

Culture sensitivity- organism was sensitive to amoxicillin clavulanic acid , clindamycin, ciprofloxacin, cefepime, erythromycin and gentamycin.

HPE Showed lacrimal gland showed acini and ducts, dense fibrous collagenous tissue along with granulation tissue and histiocyte granulomas. Also seen are many foreign body and Langhan's type of giant cells. Amidst neutrophilic abscesses showed non filamentous bacterial

CASE REPORT

colonies surrounded by splendori -hoppeli reaction, Impression suggestive of botryomycosis. [FIG-6]

The case was treated with I v clindamycin 1.2 gm twice daily and gentamycin 80mg thrice daily for 7 days . Topically treated with azithromycin 1.0% , artificial tears. Subject developed dry eye disease, cornea started melting and pain did not subside. After 6 weeks patient had to undergo subtotal exenteration of orbit to relieve pain and to prevent other dreadful complication like panophthalmitis and intracranial extension of primary growth. Subject relieved of symptoms only after exenteration.

DISCUSSION: Botryomycosis was first reported by Bollinger in lung of horse in 1870⁸ .He reported multiple fibrous nodules containing areas of pus in which yellow white granules resembling those of actinomycosis were visible. Microscopically there was no evidence of branching filaments characteristic of actinomycosis. Rather there was coccus like bodies surrounded by a homogenous capsule. Until 1913, when Opie⁴ presented the case of a patient with hepatic botryomycosis, it was believed that the disease only occurred in animals⁹. Botryomycosis is best considered a reactive process initiated by low-grade bacterial infections. The lesions are generally indurated, fibrotic masses that may form draining sinuses and fistulae. Pathologically, botryomycosis is characterized by the presence of eosinophilic granules, with eosinophils surrounding central foci of necrosis, known as the Splendor-Hoeppeli effect. The difference between botryomycosis and fungal infection (e.g., with actinomyces) is the bacteria shown on Gram staining .⁽⁷⁾

As only a few cases of botryomycosis have been reported the guidelines for medical treatment are still insufficient to accurately suggest the correct duration of the antibiotic therapy for such patients.

Among patients with cutaneous botryomycosis, diabetes, chronic mucocutaneous candidiasis with T cell deficiency, systemic corticosteroid therapy and transient T cell impairment have been reported, but the majority of patients show no such predisposing factors. There was no evidence of any predisposing factor in present case except history of preceding trauma. A history of injury is common in cutaneous form, which stress the importance of a foreign body as well as infection. ¹⁰

CONCLUSION: This case study reports the importance of early evaluation, exploration and wound cleaning of all the trauma cases with open wounds. Resistant micro organisms under entrapment can cause various types of presentations like granuloma, abscess and the invasive infectious mass lesion like botryomycosis which are poor responders to systemic antibiotics. The wound exploration and thorough debridement of the contaminated wound at the time of wound reconstruction can prevent such destructive infectious manifestations. Surgical intervention is necessary. Initial prophylaxis of all the open traumatic wounds with povidone iodine and antibiotics and antifungals in cases of suspected contaminations can prevent disaster . Culture sensitivity of the materials obtained from trauma site can give clue to the suitable antibiotics to be administered systemically and topically in initial stages. All cases of open orbital wounds needs long term follow up.

REFERENCES:

1. James, William D.; Berger, Timothy G.; et al. (2006). *Andrews' Diseases of the Skin: clinical Dermatology*. Saunders Elsevier. [ISBN 0-7216-2921-0](#).

CASE REPORT

2. Mehregan DA, Su WPD, Anhalt JP. Cutaneous botryomycosis. *J Am Acad Dermatol.* 1991; 24:393-6
3. Bonifaz A, Carrasco E. Botryomycosis. *Int J Dermatol.* 1996;35:381-8
4. Winslow DJ: Botryomycosis. *Am J Pathol* 35:153, 1959
5. Caecal botryomycosis. A case review. Rachel H. Williams, MD, Mazen Kattih, MD, VOLUME 57, NO. 6, 2003
6. Katkar V, Mohammad F, Raut S, Amir R. Red grain botryomycosis due to *Staphylococcus aureus* - A novel case report. *Indian J Med Microbiol* 2009;27:370-2
7. Pulmonary botryomycosis: A difficult diagnosis in the preoperative patient; Russell Hodgson, Shane A. Blackmore and C. Peter Clarke. *J Thorac Cardiovasc Surg* 2005;130:924-925
8. Bollinger O: Mycosis der lunge beim pferde. *Virchows Arch [PA]* 49:586, 1870
9. OPIE E. L., *Arch. Intern Med.*, 2 (1913) 425.
10. Case report botryomycosis. c arun inamdar, SJ Naglotimath. *Indian journal of dermatology, venerology and leprology* 1994 vol60 issue 2 108-109
11. Botryomycosis with orbital invasion case report and literature review JOHN W. PRUITT, DDS, MD,* STEPHEN R. SABOL, DDS, *Journal of oromaxillary facial surgery* 1995

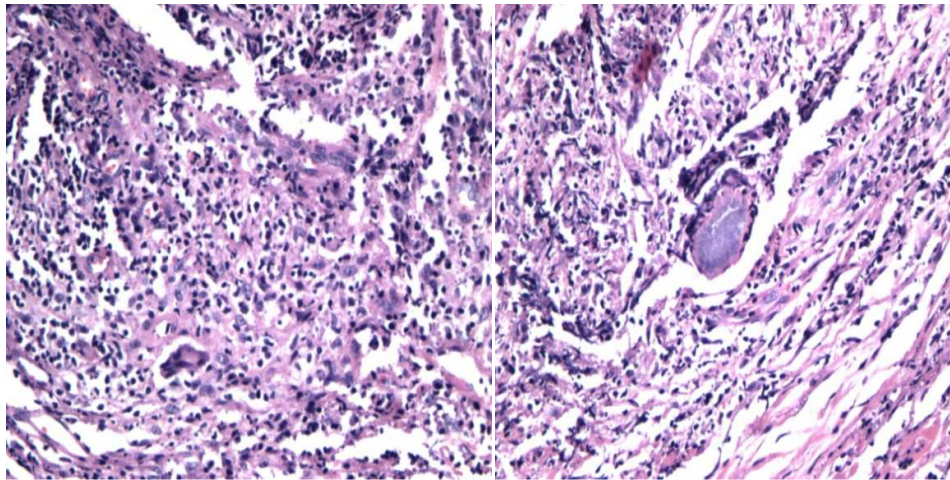


Fig 1 Impression botryomycosis with granulomatous inflammation. Soft tissue bit covered by squamous epithelium, stroma densely infiltrated by mononuclear cells. Also seen are scattered neutrophilic abscess with central necrosis and organism resembling actinomycetes. Many epithelial granuloma and giant cells are also seen.

CASE REPORT

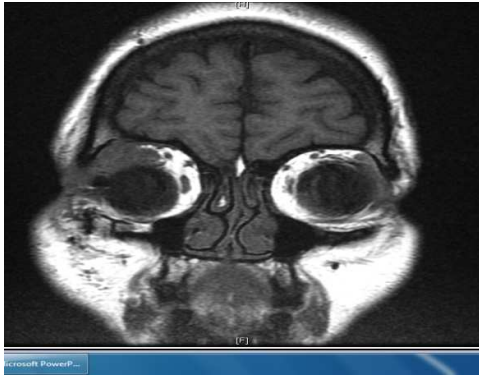

Fig -2 -MRI ORBIT

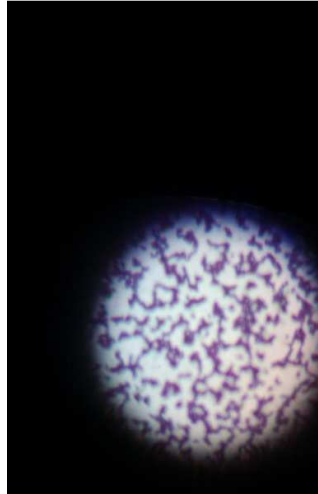

Fig -3 Gram stain - gram positive cocci in pairs and clusters staph aureus growth. Culture for fungus was negative

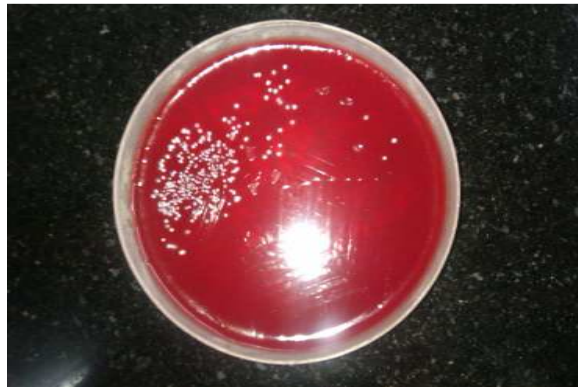

FIG-5 - Blood agar- cream lytic colonies

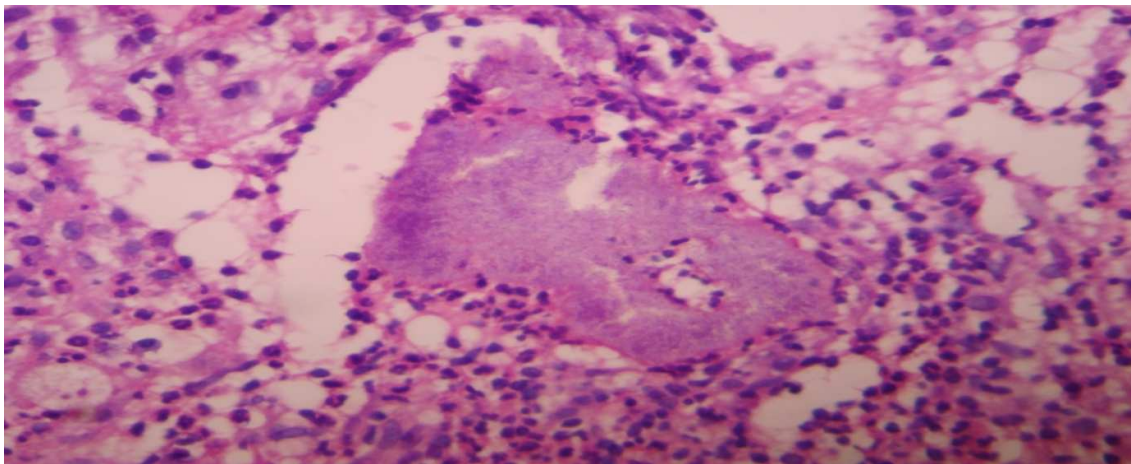


Fig-6