

**OTOGENIC BRAIN ABSCESS: OUR EXPERIENCE**Shashidhar S. Suligavi<sup>1</sup>, Shilpa Gokale<sup>2</sup>, Pradeep Jain<sup>3</sup>, S. S. Doddamani<sup>4</sup>, M. N. Patil<sup>5</sup>**HOW TO CITE THIS ARTICLE:**

Shashidhar S. Suligavi, Shilpa Gokale, Pradeep Jain, S. S. Doddamani, M. N. Patil. "Otogenic Brain Abscess: Our Experience". Journal of Evolution of Medical and Dental Sciences 2015; Vol. 4, Issue 13, February 12; Page: 2107-2111, DOI: 10.14260/jemds/2015/303

**ABSTRACT: OBJECTIVE:** To share our experience about otogenic brain abscess and to provide information about diagnosis and treatment of otogenic brain abscess (OBA). **MATERIALS & METHODS:** Eight patients with an average age of 20.62years (range of 8 to 51 years) were diagnosed with OBA. All patients had cholesteatoma except one. Six had cerebral and 2 had cerebellar abscess. All underwent medical & surgical treatment. No mortality was reported in our study with the mean follow up period of 11 months. **CONCLUSION:** OBA is a life threatening condition, which requires early diagnosis and aggressive treatment. Combined approach by ENT surgeon and neurosurgeon reduces morbidity and mortality to a great extent.

**KEYWORDS:** Brain abscess, mastoidectomy, combined approach.

**INTRODUCTION:** Brain abscess is a focal suppurative process in the brain parenchyma. Significant percentage of brain abscess is of otogenic origin. Antibiotic therapy has reduced the occurrence of complications of otitis media. In spite of this brain abscess is not a rare complication in developing countries with high incidence of cholesteatoma. The estimated incidence is 0.02-1.97% in developing countries compared to 0.04-0.15% in developed countries.<sup>[1,2]</sup>

Otogenic brain abscess is the second most common intracranial complication after meningitis. But it is most lethal with mortality rate ranging from 7-60%.<sup>[3,4]</sup> Otogenic causes constitute 25% of the abscesses in children, whereas in adults they constitute 50%.<sup>[3,5]</sup>

Computed Tomography (CT) is the best diagnostic tool for OBA. High. Suspicion and thorough clinical examination alongwith computed tomography scan will help in making early diagnosis. Timely aggressive treatment will help in reducing the morbidity and mortality of the disease

**MATERIALS AND METHODS:** Eight patients with OBA were admitted to ENT & neurosurgery wards for management during 2008 – 2013. Detailed history was taken and a thorough examination of ear, nose & throat were done in all cases. Neurological examination was done including level of consciousness, neck rigidity, kernig's sign, cerebellar signs, cranial nerve examination, nystagmus, speech, gait along with ophthalmoscopy.<sup>[6]</sup> Patients suspected of brain abscess had CT scanning of brain and temporal bone with contrast. Patients were given IV antibiotics, tension reducing agents and antiepileptics. Once the diagnosis was established, they underwent neurosurgery and ear surgery simultaneously in 5 cases. In the other 2 cases ear surgery was done later, once the patient was stabilized.

One patient underwent modified radical mastoidectomy only, since he had cholesteatoma with early cerebritis. Success of the treatment was monitored through clinical signs & symptoms and CT scanning at 1<sup>st</sup>, 4<sup>th</sup> week and 3<sup>rd</sup> month. Antibiotics were given intravenously for 3weeks and orally for three months. Patients were followed for 6 months to 2 years.

## ORIGINAL ARTICLE

---

**RESULTS:** In our study, there were 5 (62.5%) males and 3 (37.5%) females. The age range was between 8 years and 51 years with mean age of 20.62 years. More than 60% were younger than 20 years of age. Headache and ear discharge were the commonest (100%) symptoms followed by vomiting (62.5%), seizures & vertigo (37.5%). Four months pregnant female and 9 yr old girl presented with drowsiness (25%) as shown in table 1.

The main findings in ear were cholesteatoma, granulations, and defects in dural plate and sinus plate, erosion of horizontal SCC and sigmoid sinus thrombosis. Other important findings were signs of meningeal irritation, focal neurological signs, hemiparesis, cerebellar signs and nystagmus as shown in table 2.

All patients underwent haematological investigations and CT scan with contrast. Six patients had temporal lobe abscess and 2 had cerebellar abscess (Fig.1 & Fig. 2). Of these, one child had early cerebritis changes in temporal lobe with facial nerve paresis (Fig 3). Abscesses with typical ring enhancement were found in other seven cases. All patients had changes of meningitis and 3 had sigmoid sinus thrombosis. Seven patients underwent neurosurgical intervention in the form of burr hole or craniotomy. Aspiration or excision of the abscess was done. One child with early cerebritis did not require neurosurgery. In 5 patients pus was sent for culture sensitivity.

Seven patients underwent modified radical mastoidectomy or radical mastoidectomy to clear the source of infection in ear. One female patient had ASOM with 4 months pregnancy. She had to undergo cortical mastoidectomy & burr hole and later MTP. Five patients underwent both neurosurgical & otological procedures simultaneously whereas 2 had to undergo mastoid exploration later once the condition was stabilised. Child with early cerebritis responded very well to mastoid exploration and antibiotics hence did not require neurosurgery.

There was no mortality in our study. One patient developed CSF otorrhoea on 6th postoperative day which was managed conservatively. Another patient developed grade 1 facial nerve paresis which resolved completely in 1 week. One child required repeated aspiration of abscess 3 times through the same burr hole.

**DISCUSSION:** Brain abscess is one of the life threatening complications of chronic suppurative otitis media particularly cholesteatoma.<sup>[7]</sup> Almost all patients in our study had cholesteatoma and presented with headache & vomiting, which is suggestive of intracranial complication.<sup>[8]</sup> The annual risk of developing brain abscess in CSOM is around 0.98 in 1000.

In our study, males were more affected than females. It was similar to other studies.<sup>[1,3]</sup> The incidence was more in 2<sup>nd</sup> decade of life.<sup>[3]</sup>

It is an important outcome in this study that lower socioeconomic status and poor health consciousness were the main causes of CSOM with complications. Therefore the incidence is significantly low in developed countries. The other important factors that contribute to intracranial complications are the virulence of organisms and immunity of host in addition to late and inadequate treatment.

Symptoms and signs vary according to the stage of brain abscess. In first stage (Encephalitic stage), symptoms are malaise, headache, fever and nausea which are mild. In second stage (Latent), the abscess localizes and acute symptoms abate. The third stage (Progressive) is associated with increased intra cranial tension and compression of specific structures in brain. The final stage is

## ORIGINAL ARTICLE

---

when the abscess ruptures into the ventricle or subarachnoid space resulting in rapid decline and ultimately to death.

Early diagnosis can be made by CT- scan with contrast. It is even used for monitoring the progress of treatment. It's usage has markedly reduced the morbidity and mortality of the complication. In addition to the site of abscess, it also detects the defects in tegmen and Trautman's triangle.<sup>[3,7]</sup> Temporal lobe and cerebellum are the two most common sites of OBA.<sup>[3,9]</sup>

Early diagnosis and treatment are essential to reduce the morbidity and mortality. The management includes medical treatment in the form of intravenous antibiotics, pressure reducing agents, steroids and symptomatic treatment as well as surgical intervention. The surgical approach in our study was simultaneous otological and neurosurgical intervention whenever possible. This combined approach reduces the anaesthetic risk, number of interventions and cost of treatment which is very important in poor & developing countries.

Out of 5 pus samples which were sent for culture and sensitivity, only two samples showed growth. Pseudomonas and Bacteroides fragilis were grown in those samples. Pseudomonas organism was sensitive only to Amikacin, Ceftriaxone and Imipenem. Bacteroides fragilis was a sensitive strain.<sup>[10,11]</sup>

There was no mortality in our study but mortality in other studies were ranging from 10-30%.<sup>[12]</sup> Many times OBA is associated with other intracranial complications like meningitis, sigmoid sinus thrombosis and extra or subdural abscess. Complications of surgery include CSF otorrhoea, facial nerve palsy and recurrence.

**CONCLUSION:** Otogenic brain abscess remains a life threatening complication of CSOM in particular cholesteatoma. It is more common in males and in 2nd decade of life. It needs be diagnosed early with high clinical suspicion and CT scan is the best diagnostic tool. The combination of surgical evacuation of abscess and cleansing of the source of infection from ear in single sitting is economically also effective.

### REFERENCES:

1. Osama U, Cureoglu S, Hosoglu S. The complications of chronic otitis media. *J laryngol Otol* 2000; 114: 97-100.
2. Hafidh MA, Keogh I, Walsh MC et al. Otogenic intracranial complications-A 7 year retrospective review. *Am J Otolaryngol Head Neck Med Surg* 2006; 7: 390-395.
3. Sennaroglu L, Sozeri B. Otogenic Brain Abscess: Review of 41 cases. *Otolaryngol Head Neck Surg* 2000; 123: 751-755.
4. Garcia BA, Varquez GE, Benito N et al. Brain Abscess-clinicomicrobiological study and prognostic analysis of 59 cases. *Rev Clin esp* 1998; 198: 413-9.
5. Deric D, Arsovic N, Dordevic V. Pathogenesis and methods of treatment of Otogenic Brain Abscess. *Med Pregl* 1998; 51(1-2): 51-5.
6. Arunbha S, Debasish G, Bijan B, Tarique A. Clinico-pathological study of Otogenic Brain Abscess. *Indian J Otolaryngol Head Neck Surg* 2009; 61: 291-96.
7. Kempf HG, Wiel J, Issing PR et al. Otogenic Brain Abscess. *Laryngorhinotology* 1998; 77: 462-6.
8. Nesic V, Janosevic L, Stojicic G, et al. Brain Abscess of Otogenic Origin. *Srp Arh Celok Lek* 2002; 130: 389-93.

## ORIGINAL ARTICLE

9. Levent S, Bulent S. Otogenic Brain Abscess. Otolaryngol Head & Neck Surg 2000, 123: 751-755.
10. Chen PT, Ho KY, Tui CF. Otogenic Brain Abscess- A case report. Kaahsiung J Med Sci 2000; 162-5.
11. O'Connor TE, Perry CF, Lannigan FJ. Complications of Otitis Media in indigenous & nonindigenous children. Med J Aust: 009; 191: 560-64.
12. Taran K, Niramon N, Suprennee F. Intracranial Complications of Suppurative Otitis Media -13 years-experience. Am J Otolaryngol; 16: 104-109.

Patient	Age (yrs)	Sex	Clinical Features
1	14	M	Headache, vomiting, ear discharge
2	15	M	Headache, ear discharge, seizure
3	28	F	Headache, seizure, drowsiness, 4mn amenorrhoea
4	8	M	FN palsy, ear discharge, headache, vomiting
5	15	F	Ear discharge, ear pain, headache, vertigo
6	25	M	Seizure, ear discharge, headache, vertigo
7	9	F	Drowsiness, ear discharge, headache, vomiting
8	51	M	Headache, ear discharge, ear pain, vertigo

**Table 1: Clinical data**

Patient	Otological Findings	Site Abscess	Treatment Modality
1	Cholesteatoma, dural plate erosion	Temporal lobe	SA
2	Cholesteatoma, trautman's triangle	Cerebellar	CA
3	Granulations in meso, epitympanum, coalescent mastoiditis, sigmoid sinus thrombosis	Temporal lobe	CA
4	Cholesteatoma, erosion of horizontal portion of fallopian canal	Early cerebritis in temporal lobe	Only MRM
5	Cholesteatoma, dural plate & lateral SCC erosion	Temporal lobe	CA
6	Cholesteatoma, sigmoid sinus thrombosis	Temporal lobe	SA
7	Cholesteatoma, sinus plate erosion, sigmoid sinus thrombosis	Cerebellar	CA
8	Cholesteatoma dural plate erosion	Temporal lobe	CA

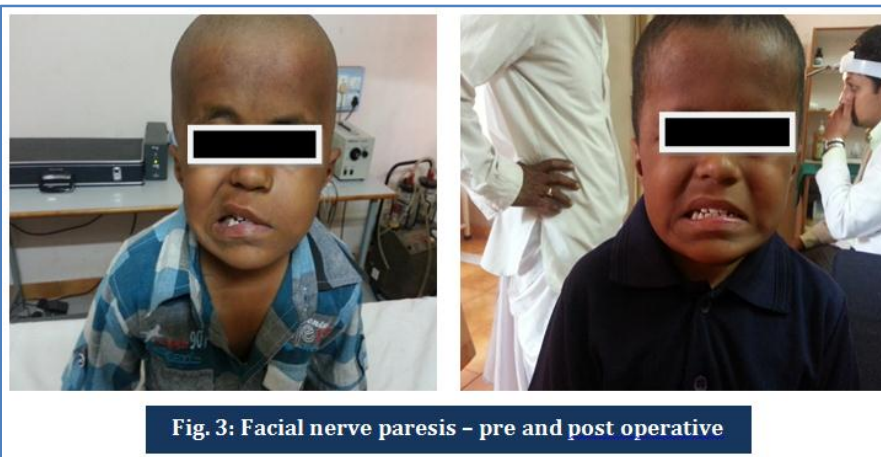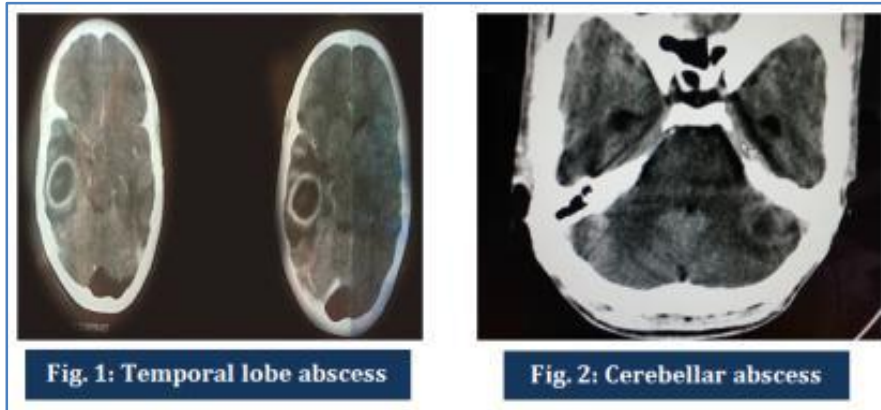
**Table 2: Operative findings and treatment modality**

CA- combined neurosurgery and ear surgery in one sitting.

SA-initially neurosurgery & ear surgery later.

MRM-modified radical mastoidectomy.

## ORIGINAL ARTICLE



### AUTHORS:

1. Shashidhar S. Suligavi
2. Shilpa Gokale
3. Pradeep Jain
4. S. S. Doddamani
5. M. N. Patil

### PARTICULARS OF CONTRIBUTORS:

1. Associate Professor, Department of ENT, SN Medical College & HSK & RC.
2. Assistant Professor, Department of Microbiology, SN Medical College & HSK & RC.
3. Consultant Neurosurgeon, Department of Neurology, Kerudi Hospital and RC.

### FINANCIAL OR OTHER

**COMPETING INTERESTS:** None

4. Professor, Department of ENT, SN Medical College & HSK & RC.
5. Assistant Professor, Department of ENT, SN Medical College & HSK & RC.

### NAME ADDRESS EMAIL ID OF THE CORRESPONDING AUTHOR:

Dr. Shashidhar S. Suligavi,  
# B-8, Staff Quarters, SNMC Campus,  
Navanagar, Bagalkot,  
Karnataka-587102  
E-mail: drshashient@gmail.com

Date of Submission: 19/01/2015.  
Date of Peer Review: 20/01/2015.  
Date of Acceptance: 04/02/2015.  
Date of Publishing: 10/02/2015.