DOI: 10.14260/jemds/2014/2907

ORIGINAL ARTICLE

PROFILE OF PAEDIATRIC PATIENTS WITH CERVICAL LYMPHADENOPATHY: A STUDY FROM CENTRAL INDIA

Jharna Mishra[1], M. Maheshwari[2], Roshan Chanchlani[3]

HOW TO CITE THIS ARTICLE:
Jharna Mishra, M. Maheshwari, Roshan Chanchlani. "Profile of Paediatric Patients with Cervical Lymphadenopathy: A Study from Central India". Journal of Evolution of Medical and Dental Sciences 2014; Vol. 3, Issue 27, July 07; Page: 7384-7388, DOI: 10.14260/jemds/2014/2907

ABSTRACT: INTRODUCTION: Cervical lymphadenopathy (CLA) is a common problem in clinical practice during childhood. Lymphadenopahy is the disease process of lymph nodes that render them abnormal in size and consistency. **AIM:** To determine the causes of persistent lymphadenopathy in pediatric patient and to test a diagnostic approach in its management. **METHODS:** This study was conducted at tertiary care hospital, over two year period amongst children between ages of 1-15 years with persistent lymph node enlargement of >1 cm in diameter and >2 weeks duration. **RESULTS:** 40(61.5%) had unilateral cervical lymph node enlargement, while in 25 children (38.5%) the pathology was bilateral. We found that in 35 children (53.8%) the lymph nodes regressed in size over 2 weeks' time and in 15 (23%) children, they regressed in 4 weeks' time as proved by ultrasonography examination. Fever was the commonest systemic manifestation in these children 80%, 7(10.7%) had lymph node abscess on initial presentation. **CONCLUSION:** Reactive lymphadenitis is the commonest cause of cervical lymph node enlargement in children. Majority of lymph nodes regress in 4 weeks' time. Persisting lymph nodes more than 4 weeks warrant histological examination. Tuberculosis is a common cause of cervical lymphadenopathy among Indian patients.

KEYWORDS: Lymphadenopathy, Lymph node, Lymphadenitis.

INTRODUCTION: Cervical lymphadenopathy (CLA) is a common problem in clinical practice during childhood.[1]Lymphadenopahy is the disease process of lymph nodes that render them abnormal in size and consistency. Common benign causes include adenoviral illness, infectious agents and tuberculosis whereas the malignancies causing generalized lymphadenopathy include leukemia, lymphoma or metastasis.[2]Lymphadenitis refers to lymphadenopathies that are due to inflammatory processes. It is characterized by nodal swelling, pain, skin changes, fever, edema and/or purulent collection.

In the pediatric age group, most lymphadenopathies are attributable to an infectious etiology, often viral in origin. Enlarged, palpable lymph nodes are common due to reactive hyperplasia of the lymphoid tissue.[3]Cervical lymphadenitis is a common pediatric problem and most patients with this condition are treated successfully by their primary care physicians. Histological examination and surgical consultation are, however, often required to assist in the diagnosis and treatment of patients who do not respond to initial therapy or in whom there is an index of suspicion for a neoplastic process.[4]

Though the frequency of the problem in children is high, few original studies on the issue were conducted. Most of the studies were conducted to define the causative agents. The aim of this study was to determine the most common causes of persistent cervical lymphadenopathy and the management strategy based on clinical, laboratory, ultrasonic and histological findings.

DOI: 10.14260/jemds/2014/2907

MATERIAL AND METHODS: This study was conducted over two year period from May 2012 to May 2014 in a tertiary care institute to evaluate children with persistent lymphadenopathy. Persistent lymphadenopathy was defined as enlarged lymph nodes (> 10 mm in diameter) and persisting for more than 2 weeks. The study included all children from 1 year to 15years of age with the diagnosis of persistent lymphadenopathy.

Demographic profile was noted and accompanying diseases of the patients were assessed. Initial work up of all patients included: detailed physical exam, complete blood count, blood film, erythrocyte sedimentation rate (ESR), purified protein derivative (PPD), chest X ray (CXR) and ultrasonic examination, histological testing by fine needle aspiration cytology (FNAC) or excisional biopsy were preserved for cases with abnormal findings (abnormal white blood cells (WBC) count; abnormal blood film; high ESR > 20 ml/hr; PPD > 10 mm.

RESULTS: A total of sixty five children between the ages of 1- 15 years assessed during the specified period of time. The age of patients ranged 1-5 years with a median of 7years and a mean of 4.8 ±2.3SD years. Males were 43 (66.1%) and females were 22(33.8%) All had persistent lymph node enlargement based on our previous definition. 40(61.5%) had unilateral cervical lymph node enlargement, while in 25 children (38.5%) the pathology was bilateral. (fig.1)

The jugular-digastric and the submandibular lymph nodes were the two most common enlarged nodes in 80% of children. Sub-mental, anterior cervical, posterior cervical, occipital accounted for the rest of the pathology (20%).

We found that in 35 children (53.8%) the lymph nodes regressed in size over 2 weeks' time and in 15(23%) children, they regressed in 4 weeks' time as proved by ultrasonography examination. The FNAC showed reactive lymphoid hyperplasia in these 15children (table no. 1). All of these children had tender, mobile, and soft nodes on clinical examination. In all of them complete blood count, blood film, ESR and CXRs were normal. Ultrasound showed enlarged lymph nodes with homogenous echotexture in all of them.

Fever was the commonest systemic manifestation in these children 80%, 7(10.7%) had lymph node abscess on initial presentation (table no. 2). Based on clinical and ultrasonic findings, surgical excision and histological testing confirmed the diagnosis; tuberculous lymphadenitis was diagnosed in 5 children (7.6%) based on clinical, PPD testing (>10 mm in diameter) and caseating granuloma on lymph node histology. (Fig. 2, 3) The ultrasound showed a non-homogenous echotexture with necrotic shadows and areas of calcification.

3(4.61%) of the children had bilateral lymph node enlargement and splenomegaly or Hodgkin´s lymphoma on excisional biopsy. These three children had high ESR on initial presentation, and their CXR's showed widened mediastinum with hilaradenopathy.

DISCUSSION: The workup of palpable lymph nodes is a common clinical task for the general practitioners and the pediatricians. Most of the causes of CLA are benign and may resolve spontaneously. It can be a sign of malignancy or systemic disease, thus understanding the differential causes is of paramount importance. Cervical lymphadenopathy is a common presentation in children in both the primary care and hospital setting. Park states that 90% of children aged 4-8 yrs have palpable cervical lymph nodes.[5]

According to Larsson et al 38- 45% of otherwise healthy children have palpable cervical lymph nodes.[6] The differential diagnosis of a persistent neck lump in children is different from adults because of increased incidence of congenital anomalies and infectious diseases and rarity of malignant disorder. In our study we excluded congenital anomalies and limited our research to persistently enlarged lymph nodes.

It is widely accepted that the absence of clinical signs of inflammatory disease, negative laboratory testing and progressive reduction of size of lymph node indicate reactive hyperplasia.[7] The study indicates that reactive inflammatory changes are the commonest pathology in children as confirmed by other studies. Our observation indicates also that most cases of lymphadenopathy are self-limited and require no treatment.

Failure of resolution after 4 weeks might be an indication for diagnostic histology. Most researches indicate that bilateral lymphadenopathy is more likely to be reactive in nature but our study cannot confirm that because in 61% of children enlargement was unilateral.[8]Mobility, softness and tenderness are almost always associated with reactive changes, which is similar to observation by other researchers.[9] We found that ultrasound is a valuable diagnostic tool for showing the size, shape and echotexture of lymph nodes.

A homogenous echotexture, oval shape, central necrosis, blurred margins were associated with reactive hyperplasia in most cases, while a non-homogenous echotexture suggests other diagnosis. Ultrasonography should not be considered as a definitive mean to rule out neoplasia in patients with persistent lymphadenopathy.[10]

CONCLUSION: Enlargement of cervical lymph nodes is a common problem in children. Reactive hyperplasia secondary to benign infectious causes is usually the commonest pathology. Most of these cases regress in 4 weeks' time. Persistent lymph nodes more than 4 weeks warrant histological examination done. A management strategy should be established to diagnose children with persistent lymph node enlargement.

REFERENCES:

1. Nield LS, Kamat D. Lymphadenopathy in Children: When and How to Evaluate. Clin Pediatr. 2004; 43: 25-33.
2. Friedmann AM. Evaluation and management of lymphadenopathy in children. Paediatr Rev 2008; 29: 53-60.
3. Luu TM, Chevalier I, Gauthier M, et al. Acute adenitis in children: Clinical course and factors predictive of surgical drainage. J Paediatr Child Health 2005; 14: 273-277.
4. Gosche JR, Vick L. Acute, subacute, and chronic cervical lymphadenitis in children. Sem in Pediatr Surg 2006; 15: 99- 106.
5. Srouji IA, Okpala N, Nelseen E, et al. Diagnostic cervical lymphadenectomy in children: a case for multidisciplinary assessment and formal management guidelines. Int J Paediatr Otolaryngol 2004; 68: 551- 556.
6. Niedzielska G, Kotowski M, Niedzielski A, et al. Cervical lymphadenopathy in children- Incidence and diagnostic management. Int J Paediatr Otolaryngol 2007; 71: 51- 56.
7. Song JY, Cheong HJ, Kee SY, et al. Disease spectrum of cervical lymphadenitis: Analysis based on ultrasound-guided core-needle gun biopsy. Journal of Infection 2007; 55: 310-316.

DOI: 10.14260/jemds/2014/2907

8. Nylen O, Berg K, Anderson B. Cervical lymph node infection with non-tuberculous mycobacteria in preschool children: interferon gamma deficiency as a possible cause of clinical infection. Acta Paediatr 2000; 89: 1322-1325.
9. Brown RL, Azizkhan RG. Pediatric head and neck lesions. Pediatr Clin North Am 1998; 45: 889-905.
10. Matsumoto F, et al. Biopsy of cervical lympnode Auris Nasus Larynx 2008; 1107.

Diagnosis	Number	Percentage
Reactive hyperplasia(Regressed in 2 wks)	35	53.84
Reactive hyperplasia(Regressed in 4 wks)	15	23.07
Lymph node abscess	7	10.76
TB lymphadenitis	5	07.69
Hodgkin's lymphoma	3	04.61
Total	**65**	**100**

Table no. 1: Diagnosis of persistent lymphadenopathy in children

Presenting symptoms	Number of children	Percentage
Fever	52	80.0
Neck mass	45	69.2
Cough	12	18.4
Loss of weight	15	23.0
Sore throat	21	32.3
Loss of appetite	08	12.3
Headache	05	07.6
Malaise	07	10.7
Arthralgia	15	23.0
Earache	03	04.6
Dental caries	03	04.6

Table no. 2: Distribution of the subjects according to the presenting symptoms

DOI: 10.14260/jemds/2014/2907



Fig. 1: Clinical photograph showing cervical lymphadenopathy

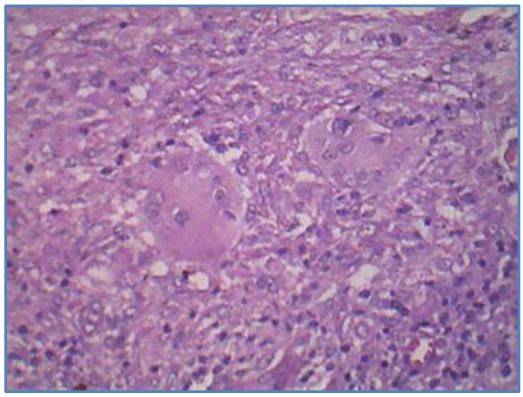

Fig. 2: Granulomatous Lymphadenitis

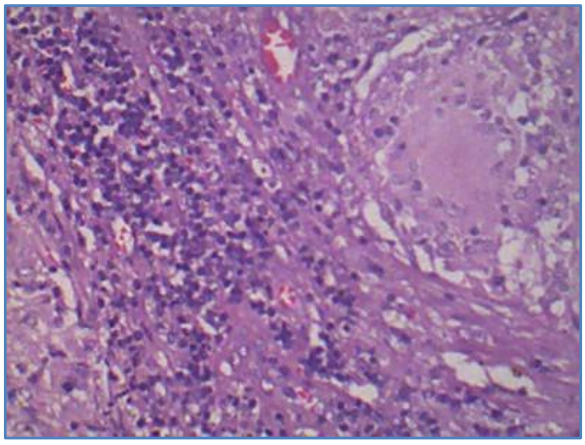

Fig. 3: Granulomatous Lymphadenitis showing Langhan's giant cell

AUTHORS:

1. Jharna Mishra
2. M. Maheshwari
3. Roshan Chanchlani

PARTICULARS OF CONTRIBUTORS:

1. Assistant Professor, Department of Pathology, Chirayu Medial College & Hospital, Bhopal.
2. Associate Professor, Department of Paediatrics, Peoples College of Medical Sciences, Bhopal
3. Associate Professor, Department of Surgery, Chirayu Medial College & Hospital, Bhopal.

NAME ADDRESS EMAIL ID OF THE CORRESPONDING AUTHOR:

Dr. Roshan Chanchlani,
#1/6-Idgah Kothi,
Doctors Enclave, Near Filter Plant,
Idgah Hills, Bhopal-462001, M. P.
Email: roshanchanchlani@gmail.com

Date of Submission: 18/06/2014.
Date of Peer Review: 19/06/2014.
Date of Acceptance: 26/06/2014.
Date of Publishing: 02/07/2014.