

ORIGINAL ARTICLE

COMPARATIVE STUDY OF EFFICACY OF INJECTION SCLEROTHERAPY VERSUS SURGERY AS PRIMARY MODALITY THERAPY IN PRIMARY VAGINAL HYDROCOELE: A RANDOMISED CONTROL STUDY

Jayakarthish Y¹, M. B. Patil²

HOW TO CITE THIS ARTICLE:

Jayakarthish Y, M. B. Patil. "Comparative Study of Efficacy of Injection Sclerotherapy versus Surgery as Primary Modality Therapy in Primary Vaginal Hydrocoele: A Randomised Control Study". Journal of Evolution of Medical and Dental Sciences 2015; Vol. 4, Issue 09, January 29; Page: 1405-1413, DOI: 10.14260/jemds/2015/198

ABSTRACT: CONTEXT (BACKGROUND): Primary/Idiopathic hydrocele is defined as an abnormal collection of serous fluid in tunica vaginalis whose cause is not known as it is neither associated with the disease of testis or epididymis. Surgery is considered as a definitive treatment, though the reason of injection treatment falling out of favour is ill understood as studies have shown this technique to be efficacious, safe, cost effective treatment modality in idiopathic hydroceles. This neglect, in part appears to be based on poor evidence presented by previous studies which show inconsistent results. Thus there appears to be lacunae in our knowledge with regards to the usage of aspiration-sclerotherapy as the first line of management in select patients. **AIM:** To compare the results of Injection Sclerotherapy and Surgery for the management of idiopathic hydrocele with respect to post procedure complications like pain, scrotal edema, wound infection, recurrence and the costs involved. **MATERIAL AND METHODS:** Patients presenting with primary vaginal hydrocele from May 2009-May 2012 were considered in the study. Diagnosis was ascertained by detailed history taking and clinical examination. Of the 60 Patients in the study, 30 each were randomly designated to treatment by surgery or aspiration-sclerotherapy. Sclerotherapy group were treated on an out-patient basis and those selected for surgery were treated after admission as in-patients. **STATISTICAL ANALYSIS USED:** Diagrammatic presentation, Mean +/- SD, Kruskal Wallis test, Chi square test. **RESULTS:** 70% cases undergoing sclerotherapy achieved primary cure. Among 30% recurrences, 13.33% achieved cure after 2nd session of sclerotherapy and 16.67% after 3rd session. Initial pain was more in sclerotherapy group whereas edema was more in Jaboulay's surgery group. All patients in sclerotherapy group were discharged on the same day while average duration of hospital stay was 6 days in surgery group. There was nearly 7 fold difference in the costs in favour of sclerotherapy. **CONCLUSIONS:** Sclerotherapy is highly effective, safe and economical procedure that permits one to avoid an operation, anesthesia and hospitalization in patients who are either not fit, don't desire for surgery. Its use is warranted in adults, particularly in elderly.

KEYWORDS: Sclerotherapy, Primary hydrocele, phenol.

INTRODUCTION: Primary vaginal hydrocele, one of the commonest diseases occurring worldwide, is defined as an abnormal collection of serous fluid in the tunica vaginalis. The scrotal swelling which worries the patient has led to various modalities of its treatment. Surgery has been the traditional treatment of choice for hydrocele which is simple and generally known. There is variety of procedures for hydroceles. The surgery commonly used for hydrocele is radical operation in which the parietal layer of tunica vaginalis is completely removed. However the surgery for hydrocele has a significant morbidity rate. The complications expected of surgery are hematoma, infection, scrotal edema, torsion testis, epididymitis or testicular atrophy. In addition there is associated risk of

ORIGINAL ARTICLE

anesthesia and an average hospital stay for 5 days and a time off work of minimum 2 weeks. These reasons apart, there is also an increasing incidence of surgical conditions which need attention on a priority basis necessitating diversion of the resources including time and personnel towards these conditions and thus away from less consequential conditions like primary hydrocele. Thus, there is a growing need to address such a situation by innovating/improvising alternate methods of treating this condition. The other methods of treatment described are tapping, sclerotherapy, fenestration technique,¹ silicon catheter technique.² The principles of sclerotherapy is not new but known since ancient times. Lander and Leonhardt have reported that surgeons in the past as long as the 13th century have used instillation of sugar and ginger to produce sclerosis of cystic lesions of the scrotum. Celsus attempted to cure using boiled water, milk, protein, alcohol, phenol, sodium chloride and glycerin. Since then many sclerosants have been tried like 2.5% phenol, portwine, quinine, urethane, 3% STDS, ethanalamine oleate, talc, antazoline, polidacanol and of late tetracycline with varied results. The reason injection treatment has fallen out of favour is not clear but such neglect appears to be based on poor evidence.³

METHODS: Selection of cases for the study was from the patients visiting the surgical OPD with primary vaginal hydrocele from May 2009 to May 2011 after obtaining clearance from the ethical committee. The details of the patient with regard to the age, address and contact number were taken and diagnosis of hydrocele was ascertained by detailed history taking and clinical examination. All primary hydroceles were included in the study. Patients with secondary hydrocele, any previous history of either surgery or aspiration for hydrocele were excluded from the study. The patients were then randomized to the surgery or sclerotherapy group by lottery method where in patients had to pick one from the 60 coupons numbered sequentially. Subsequently, those with even number were allotted to undergo surgery and those picking odd number were allotted for the sclerotherapy. Thus among a sample size of 60, 30 each were designated to either groups. Those selected for sclerotherapy were treated on an outpatient basis and those selected for surgery were admitted and operated. We used 3% phenol as the sclerosing agent. After prepping, bleb of skin was raised with a local anaesthetic after the assistant held the hemiscrotum following painting the area with povidone-iodine.

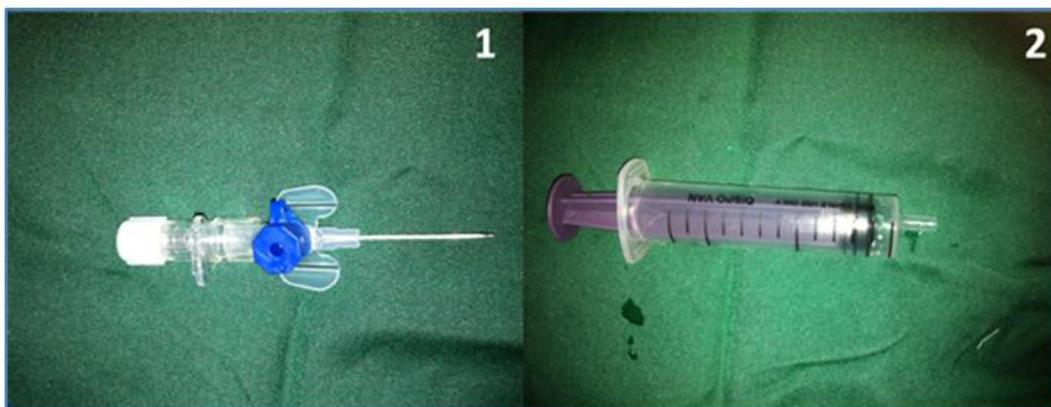


Fig. 1, 2: Instruments required for the procedure

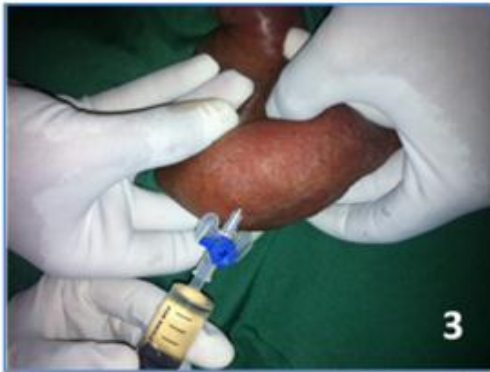

Fig. 3: Aspirating the hydrocele fluid till the sac was emptied

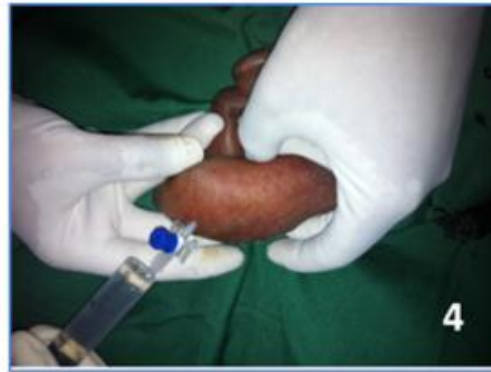

Figure 4: Injecting 3% phenol according to the volume aspirated through the same cannula kept in situ after aspiration

A cannula is inserted at the middle or upper part of the swelling and pushed well towards the other side of the swelling and held there so that, on tapping the fluid, the collapsing wall does not slip over the end of instrument. The sac was completely emptied by aspiration, volume measured and corresponding dosage of 3% phenol injected. Thus 5,10,15,20ml was injected for upto 50ml, 51-200ml, 201-400ml, more than 400ml hydrocele fluid aspirated. Patients were reviewed after every 6 weeks and the procedure repeated if need be until no fluid reaccumulated. All patients were given tight scrotal support and appropriate antibiotics and analgesics. In case of surgery, Jaboulay's procedure was done. Corrugated rubber drain when kept was removed after 48 hours. The sutures in most cases were removed between 6-12 days. In a few cases associated with partial dehiscence or discharge from wound sutures were removed between 12-14 days and the patients were hospitalized and observed till the wound healed. All cases of injection sclerotherapy were discharged 3 hours after the procedure. In our study of 60 cases, the youngest age was 19 years and 23 years in the sclerotherapy and surgery groups respectively. The mean age was 36 years and 40 years among those who underwent sclerotherapy and surgery respectively. Maximum incidence of hydrocele was found in 20-30yrs age group. Case with shortest duration of symptoms treated in the present study was 2 months and the longest was 15 years. Maximum number of cases had duration of symptoms between 1 to 4 years and minimum above 12 years. Statistical analyses was done using proper statistical tests like Diagrammatic presentation, Mean +/- SD, Kruskall Wallis test, Chi square test to infer the results

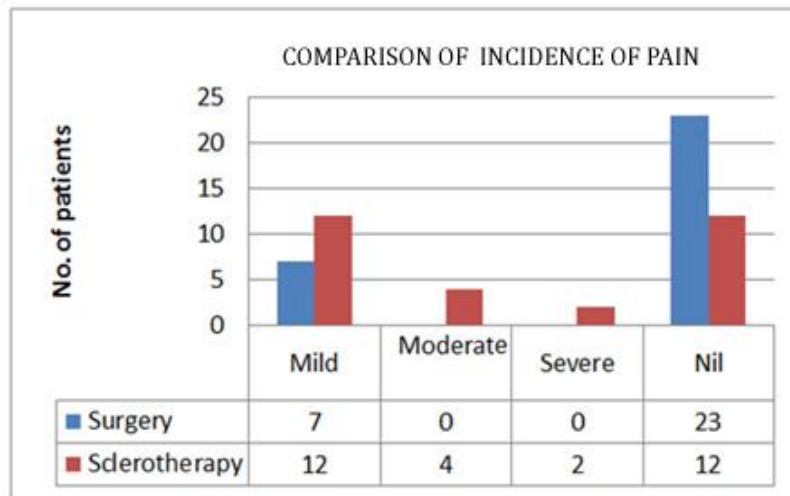
RESULTS:

Treatment modality	Duration of hospital stay (in days)
Jaboulay's	6
Injection sclerotherapy	0

Table 1: Comparison of duration of hospital stay

ORIGINAL ARTICLE

COMPARISON OF THE PAIN WITH RESPECT TO EACH TREATMENT MODALITY:

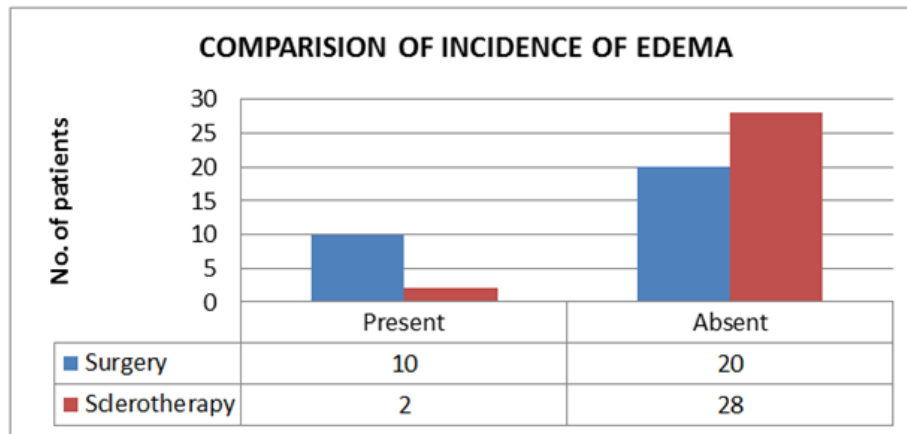


Graph 1

$$\chi^2=10.77; P= 0.013$$

There was statistically significant difference with regards to the degree of pain when the surgery and sclerotherapy were compared

COMPARISON OF THE SCROTAL EDEMA WITH RESPECT TO EACH TREATMENT MODALITY:



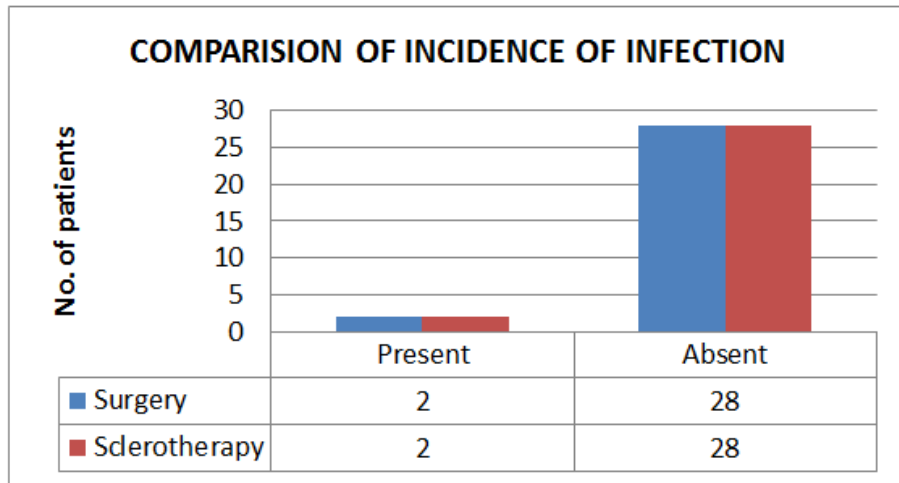
Graph 2

$$\chi^2=6.667; P= 0.010$$

There was statistically significant difference with regards to the incidence of edema post treatment when the surgery and sclerotherapy were compared with results favouring the sclerotherapy group.

ORIGINAL ARTICLE

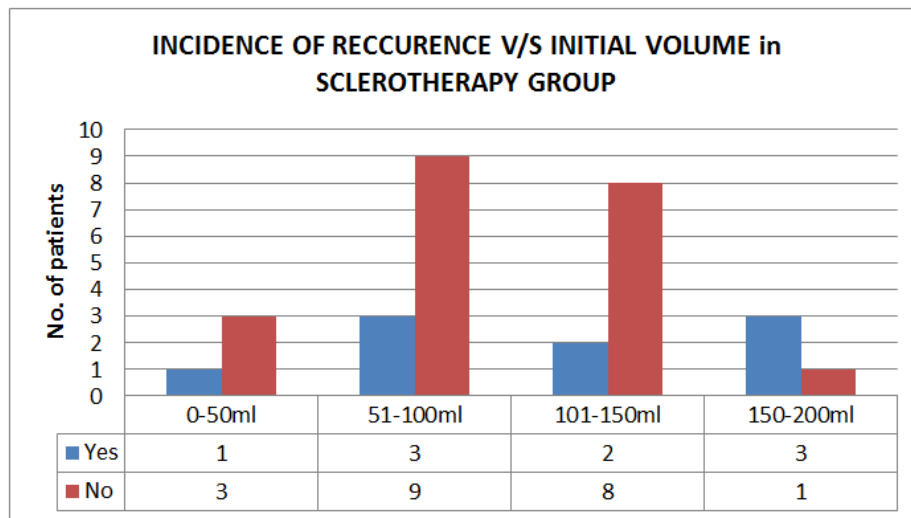
COMPARISON THE RATES OF INFECTION WITH RESPECT TO EACH TREATMENT MODALITY:



Graph 3

$P > 0.05$; No significant difference in the incidence of infection with either groups was found.

COMPARISON OF INCIDENCE OF RECCURENCE WITH INITIAL VOLUME IN THE SCLEROTHERAPY GROUP:

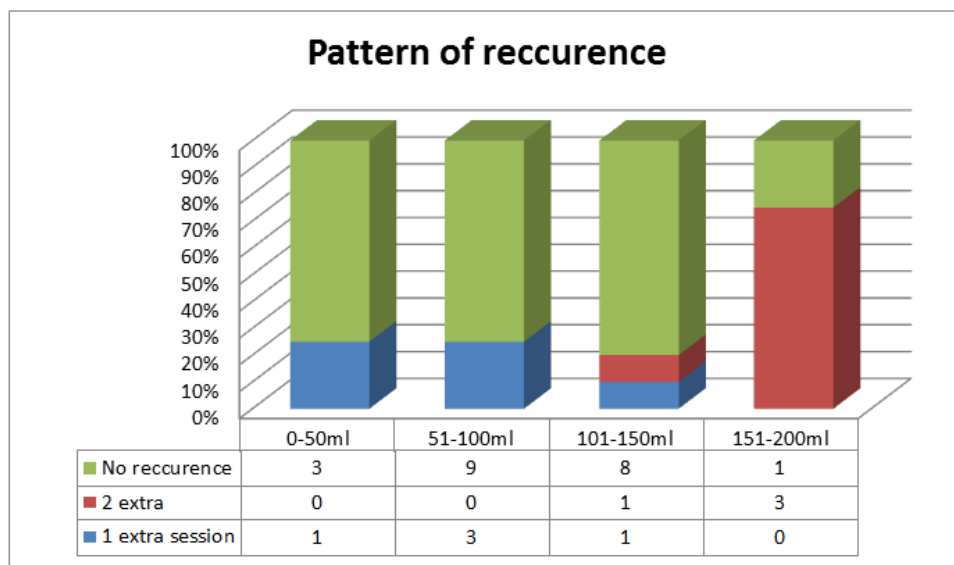


Graph 4

$\chi^2 = 4.5238$; $P = 0.210$.

Thus, there is no association between the initial volume of the hydrocele sac and the recurrence.

RECURRENCE PATTERNS:



Graph 5

Out of the 30 patients treated with sclerotherapy, primary cure was seen in 21 cases (70%) and 9 patients had recurrences. Of the 9 patients, cure was achieved with 2nd session of sclerotherapy in 4(13.33%) patients. 5 of the 9(16.67%) patients required another extra session of sclerotherapy. This pattern indicates that though the recurrence was not associated with the initial volume of the hydrocele, when it did recur the one with larger initial volume required multiple sessions of sclerotherapy.

	Surgery	Sclerotherapy
Drugs	960	150
OT charges	525	100
Total	1485	250

Table 2: Comparison of the expenditure

Thus there was 6 fold increases in cost in the Jaboulay's group when compared to sclerotherapy.

DISCUSSION: Nearly 2500 years ago, Sushruta had first described about the treatment of hydrocele as "vyadhana" in his famous book Sushruthasamhita wherein he used a special instrument for draining the fluid. Though surgery is the gold standard in the management of hydrocele, it is not without complications like postoperative hematoma, scrotal edema, and pain. It is commonly described in teachings that "he comes with a size of a cricket ball and goes back with a coconut" to emphasize the importance of scrotal edema post operatively. Recent reports on sclerotherapy have promoted many to study the role of sclerotherapy in the management of hydrocele. This study dispels the fears associated with sclerotherapy by providing evidence supporting the validity of the procedure in the current times in select patients. There have been studies regarding the poor success

ORIGINAL ARTICLE

rates associated with the procedure when compared to the surgery⁴. In our study, only 30 % (9 out of 30) required multiple sessions of sclerotherapy (5/9 requiring 2 and 4/9 requiring 3 sessions) at the end of which there was no further recurrence. We have also not had any of the severe complications like intense inflammatory reactions necessitating orchidectomy or gangrene of the scrotal skin^{5,6}. The sclerosant that we have used is 3% phenol. In our study, there was no association between size of the hydrocele at presentation and the recurrence, though there was a trend towards the need of multiple treatment sessions in those patients presenting with recurrence with a higher initial volume of hydrocele. Some of the commonly used sclerosants for hydrocele are phenol, polidocanol, tetracyclines, OK432 to name a few.

Savion M et al⁷ in their study of 63 hydroceles with 2.5% phenol achieved cure in 51.6%, 25.8%, 13%, 8% of the patients with 1,2,3,4 treatment sessions respectively. One of their patients required 7 injections and in one it was unsuccessful because of local allergic reaction. In our study we achieved 70%, 13.33% and 16.67% cure rate in 1, 2 and 3 treatment sessions respectively. Shan et al⁸ used phenol as the sclerosant in their study where they compared sclerotherapy and surgery with respect to efficacy, side effects and effects on spermatogenesis and concluded that phenol is as efficacious as surgery and caused less morbidity. The effect on spermatogenesis was also similar in both the groups as evidenced by semen analysis pre and post procedures.

Ozdeimer⁹ used 3% phenol as the sclerosant in his study wherein neither anaesthetics nor antibiotic prophylaxis was used. They concluded that sclerotherapy with 3% phenol is an effective, economical and safe form of therapy for patients with hydrocele.

Francis JJ¹⁰ et al used doxycycline as the sclerosant and achieved cure in 84% (27 of 32 hydroceles) after a single session of sclerotherapy. One patient preferred surgery after recurrence while one more patient achieved cure after 2nd session. The remaining patients had recurrence after 2nd session and underwent hydrocelectomy. In our study, none of the patients underwent surgery in view of repeated recurrence or complications in the sclerotherapy group. Musa et al¹¹ in their study using tetracycline as the sclerosant reported an overall cure rate of 95%. Pain was encountered in 10%, 12% had local infections and 5% developed hematoma. Recurrence was seen in 4 patients with thick-walled hydroceles. In the surgical group, there were no recurrence, 25% incidence of infection and 7% incidence of hematoma. The mean hospital stay for the surgical group was 3.4 +/- 1.3 days (range 1-7).

East JM et al¹² compared 5% phenol with tetracycline as sclerosant in their study and achieved similar cure rates in both groups (83% and 81% respectively, $p = 0.8$) with similar mean number of injections to cure (1.34 and 1.12 respectively, $p = 0.069$), with range 1-4 and 1-3 respectively. Severe pain following tetracycline injection required administration of pre-injection cord block. They had one case of chronic haematocele treated by orchietomy in the tetracycline group. The authors concluded that both sclerosants are equally efficacious and added a word of caution regarding post-treatment fertility as in surgery thus reiterating the need of informed consent for both modalities. With the technique that we followed in our study as described, we did not encounter any case requiring orchietomy for complications nor was there a need of pre-injection cord blocks.

Lund et al¹³ used polidocanol as the sclerosant in their study wherein they had a recurrence rate of 44%. 25% of these recurrences required a 3rd session of sclerotherapy. Jahnson S et al¹⁴ in their study on hydroceles and spermatoceles reported 94% satisfactory results after 1 to 4

ORIGINAL ARTICLE

treatments using polidocanol and they also concluded that dose of 4 ml was superior to 2 ml, particularly for larger hydroceles/spermatoceles. Sallami S et al¹⁵ reported a cure rate of hydroceles after one sclerotherapy session was 62.1% and the overall cure rate using the procedure was 82.6%. Re-instillation was done for recurrences in 41% of patients. Polidocanol therapy was almost pain-free. A low rate of complications was observed. Andersen M et al¹⁶ in their study with polidocanol found that in 24 of the 30 treatments there were no sign of relapse. In three cases the patient had noticed a small relapse, but had no pain. Three were treated with surgery.

There has been a study reporting the success achieved using OK-432 (group A *Streptococcus pyogenes* of human origin) as the sclerosant. 18 out of 20 required only one injection and the other 2 requiring another one for achieving cure. The side effects they have noted were the local inflammatory reaction and fever of 2-3 days¹⁷.

Thus from the above studies it is clear that the sclerotherapy is a lesser invasive option of treating primary hydrocele which is done under local anesthesia, requiring shorter hospital stay, not associated with significant edema, associated with more pain compared to surgery in the immediate post-operative period. The probabilities of patient requiring multiple treatment sessions and surgery in the event of repeated recurrence or complication must be explained to the patient in clear terms before the procedure. Strict adherence to techniques has resulted in improved results.

CONCLUSIONS: Sclerotherapy when performed in the right technique is highly effective, safe and economical procedure that permits one to possibly avoid an operation, anesthesia and hospitalization and can be used as a treatment option in patients who are either not fit or do not desire for surgery. Its use is warranted in adults, particularly in the elderly.

REFERENCES:

1. Tariel E, Mongiat-Artus P. Treatment of adult hydrocele. *Ann Urol (Paris)*. 2004 Aug; 38 (4): 180-5.
2. Arslan M, Kilinc M, Yilmaz K, Ozturk A. A new approach in the management of the hydrocele with a silicone catheter. *Urology*. 2004 Jan; 63 (1): 170-3.
3. Nash JR. Sclerotherapy for hydrocele and epididymal cysts: a five year study. *Br Med J (Clin Res Ed)*. Jun 2, 1984; 288 (6431): 1652.
4. Khaniya S, Agarwal CS, Koirala R, Regmi R, Adhikary S. Comparison of aspiration-sclerotherapy with hydrocelectomy in the management of hydrocele: a prospective randomized study. *Int J Surg*. 2009 Aug; 7 (4): 392-5.
5. Stattin P, Karlber L, Damber JE. Long-term outcome of patients treated for hydrocele with the sclerosant agent sodium tetradecyl sulphate. *Scand J Urol Nephrol*. 1996 Apr; 30 (2): 109-13.
6. Dahl BH. Partial gangrene of the scrotum and penis. A complication of sclerotherapy of testicular hydrocele. *Tidsskr Nor Laegeforen*. 1993 Apr 20; 113 (10): 1232.
7. Savion M, Wolloch Y, Savir A. Phenol sclerotherapy for hydrocele: a study in 55 patients. *J Urol*. 1989 Dec; 142 (6): 1500-1.
8. Shan CJ, Lucon AM, Arap S. Comparative study of sclerotherapy with phenol and surgical treatment for hydrocele. *J Urol*. 2003 Mar; 169 (3): 1056-9.
9. Ozdemir E. Sclerotherapy of testicular hydroceles with 3% aqueous phenol. *Hinyokika Kyo*. 1996 Jun; 42 (6): 427-32.

ORIGINAL ARTICLE

10. Francis JJ, Levine LA. Aspiration and sclerotherapy: a nonsurgical treatment option for hydroceles. *J Urol.* 2013 May; 189 (5): 1725-9.
11. Musa MT, Fahal AH, el Arabi YE. Aspiration sclerotherapy for hydroceles in the tropics. *Br J Urol.* 1995 Oct; 76 (4): 488-90.
12. East JM, Du Quesnay D. Sclerotherapy of idiopathic hydroceles and epididymal cysts: a historical comparison trial of 5% phenol versus tetracycline. *West Indian Med J.* 2007 Dec; 56 (6): 520-5.
13. Lund L, Kloster A, Cao T. The long-term efficacy of hydrocele treatment with aspiration and sclerotherapy with polidocanol compared to placebo: a prospective, double-blind, randomized study. *J Urol.* 2014 May; 191 (5): 1347-50.
14. Jahanson S, Sandblom D, Holmang S. A randomized trial comparing 2 doses of polidocanol sclerotherapy for hydrocele or spermatocele. *J Urol.* 2011 Oct; 186 (4): 1319-23.
15. Sallami S, Binous MY, Ben Rhouma S, Chelif M, Hmidi M, Nouira Y, Ben Rais N, Horchani A. Sclerotherapy of idiopathic hydrocele with polidocanol: a study about 190 cases. *Tunis Med.* 2011 May; 89 (5): 440-4.
16. Andersen M, Bentsen G. Sclerotherapy of spermatoceles and hydroceles. Long term results of polidocanol use. *Tidsskr Nor Laegeforen.* 1993 Oct 20; 113 (25): 3146-7.
17. Yamamoto M, Hibi H, Miyake K. A new sclerosant therapy for testicular hydrocele with aspiration and injection of OK-432. *Int Urol Nephrol.* 1994; 26 (2): 205-8

AUTHORS:

1. Jayakarthish Y.
2. M. B. Patil

PARTICULARS OF CONTRIBUTORS:

1. Assistant Professor, Department of Surgery, SBV University's, Mahatma Gandhi Medical College and Research Institute.
2. Professor, Department of Surgery, BLDEU's Shri B. M. Patil Medical College.

NAME ADDRESS EMAIL ID OF THE CORRESPONDING AUTHOR:

Dr. Jayakarthish Y,
 # 1A, Type 1 Quarters,
 MGMCRI Campus, Pillaiyarkuppam,
 Pondicherry-607402.
 E-mail: yjk51085@gmail.com

Date of Submission: 14/01/2015.
 Date of Peer Review: 16/01/2015.
 Date of Acceptance: 19/01/2015.
 Date of Publishing: 27/01/2015.