

CASE REPORT

PREGNANCY OUTCOME AFTER MITRAL VALVE REPLACEMENT: A CASE REPORT

Sunanda N¹, Sudha R², Asha M. B³

HOW TO CITE THIS ARTICLE:

Sunanda N, Sudha R, Asha M. B. "Pregnancy Outcome after Mitral Valve Replacement: A Case Report". Journal of Evolution of Medical and Dental Sciences 2014; Vol. 3, Issue 31, July 31; Page: 8631-8636, DOI: 10.14260/jemds/2014/3098

ABSTRACT: Cardiac disorders in pregnancy poses special challenges to health care providers. Complications may arise at any stage due to increased hemodynamic load imposed by pregnancy or because of impaired cardiac performance often seen in these patients. There is an increased risk of thromboembolism, anticoagulant related hemorrhage, fetal wastage, congestive cardiac failure in pregnant women with mechanical heart valve. Pregnancy in such patients is a high risk venture. In order to have good outcome, the care of such patients must involve multi-disciplinary approach and should be done in a well-equipped centre with adequate support system.

KEYWORDS: Mitral valve replacement, pregnancy.

INTRODUCTION: The management of a pregnant woman with a prosthetic heart valve requires important considerations, especially when it comes to maintaining anticoagulants. The treatment of women in child bearing age with a mechanical heart valve is a real challenge for the medical staff.¹

Warfarin is considered to be a safe and effective anticoagulant for patients with prosthetic heart valves. However, treatment during pregnancy poses many difficulties, more during the first trimester, due to the ability of warfarin to cross the placenta and its associated fetotoxicity.²

Treatment with Heparin during the first trimester decreases the rate of embryopathy, but increases maternal morbidity and mortality. In general, the risk of thromboembolism is greater for older generation prosthetic valves in the mitral position, such as the Bjork-Shiley tilting-disc prosthesis as compared with the St. Jude valve.³

The risk of thromboembolism, miscarriage, and premature birth is felt to be higher in patients who have prosthetic heart valves requiring anticoagulation. Thus pregnancy in women with prosthetic mechanical heart valve replacement is problematic and troublesome since it leads to maternal mortality rate of 3 to 4%.⁴

CASE REPORT: A 22 yrs. old primigravida with 37 wks gestation was referred from a primary health center for Rheumatic heart disease-post mitral valve replacement for safe confinement. She conceived spontaneously and pregnancy was confirmed at nearby Primary Health Center. She had frequent visits to cardiologist also.

Patient had leg & hip joint pain and headache for which she was evaluated and diagnosed to be case of Rheumatic heart disease- severe Mitral regurgitation, infective endocarditis complicated by right common iliac artery aneurysm. Patient underwent surgery for both at different setting. Right common iliac artery aneurysm excision done in December, 2008 and mitral valve replacement done a month later using St Jude valve 27- mechanical valve. Since then she is on tablet Warfarin 3mg/4mg, once a day alternate day and penidure prophylaxis. When pregnancy was confirmed her medication was changed to inj. Heparin 5000 IU with weekly aPTT/ PT monitoring and titrating the dose

CASE REPORT

accordingly. INR was maintained at >2. Before admission she was taking inj. Heparin 3500IU thrice daily.

On examination, patient was comfortable and belonged to NYHA (New York heart association) grade 1. She had a vertical scar in the mediastinum extending from the xiphisterum to 7cm below the suprasternal notch. Pulmonary area had a palpable P2, and systolic thrill. Prosthetic valve click was heard in the mitral area with an ejection systolic murmur in pulmonary area indicating pulmonary hypertension. Obstetric examination revealed a term relaxed uterus.

On admission patient was ordered a 2D echo which revealed normal functioning mitral valve prosthesis with no valvular or paravalvular leak, normal Left Ventricular function with ejection fraction of 65%. No obvious clots/ vegetation was detected however, mild mitral regurgitation was present. USG showed single live intrauterine gestation of 19 weeks with no obvious anomalies. Fetal echocardiography was done considering the risks, which was found to be normal. Coagulation profile was within normal limits.

Further management was planned after consulting the cardiologist who advised to increase the dose of inj heparin to 4000 IU BD and to Continue heparin up to onset of labor. Heparin was to be stopped 6hrs prior to elective LSCS/induction. Post-delivery after ensuring hemostasis, warfarin was to be restarted at 2mg OD overlapping with heparin. Activated PTT and INR to be kept at 1.5-2 times the control value. After INR Value is achieved heparin was advised to be stopped.

A reserve of blood components (FFP's, platelets, PRBC) was kept and infective endocarditis prophylaxis given. On 08/04/2014 patient set into labor spontaneously. Patient had a vacuum assisted vaginal delivery of an alive male baby of weight 2.75kg at 5:50pm.

Intrapartum and postnatal period was uneventful. Activated PTT was monitored during labor and in post natal period. Inj heparin was restarted 6hours after delivery and overlapped with tab. Warfarin 3mg OD at the time of discharge.

DISCUSSION: Surgical valve replacement has allowed many patients with severe valvular heart disease to survive and lead near normal life. There are 2 broad categories of replacement valves each with advantage and disadvantages: Mechanical valve and Bioprosthetic valve. Further they are divided into:

Heterograft- bovine or porcine valve.

Homograft- human aortic valve.

Autograft- patients own pulmonary valve.

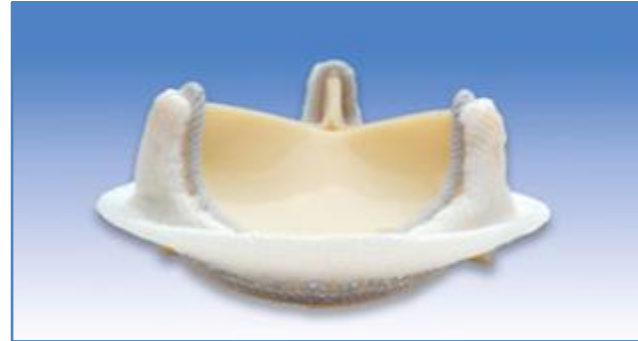
Mechanical valve are non-biological material.^{5,6,7} They have advantage of durability but risk of thrombosis requires long term anticoagulant.

Bioprosthetic valves do not require anticoagulant but valve failure often occurs within 10-15years.^{8,9,10} Pregnancy has been reported to increase the rate of spontaneous valve deterioration.

CASE REPORT



St JUDE MECHANICAL VALVE



**EDWARD BOVINE PORCINE
BIOPROSTHETIC VALVE**

All mechanical prosthetic valves are thrombogenic and require life-long anticoagulation to prevent thromboembolic complications.

In addition, pregnancy is a hypercoagulable state.¹¹ choosing which type of anticoagulation to use during pregnancy is problematic, as there is no perfect choice from the available data.

OUTCOME	MECHANICAL (N=178)	BIOPROSTHETIC (N=73)	HOMOGRAFT (N=72)
10YEARS SURVIVAL (%)	70	84	96
THROMBOTIC COMPLICATION (%)	45	13	1
BLEEDING COMPLICATION (%)	15	4	
10 YEARSVALVEREPLACEMENT	29	82	28

Comparison of outcomes associated with mechanical and prosthetic valves in young women

Therefore, the major concerns associated with pregnant women with mechanical heart valves are thromboembolic complications, maternal bleeding, and increased fetal events.^{12,13,14} The use of Warfarin in pregnant women during the first trimester resulted in a high rate of abortion (34.9%). A similar incidence of abortion was found by Salazar and associates (37.5%) and Shannon et al., who reported a 37% rate of abortion.¹⁵

In contrast, in the Akhtar et al. study, spontaneous abortion occurred more frequently in the Heparin group, whereas Geelani and colleagues reported a similar incidence of abortion in Warfarin and Heparin groups. Many articles have shown that the use of Warfarin between 6 and 12 weeks' gestational age results in a 6% to 10% risk of embryopathy.

The risk is probably lower if ≤ 5 mg of Warfarin is prescribed. A large number of studies have reported that the risk of thromboembolic events during pregnancy in patients treated with Heparin is approximately 10%, compared with a 3.9% risk with the use of Warfarin throughout pregnancy. The use of unfractionated Heparin during pregnancy can be problematic, with an attenuated response of

CASE REPORT

activated partial thromboplastin time, variable sensitivities of aPPT reagents, and wide peaks or troughs with the use of subcutaneous unfractionated heparin.

Most studies have found that the risk of thromboembolic complications is greater with prosthetic valves in the mitral valve position than with those in the aortic position. As regards the maternal outcome, it is deserving of note that the Warfarin regimen is safer than Heparin.

REGIMEN	DOSING	MONITORING	THERAPEUTIC GOAL
LMWH THROUGHOUT PREGNANCY	Begin with 1mg/kg enoxaparin 12 th hourly	Anti factor Xa level 4 hour after dose	Manufacturers upper therapeutic range
UFH THROUGHOUT PREGNANCY	Begin at 17500 to 20000 U 12 th hourly	aPTT or anti factor Xa level 4 to 6 hours after dose	.>2 times control 0.35 to.70 U/mL
LMWH OR UFH THROUGH 13 WKS AND AFTER 36 WKS; WARFARIN FROM 14 -36wks	Heparin 12 th hourly Warfarin daily	As above for heparin INR	As above for Heparin 2.5-3.5
ASPIRIN added to all above	75- 100 mg daily	None	None
ANTICOAGULANT DOSING			

UFH: unfractionated heparin

LMWH: low molecular weight heparin

CONCLUSION: Women who have prosthetic heart valves and are of a childbearing age should be counselled (ideally before conception) about the potential issues that might arise during pregnancy. Having a prosthetic heart valve puts both the mother and fetus at risk; therefore, the management of these women is required throughout pregnancy in a specialized program for high-risk patients by a multi-disciplinary team.

REFERENCES:

1. Marcus-Braun N, Segal D, Merkin M, wiziter A, Katz M, Tager S, Llya R, Mazor M. Anticoagulation in pregnant women with prosthetic heart valve – a new approach for therapy. Harefuah 2003; 142: 508-511.
2. Grunkemeier GL, Starr A, Rahimtoola SH. Clinical performance of prosthetic heart valves. In: Fuster V, Alexander RW, O'Rourke RA, Eds. The Heart. 10th Ed. New York: McGraw-Hill; 2001. p. 1759-1774.
3. Bron D, Martines EE, Almeida PA, Santos DV, Carvalho AC, Moron AF, Miyasaki CH, Moraes SD, Ambrose JA. Pregnancy in patient with prosthetic heart valves the effect of anticoagulation on mother, fetus and neonatal. Am Heart J 1992;124:413-417.
4. Elkayam U, Bitar F. Valvular heart disease and pregnancy: part II: prosthetic valves. J Am Coll Cardiol 2005;46:403-410.

CASE REPORT

5. Salazar E, Izaguirre R, Verdejo J, Mutchinick O. Failure of adjusted doses of subcutaneous heparin to prevent thromboembolic phenomenon in pregnant patients with mechanical cardiac valve prostheses. *J Am Coll Cardiol* 1996 22:1698-1703.
6. Shannon MS, Edwards MB, Long F, Taylor KM, Bagger JP, De Swiet M. Anticoagulant management of pregnancy following heart valve replacement in the United Kingdom 1986-2002. *J Heart Valve Dis* 2008 17:526-532.
7. Geelani MA, Singh S, Verma A, Nagesh A, Betigeri V, Nigam M. Anticoagulation in patients with mechanical valves during pregnancy. *Asian Cardiovasc Thorac Ann* 2005;13:30-33.
8. Maxwell C, Sermer M. Mechanical heart valves and pregnancy. *Fetal Matern Med Rev* 2007;18:311-331.
9. Maxwell CV, Poppas A, Dunn E, Sermer M. Pregnancy, mechanical heart valves and anticoagulation: navigating the complexities of management during gestation. In: Rosene-Montella K, Keely EJ, Barbour LA, Lee RV, eds. *Medical Care of the Pregnant Patient*. 2nd ed. Philadelphia: American College of Physicians; 2007. p.344-355.
10. Vitale N, De Feo M, De Santo LS, Pollice A, Tedesco N, Cotrufo M. Dose-dependent fetal complications of warfarin in pregnant women with mechanical heart valves. *J Am Coll Cardiol* 1999;33:1637-1641.
11. Khamooshi AJ, Kashfi F, Hosseini S, Tabatabaei MB, Javadpour H, Noohi F. Anticoagulation for prosthetic heart valves in pregnancy. Is there an answer? *Asian Cardiovasc Thorac Ann* 2007;15:493-496.
12. Khamoushi AJ, Kashfi F, Hosseini S, Alizadeh Ghavidel AR, Samiei N, Haddadzadeh M. Anticoagulation During Pregnancy in women with mechanical heart valves: a prospective study. *IJFS* 2011;5:47-51.
13. Warnes CA. Prosthetic heart valves. In: Steer PJ, Gatzoulis MA, Baker P, eds. *Heart Disease and Pregnancy*. London: RCOG Press; 2006. p.157-168.
14. American college of cardiology/American heart association. Task force on practical guidelines; society of cardiovascular anaesthesiologists; society for cardiovascular angiography and interventions; society of thoracic surgeons, Bonow RO, Carabello BA, Kanuc, deLeon AC Jr, Faxon DP et al 2006 guidelines Further guidelines for the management of patients with valvular heart disease: A report of ACOC/American Heart Association Task Force on Practice Guidelines(writing committee to revise the 1998 guidelines for the management of patients of valvular heart disease):developed in collaboration with the society of cardiovascular angiography and interventions and the society of thoracic surgeons. *Circulation* 2006; 114:e84-231.
15. Vitale N, DeFeo M, De Santo LS, Pollice A, Tedesco N, Cotrufo M. Dose dependant fetal complications of warfarin in pregnant women with mechanical heart valves. *J Am Coll Cardiol* 1999;33:1637-1641

CASE REPORT

AUTHORS:

1. Sunanda N.
2. Sudha R.
3. Asha M. B.

PARTICULARS OF CONTRIBUTORS:

1. Assistant Professor, Department of Obstetrics and Gynaecology, Mysore Medical College and Research Institute, Cheluvamba Hospital.
2. Associate Professor, Department of Obstetrics and Gynaecology, Mysore Medical College and Research Institute, Cheluvamba Hospital.
3. Post Graduate, Department of Obstetrics and Gynaecology, Mysore Medical College and Research Institute, Cheluvamba Hospital.

NAME ADDRESS EMAIL ID OF THE CORRESPONDING AUTHOR:

Dr. Sunanda N,
No. 1312, 5th Cross,
Paduvana Road,
Kuvempunagar,
Mysore-570023.

Email: sunanda_n@rediffmail.com

Date of Submission: 11/07/2014.

Date of Peer Review: 12/07/2014.

Date of Acceptance: 24/07/2014.

Date of Publishing: 30/07/2014.