

CASE REPORT

A RARE PRESENTATION OF A FOREIGN BODY IN VAGINA (WOOD APPLE)

B. Venkateswara Rao¹

HOW TO CITE THIS ARTICLE:

B. Venkateswara Rao. "A Rare Presentation of a Foreign Body in Vagina (Wood Apple)". Journal of Evolution of Medical and Dental Sciences 2014; Vol. 3, Issue 13, March 31; Page: 3321-3323, DOI: 10.14260/jemds/2014/2287

INTRODUCTION: A very rare interesting presentation of a woman attending our medical out-patient department with decreased urinary output and investigated for renal problem. Later found to be a case of foreign body (wood apple) in the vagina. It is a rare presentation now a day^{1,2}. Our hospital is a rural based, 500 bedded teaching hospital attached to a Government Medical College at Anantapuramu, Andhra Pradesh.

KEYWORDS: Foreign body; Wood apple; Vagina.

CASE REPORT: A 50 year old post-menopausal woman from a near-by tribal village was admitted in the medical outpatient department in our hospital with a history of decreased urinary output since 1 week, fever since 1 week, abdominal pain 1 month, difficulty in passing urine since 1 month and white discharge since 1 month. She was evaluated for the renal problem. USG shows Hydronephrosis. As a routine case the patient was sent to the gynecology OP for white discharge.

In the gynecology OP she was examined for white discharge. General examination shows no pallor. Per abdomen-no masses palpable. Inspection of the genitalia shows foul smelling white discharge. Per speculum shows a hard mass in the vagina with a foul smelling white discharge. The patient denied of anything kept in the vagina. On further history taking she gives a history of something kept in the vagina for prolapse of the uterus 2 years back by a local quack. She was shifted to the gynecology ward for further management.

The following investigations were done. Hb-9.5gms%, Blood group-O+ve, Blood sugar - 105 mgs, Blood Urea - 28 mgs, USG shows a circumscribed mass with thick wall in the vagina. Broad spectrum antibiotics were given and vaginal douching was done for 3 days.

The patient was posted for examination and removal in the OT under spinal anesthesia. On vaginal examination there was a hard mass of about 10-12cms found jammed in the vagina (fig. 1). The same was tried to remove with the hand but could not be removed. Later the mass was held with a vulsellum and delivered out (fig. 2). The vagina and cervix appears congested. There was no descent of the cervix after the removal of the mass. The mass was found to be a wood apple (fig. 3). After 5 days the patient was referred back to the medical ward. The patient recovered well and was discharged after 7 days.

DISCUSSION: A neglected prolonged foreign bodies in the vagina can produce various urinary problems³. Wood apple is common name for several trees with edible fruits and may refer to Aeglemarmellos or Limomiaacidissima, is a native of Bangladesh, India or Pakistan⁴. Various vernacular names in English are used like - Wood apple, Elephant apple, Monkey fruit and Curd fruit. The fruit is bony 5 to 10 cms in diameter. It has a very hard rind which can be difficult to crack open and contains sticky brown pulp and small white seeds⁵. The rind of the fruit is so thick and hard, it

CASE REPORT

can be carved and used as a bowl or ash tray. The fruit was used in the previous days for temporarily reducing the prolapse of the uterus⁶.

REFERENCES:

1. Malatya lioglu E, Alper T, Kokoo. An intravaginal foreign body of over 25 years duration. *Acta Obstet Gynecol Scand* 1999; 78; 616-17.
2. Nwobu EC, Rao S, Igweike C, Hamed H. Foreign objects of long duration in the adult vagina. *J Obstet Gynecol* 2005;25(7); 737-39.
3. Duncan LE, Foltzer M, O'Hearn M, et al. Unilateral Hydronephrosis, Pyelonephritis and bacteremia caused by a neglected ring pessary. *J Am Geriater Soc* 1997; 45:1413-14.
4. Arguments for *Limoniaacidissima* L (Rutaceae) and against its Rejection as a nomenambiguum. *Taxon* November 1978.
5. S G Joshi, Medicinal Plants, Oxford & IBH Publishing Co. Pvt. Ltd. New Delhi; 2004, ISBN 81-204-1414-4, P.347.
6. Poma PA. Non-surgical management of general prolapse – a review and recommendation for clinical prolapse. *J Reprod Med* 2000; 45:789.97.

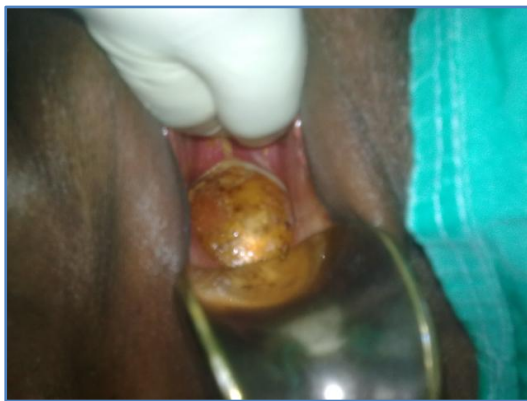

Fig. 1: Per speculum examination of the Wood apple

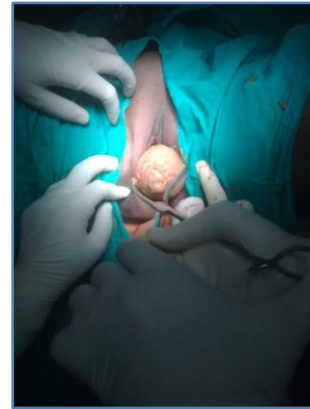


Fig. 2: Wood apple held with vulsellum

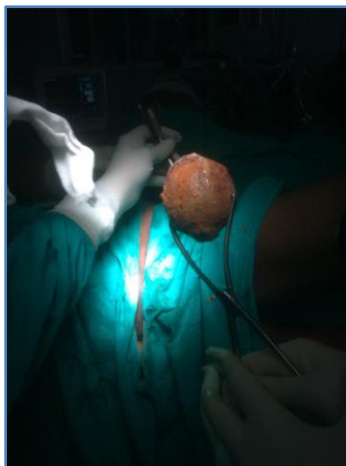

Fig. 3: Wood apple taken out

CASE REPORT

AUTHORS:

1. B. Venkateswara Rao

PARTICULARS OF CONTRIBUTORS:

1. Associate Professor, Department of Obstetrics and Gynaecology, Government Medical College / Government General Hospital, Anantapuram, Andhra Pradesh.

NAME ADDRESS EMAIL ID OF THE CORRESPONDING AUTHOR:

Dr. B. Venkateswara Rao,
H. No. 27-8-4, 4th Line,
Kannavarithota, Guntur – 522004,
Andhra Pradesh.
E-mail: birra_venkat@yahoo.com

Date of Submission: 01/03/2014.

Date of Peer Review: 03/03/2014.

Date of Acceptance: 14/03/2014.

Date of Publishing: 26/03/2014.