

CASE REPORT

IDIOPATHIC CERVICAL FIBROSIS- A CASE REPORT WITH REVIEW OF LITERATURE

M.J. Nirmala¹, S.S. Parinitha², Ravikala V Rao³

HOW TO CITE THIS ARTICLE:

M.J. Nirmala¹, S.S. Parinitha², Ravikala V Rao. "Idiopathic Cervical Fibrosis- A Case Report with Review of Literature". Journal of Evolution of Medical and Dental Sciences 2014; Vol. 3, Issue 01, January 06; Page: 56-59.

ABSTRACT: Idiopathic cervical fibrosis is a rare fibrosclerosing lesion of the head and neck region simulating a malignant process. It is designated as a tumefactive fibroinflammatory lesion constituting a heterogeneous clinical condition with an unknown cause and pathogenesis. Infection, Hodgkin's lymphoma, sarcoidosis, Autoimmune disease, trauma was considered as etiological factors in the past but recently considered to be idiopathic. We report a case of idiopathic cervical fibrosis involving the jaw destroying the ramus of the mandible and extending into the adjacent soft tissue planes upto skin. Biopsy revealed dense fibrous tissue, bands of hyalinised collagen admixed with inflammatory infiltrate composing of lymphocytes, plasma cells encasing vascular and neural structures. Lymphocyte markers (CD 3 & CD20) and vimentin was done to confirm the lymphocytes and fibrous tissue. A diagnosis of Idiopathic cervical fibrosis was made after excluding Fibromatosis, Nodular Fasciitis, Malignant Fibrous Histiocytoma and Fibrosarcoma. It is difficult to diagnose these conditions clinically and the X-ray and CT findings may be misleading. Biopsy is the only way to make the diagnosis along with the added marker study and IHC profile. Treatment includes surgical excision, steroid therapy and radiation used alone or in combination.

KEY WORDS: Cervicofacial; fibrosclerosing; tumefactive.

INTRODUCTION: Idiopathic fibrosclerosing disorder of the head and neck most often presents as a soft tissue tumor clinically simulating malignant process but histologically benign. The tumor has been designated with various names like tumefactive fibroinflammatory lesion, sclerosing cervicitis, inflammatory pseudotumour and cervical fibrosclerosis.¹ Some authors do suggest that the disease can represent a localized manifestation of a systemic condition because twenty percent of patients also have other inflammatory fibrosclerosing lesions like mediastinal fibrosis, sclerosing cholangitis, and retroperitoneal fibrosis.² The first case was reported by Rice et al in 1975 and he named it as sclerosing cervicitis.³ Since then approximately thirty cases have been reported till 2009.² These lesions can occur at several sites like buccal soft tissues, neck, infratemporal, or pterygopalatine fossa and submandibular gland.⁴ We report a case of idiopathic cervical fibrosis without associated systemic manifestations doing well with steroid therapy.

CASE REPORT: A 38 year old female presented to dental OPD with restriction of mouth opening since 2 months and pain in left side of jaw since 2 years. On examination facial asymmetry was seen in the left side of face. Intraoral examination showed well defined swelling extending from premolar to retromolar region and superiorly from upper vestibule to lower. X ray showed osteolytic lesion in the left ramus of mandible (Fig 1a).

CT scan showed an ill-defined soft tissue density growth involving left parasymphiseal region measuring 4x3.4x2.5 cms with irregular osteolytic destruction of underlying portion of the mandible extending into medullary cavity and widening mandibular foramen. Growth showed

CASE REPORT

extension into adjacent soft tissue planes upto skin. Submental, left jugular and submandibular lymphnodes were enlarged. Possibility of Lymphoma or metastasis was considered on CT scan (Fig 1b).

Incisional biopsy at 3 places was performed, Masseteric tissue at lower border of mandible, inferomedial aspect of the lesion and from left side buccal mucosa. Received three grey white firm to hard soft tissue masses measured 3x1.5x0.6 cms (masseteric tissue), 1.3x0.6x0.3 cm (inferomedial aspect of lesion) and 2x1x0.5 cm (left side buccal mucosa).

Microscopic examination revealed dense fibrous tissue, bands of hyalinised collagen admixed with inflammatory infiltrate composed of lymphocytes, plasma cells encasing vascular and neural structures. Invasion of surrounding muscle fibres was seen (Fig. 2a & 2b). Special stains for acid fast bacilli (Z N Stain) and fungi (GMS, PAS) were negative. Immunohistochemistry showed CD3 positive T lymphocytes, CD20 positive B lymphocytes and fibroblasts showed vimentin positivity (Fig 3a, 3b & 3c).

DISCUSSION: Idiopathic cervical fibrosis most commonly called as Tumefactive fibroinflammatory lesion of the head and neck was initially reported by Wold LE and Weiland LH.⁵ The etiology is obscure but attributed to infection, Hodgkin's lymphoma, Sarcoidosis, Autoimmune disease, trauma in the past but recently considered to be idiopathic.¹ The lesion is similar to that of sclerosing mediastinitis, retroperitoneal fibrosis and Reidel's thyroiditis all having a common histological pattern composing of mature hypocellular fibrous tissue with variable collagenization and hyalinization admixed with an inflammatory infiltrate of lymphocytes and plasma cells.⁶

The lesion can occur at any age with equal male and female predilection and clinically presents as a firm, mass like lesion eroding the adjacent structures and sometimes leading to their dysfunction.⁷ In our case it presented as a well-defined swelling extending from left premolar to retromolar region with osteolytic destruction of the mandible.

The only way to confirm the diagnosis is by open biopsy. In our case the histological findings was similar to those that have been described for other fibrosclerosing lesions.^{7,8} Search was made for the presence of fungi (GMS, PAS) as an etiologic agent and was excluded. Immunohistochemical studies to confirm the normal fibroblasts and lymphocytes were done. Also evidence for the presence of other fibrosclerosing lesions was looked for.

The differential diagnosis of inflammatory myofibroblastic pseudotumors especially the hyalinising variant should be considered. But these tumors are well circumscribed and show no evidence of adjacent invasion. The other differential diagnosis include Nodular fasciitis and Fibromatosis of which the former shows microcystic change, abundant mitosis and lacks prominent inflammatory infiltrate whereas the latter shows fascicles of long sweeping fibroblastic cells with patchy chronic inflammatory cell infiltration.² Sarcomatoid squamous cell carcinoma dominated by spindle cells rarely have hypocellular areas with fibromyxoid stroma and lack prominent nuclear atypia.⁶ Cervical fibrosis may be diagnosed as a lymphoma because of its infiltrative growth and dense lymphoid infiltrate. Lack of diffuse sheets of CD 20+ B cells and polytypia of the plasma cells support reactive process.⁹ It is difficult to diagnose these conditions clinically and the radiological findings may be misleading. Biopsy is the only way to make the diagnosis along with the added marker study. Treatment includes surgical excision, steroid therapy and radiation used alone or in combination.

CASE REPORT

Hostalet et al described Tumefactive fibroinflammatory lesion in a 74 yr. old female who presented with painless mass on right side of neck and patient responded to prednisolone 80mg/day given for 15 days and then gradually reduced over a period of 3 months.⁸ Proper guidelines have not been established for dose and duration of treatment. Cheuk W et al studied 4 cases of which 3 patients underwent excision of the tumor and one of them was also treated with steroid along with excision. The 4th case underwent biopsy of the neck mass followed by steroid therapy. Among the 2 patients who were treated with only surgical excision, one patient lost to follow up and other presented with recurrence.⁹ Idiopathic cervical fibrosis responds well with complete surgical excision and high dose of oral corticosteroids. Tamoxifen was also used as a drug of choice.² Response is incomplete with only steroid therapy and may present with recurrence following cessation of therapy.⁷

CONCLUSION: Idiopathic cervical fibrosis is a rare entity. Study of more number of cases with careful follow up would help in better understanding and management. However idiopathic cervical fibrosis should always be kept in mind whenever we come across a fibrosclerotic lesion in the head and neck region. One should not forget to look for systemic presentation of fibrosclerotic lesions.

REFERENCES:

1. Dehner LP, Coffin CM. Idiopathic fibrosclerotic disorders and other inflammatory pseudotumour. *Semin Diagn Pathol* 1998; 15: 161-173.
2. Wick MR. Soft tissue tumors of the Head and Neck. In, Gnepp DR(ed). *Diagnostic surgical Pathology of the Head and Neck*, 2nd edition. China, Saunders Elsevier, 2009; 649-651.
3. Rice DH, Batsakis JG, Coulthard SW. Sclerosing cervicitis: homologue of sclerosing retroperitonitis and mediastinitis. *Arch Surg* 1975; 110: 120-122.
4. Barnes L. *Surgical pathology of the head and neck (vol 3)*, 3rd edition. New York, Informa health care, 2009; 1367-1368.
5. Wold LE, Weiland LH. Tumefactive fibro-inflammatory lesions of the head and neck. *Am J SurgPathol* 1983; 7:477-482.
6. Pilch BZ. *Head and neck surgical Pathology*, 2nd edition. Philadelphia, lippincott Williams and Wilkins, 2001; 136-137.
7. Lorenzo JF, Graham S M. Tumefactive fibroinflammatory lesion of the head and neck: A management strategy. *Ear Nose throat J* 1995; 74:87-91.
8. Hostalet F, Hellin D, Ruiz JA. Tumefactive fibroinflammatory lesion of the head and neck treated with steroids: a case report. *Eur Arch Otorhinolaryngol* 2003; 260:229-231.
9. Cheuk W, Tam FKY, Chan ANH, Luk ISC, Yuen APW, Chan W, Hung TCW, Chan JKC. *Am J Surg Pathol* 2010; 34(11):1678-1685.

CASE REPORT

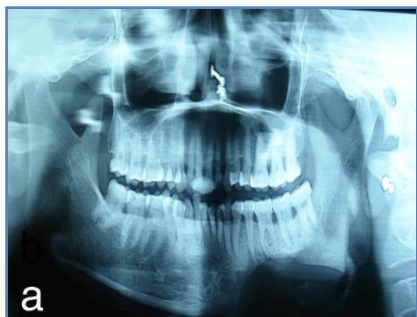

Fig. 1a: X-ray showing osteolytic lesion in the left ramus of the mandible.

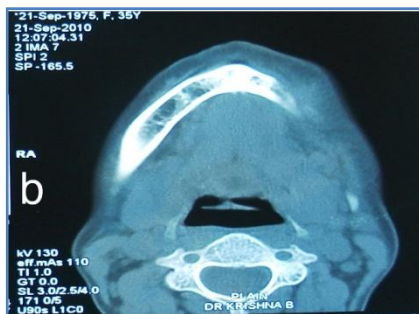


Fig. 1b: CT scan showing ill defined soft tissue density growth involving left parasymphyseal region with osteolytic destruction of the left mandible.

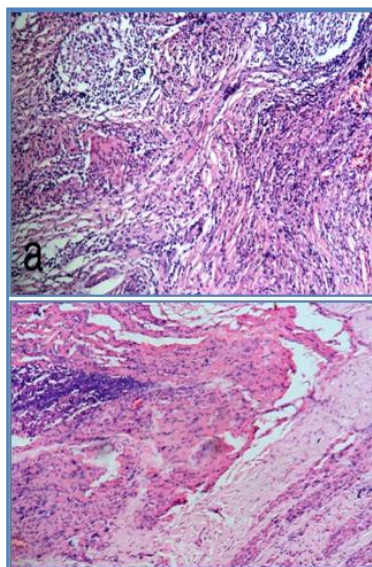


Fig. 2a & 2b: Histopathologic sections showing dense fibrous tissue, hyalinised collagen and chronic inflammatory cells infiltrating skeletal muscle fibres (H&E, 10x10).

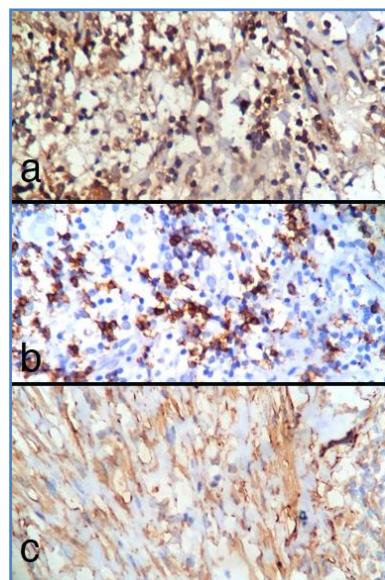


Fig. 3a, 3b & 3c: Immunohistochemical staining showing diffuse positivity for CD3, CD20 and vimentin respectively (IHC, 10x40).

AUTHORS:

1. M.J. Nirmala
2. S.S. Parinitha
3. Ravikala V. Rao

PARTICULARS OF CONTRIBUTORS:

1. Associate Professor, Department of Pathology, SDM College of Medical Sciences and Hospital.
2. Associate Professor, Department of Pathology, SDM College of Medical Sciences and Hospital.
3. Professor, Department of Pathology, SDM College of Medical Sciences and Hospital, Dharwad.

NAME ADDRESS EMAIL ID OF THE CORRESPONDING AUTHOR:

Dr.Parinitha S.S.,
Associate Professor,
Department of Pathology,
SDM College of Medical Sciences and Hospital,
Sattur – 580009, Dharwad.
Email-drparinithabhat@gmail.com

Date of Submission: 02/12/2013.
Date of Peer Review: 03/12/2013.
Date of Acceptance: 18/12/2013.
Date of Publishing: 01/01/2014