

**THE DIAGNOSTIC ACCURACY OF IMPRINT CYTOLOGY IN BREAST LESIONS**M. R. Shashidhar<sup>1</sup>, Zulfikar Ahmed<sup>2</sup>, Umaru N<sup>3</sup>**HOW TO CITE THIS ARTICLE:**

M. R. Shashidhar, Zulfikar Ahmed, Umaru N. "The Diagnostic Accuracy of Imprint Cytology in Breast Lesions". Journal of Evolution of Medical and Dental Sciences 2015; Vol. 4, Issue 25, March 26; Page: 4299-4307, DOI: 10.14260/jemds/2015/621

**ABSTRACT: BACKGROUND:** The imprint cytology is one of the rapid diagnostic tools in the field of diagnostic pathology. This method not only helps us to examine the individual cells but also aids in analyzing the patterns of particular lesion. Differentiating between benign and malignant lesions prior to or during surgery, helps the surgeon to decide on the extent of surgery. **AIMS:** The present study was conducted to know the accuracy of intraoperative imprint smears and to compare the results with that of histopathological sections in all breast tumors. **MATERIALS AND METHODS:** This was a descriptive study on 100 cases of breast lesions comprising of inflammatory, benign & malignant. Results were compared with histopathology. **STATISTICAL ANALYSIS USED:** Sensitivity, specificity, positive predictive value and negative predictive value. **RESULTS:** Out of 100 cases, 50 cases were diagnosed as benign and 50 cases as malignant lesions on imprint smear. Fibroadenoma (26%) was the most common benign lesion and invasive ductal carcinoma (38%) was the most common malignant lesion. The sensitivity and specificity of imprint cytology were 98% and 96.1% respectively. 96% PPV, 98% NPV and 97% overall diagnostic accuracy was observed for imprint cytology in the present study. **CONCLUSIONS:** Imprint cytology is a simple, accurate, rapid & cost effective diagnostic tool used intra operatively, where in facilities for frozen sections are not available.

**KEYWORDS:** Imprint; histopathology; benign; malignant; breast.

**INTRODUCTION:** Breast lumps are one of the commonest complaints encountered in surgical OPD. Worldwide breast cancers comprise 22.9% of all cancers. This diagnosis is provided by preoperative FNAC and more specifically by intraoperative imprint or frozen section. To increase the diagnostic accuracy, the combined use of imprints and frozen sections are recommended.

The imprint method allows cytological techniques to be used for the examination of individual cells yet preserves to some extent the histological pattern of the imprinted tissue. As a diagnostic method it lies between cytological smear techniques and routine histopathological sections.

**METHODS:** The study included all patients undergoing elective breast tumor surgeries in our hospital between September 2012 to September 2014. Total number of cases 100.

Specimens were received during intraoperative procedure. Freshly resected specimen was grossly examined and a fresh cut through the tumor was given. Touch imprint smears were taken by gently pressing the slides on the cut surface. Scrape imprints were also taken by gently scraping the cut surface with the edge of the slide and smearing the material on the other slide. The smears were then fixed appropriately and stained using rapid pap and giemsa stain. An imprint cytological diagnosis was given. These results were then compared with histopathology.

## ORIGINAL ARTICLE

**RESULTS:** The present study comprised of 100 cases of breast lesions. The age of the patients range from 18 to 82 years, with a mean age of 40.24 years (SD 15.79).

Majority of benign lesions were seen between 20 to 30 years, whereas malignant lesions were seen between 51 to 60 years. [Table 1]

Age in years	Benign	Malignant	Total
≤20	9	-	9
21-30	21	-	21
31-40	11	13	24
41-50	4	14	18
51-60	2	15	17
61-70	4	4	8
71-80	-	1	1
>80	-	2	2
<b>TOTAL</b>	<b>51</b>	<b>49</b>	<b>100</b>

Based on histopathological diagnosis

**Table 1: Distribution of benign and malignant breast lesions in different age groups**

With the help of operating surgeon, the freshly resected breast specimens were taken up for intra-operative imprint cytology.

Along with detailed clinical history and examination findings, pre-operative findings were collected from the surgeon. The stained smears were microscopically examined and diagnosis was arrived within a short time and the breast specimen was subsequently taken up for histopathological examination. The histopathological diagnosis was considered as the gold standard and imprint cytological diagnosis was compared with it.

Breast lesions	Frequency	Percentage (%)
<b>BENIGN LESIONS(n=50)</b>		
Fibroadenoma	26	26.0
Fat necrosis	6	6.0
Fibrocystic disease	5	5.0
No Residual Tumor (post lumpectomy)	4	4.0
Phyllodes tumor	4	4.0
Foreign body granuloma	2	2.0
Benign breast lesion	2	2.0
Benign inflammatory lesion	1	1.0
<b>MALIGNANT LESIONS(n=50)</b>		
Invasive ductal carcinoma	38	38.0
Mucinous carcinoma	5	5.0

## ORIGINAL ARTICLE

Invasive lobular carcinoma	2	2.0
Ca Breast	1	1.0
Comedo carcinoma	1	1.0
Medullary carcinoma	1	1.0
Papillary carcinoma	1	1.0
Tubular carcinoma	1	1.0
<b>Total</b>	<b>100</b>	<b>100.0</b>

**Table 2: Distribution of the cases based on imprint cytology**

But histopathological examination, out of 100 cases 51 cases were benign and 49 malignant.

Imprint		Histopath		Total
		Carcinoma	Benign	
Carcinoma	Count	48	2	50
	%	98.0%	3.9%	50.0%
Benign	Count	1	49	50
	%	2.0%	96.1%	50.0%
<b>Total</b>	<b>Count</b>	<b>49</b>	<b>51</b>	<b>100</b>
	<b>%</b>	<b>100.0%</b>	<b>100.0%</b>	<b>100.0%</b>

**Table 3: Imprint Cytology VS Histopathology**

a. Sensitivity=98%, Specificity=96.1%, Positive Predictive value=96%,  
Negative predictive value=98%. Accuracy rate=97%

Out of the 50 cases diagnosed as carcinoma on imprint cytology 48(96.1%) cases confirmed by histopathologically and 2(3.9%) cases turned out to be benign histopathology. [Table 3]

Among the 50 cases that were diagnosed as benign on imprint 49 (98%) cases confirmed on histopathologically and 1(2%) case turned out to be malignant. [Table 6]

There were three cases showing discrepancies between the imprint cytological diagnosis and histopathological diagnosis. Two cases were false positive and one case was false negative.

The first false positive diagnosis was CA breast on the imprint cytology, but in histopathology the diagnosis FA was made.

The second false positive case was IDC, which turned out to be proliferative fibrocystic disease in histopathology.

The only false negative case was FA on imprint cytology, but on histopathology the diagnosis tubular carcinoma was made.

Total numbers of breast lesions	Sensitivity	Specificity	PPV	NPV	Accuracy
100	98%	96.1%	96%	98%	97%

**Table 4: Statistical values of the study**

## Color plates:

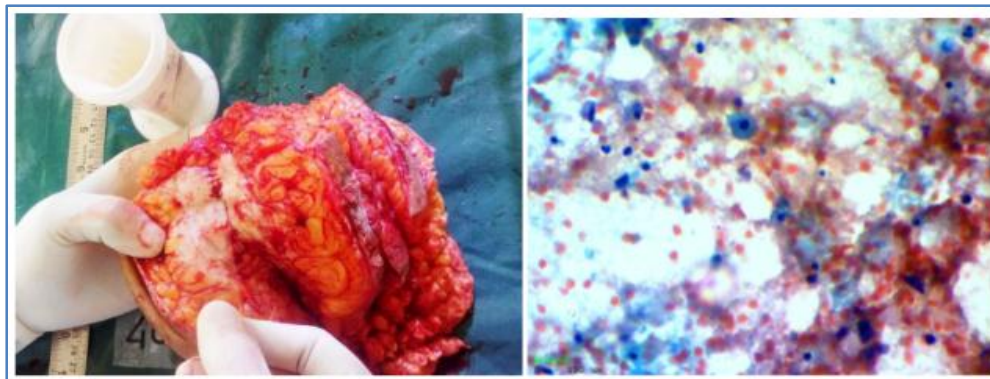


Figure 1

Figure 2

Photograph showing touch imprint being taken from the tumor.

Imprint smear showing fat necrosis with numerous histiocytes. (Pap stain, 400x)

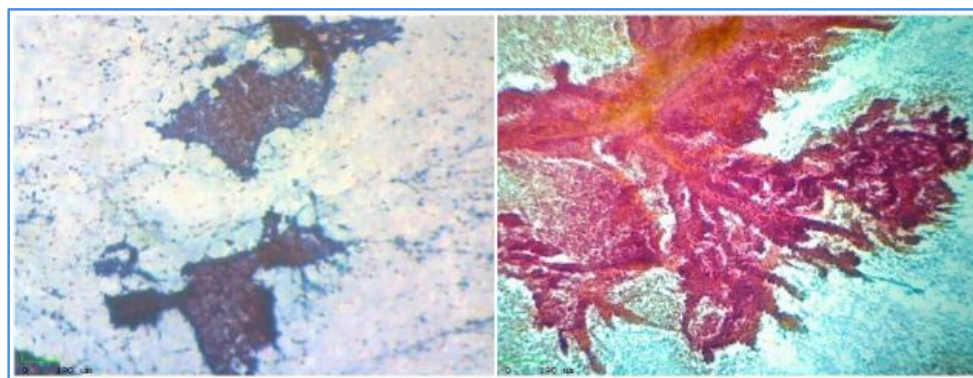


Figure 3

Figure 4

Imprint smear showing fibroadenoma with antler-like pattern (Pap stain, 100x).

Imprint smear showing papillary fronds in papillary carcinoma (Pap stain, 100x).

**DISCUSSION:** Lesions of the breast are commonly encountered in routine clinical practice. Even though FNAC, mammography and ultrasonography are routinely used for diagnostic purposes in breast lesions, the distinction between the benign and malignant lesions cannot be made out in some of the cases. When the preoperative diagnostic work up is inconclusive, an intra-operative diagnosis plays a crucial role in deciding the extent of surgery to be performed.

Nowadays, even though frozen section is the commonly used intraoperative diagnostic technique, it has its own limitations. It is time consuming, requires specialized equipment, needs well trained histopathologists and is expensive.

The technique of imprint cytology is accurate, simple, rapid, and cost effective and does not require any special instrument.

## ORIGINAL ARTICLE

In the present study imprint smears from fresh breast specimens were collected intra-operatively for interpretation. Since histopathology is considered the gold standard for diagnosis, the imprint smears of 100 breast specimen samples were compared with it.

In the present study, the benign breast lesions were most common between 21 to 30 years and malignant lesions between 51 to 60 years. The age incidence of benign lesions was comparable with the studies by Hiregoudaret al<sup>1</sup> and Khudier et al.<sup>2</sup> However the age of incidence of malignant lesions in the present study was higher than these studies.

Sl. no	Study group	Benign (%)	Malignant (%)
1	Hiregoudar et al <sup>1</sup>	50	50
2	Al-Rikabi et al <sup>3</sup>	56	44
3	Present study	50	50

**Table 5: Comparison of distribution of benign and malignant lesions diagnosed by imprint cytology**

In the present study there were 50 % cases of benign lesions and 50% cases of malignant lesions in imprint cytology. The percentage of malignant lesions diagnosed by imprint cytology in the present study is same as Hiregoudar et al<sup>1</sup> and slightly higher than the study done by Al- Rikabi et al.<sup>3</sup>[Table 5]

Sl. No	Lesions	Akthar et al <sup>4</sup>	Hiregouda r et al <sup>1</sup>	PRESENT STUDY
<b>Benign lesions</b>				
1	Fibroadenoma	6(15%)	12(30%)	26(26%)
2	Fat necrosis	-	-	6(6%)
3	Fibrocystic disease	2(5%)	4(10%)	5(5%)
4	No residual tumor	2(5%)	-	4(4%)
5	Phyllodes tumor	1(2.5%)	-	4(4%)
6	Foreign body granuloma	-	1(2.5%)	2(2%)
7	Benign breast lesion	-	1(2.5%)	2(2%)
8	Benign inflammatory lesion	2(5%)	-	1(1%)
9	Infarcted tubular adenoma	1(2.5%)	-	-
10	Lobular hyperplasia	-	2(5%)	-
11	Lumpectomy margins	2(5%)	-	-
<b>Malignant lesions</b>				
12	Invasive ductal ca	24(60%)	20(50%)	38(38%)
13	Medullary ca	-	-	5(5%)
14	Invasive lobular ca	1(2.5%)	-	2(2%)
15	Ca breast	-	-	1(1%)
16	Comedo ca	-	-	1(1%)

## ORIGINAL ARTICLE

17	Medullary ca	-	-	1(1%)
18	Papillary ca	-	-	1(1%)
19	Tubular ca	-	-	1(1%)
20	Malignant phylloids	1(2.5%)	-	-
	<b>Total</b>	<b>40</b>	<b>40</b>	<b>100</b>

**Table 6: Comparative incidence of breast lesions diagnosed by imprint method in different studies**

**BENIGN LESIONS:** Out of the 50 cases were diagnosed as benign lesions, 26 cases were diagnosed as fibroadenoma, 6 cases as fat necrosis, 5 cases as fibrocystic disease, 4 cases of phyllodes tumor, 2 cases as foreign body granuloma, 2 cases as benign lesion and 1 case as benign inflammatory lesion. In 4 cases there was no residual tumor in post lumpectomy cases.

**FIBROADENOMA:** In the present study of 100 breast lesions, 26 cases (26%) were diagnosed as fibroadenoma by imprint method. Cytological smears showed cellular smears with a bimodal pattern containing epithelial and stromal fragments, large, branching sheets of bland epithelial cells, numerous single, bare bipolar/oval nuclei and fragments of fibromyxoidstroma.

Similar to the study by Akthar<sup>4</sup> et al and Hiregaudar et al,<sup>1</sup> the present study also showed that the majority of the benign lesions showed fibroadenoma. [Table6]

In a study by Su<sup>5</sup> cases diagnosed by fibroadenoma showed high cellularity in which the ductal epithelium was the dominant cell type – including both aggregated cells and naked bipolar nuclei and foam cells and apocrine cells in less numbers. The author also noted many atypical epithelial cells with enlarged nuclei and hyperchromatism might have originated from the proliferating ductal epithelium.

In the present study, in one case, a diagnosis of fibroadenoma was given on imprint cytology, which turned out to be tubular carcinoma histopathologically. (Discussed later)

Out of the 2 false positive cases, one case was diagnosed as CA breast on the imprint cytology, but on histopathology the diagnosis FA was made.(Discussed later)

**FIBROCYSTIC DISEASE:** In the present study out of 100 breast lesions, 5 cases (5%) were diagnosed as fibrocystic disease. Similar value was observed in a study done by Akthar et al (5%) and a study done by Hiregaudar et al showed 10% cases of fibrocystic diseases [Table 6].

Smears from a case of fibrocystic disease showed cyst macrophages and more or less degenerated apocrine epithelial cells in the background of inflammatory cells.

In one of the cases, in the present study, a false positive diagnosis of IDC was made, which turned out to be proliferative fibrocystic disease histopathologically (Discussed later).

**PHYLLODES TUMOR:** In the present study phyllodes tumor constituted 4% of the cases which comparable to a study done by Akthar et al (2.5%). [Table 6]

The imprint smears showed hypercellularity with increased cellular stromal component and minimal stromal atypia.

In one of the cases in the present study, because of lack of cellularity a diagnosis benign breast lesion was made. But on histopathology it turned out to be phyllodes tumor.

## ORIGINAL ARTICLE

**NO RESIDUAL TUMOR (NRT):** In the present study there were 4(4%) post lumpectomy cases, in which clinicians wanted to rule out recurrence of tumor. On imprint cytology these cases showed there was no evidence of residual tumor, which was confirmed by histopathology.

**MALIGNANT LESIONS:** Out of the 50 cases diagnosed as malignant lesions, 38 cases were diagnosed as invasive ductal carcinoma, 5 cases as mucinous carcinoma, 2 invasive lobular carcinoma and 1 case each of CA breast, comedo carcinoma, medullary carcinoma, papillary carcinoma and tubular carcinoma.

**INVASIVE DUCTAL CARCINOMA:** Imprint smears from invasive ductal carcinoma showed malignant cells arranged in sheets, clusters and scattered singly. Individual malignant cells showed pleomorphism, hyperchromatism and prominent irregular nuclei in the inflammatory background.

Akhtar et al<sup>4</sup> reported invasive ductal carcinoma in 60% of the cases. Hiregaudar et al<sup>1</sup> reported 50% of the cases as IDC, in present study there were 38% cases of invasive ductal carcinoma.[Table 6]

Sl. no	Study group	Year	No. of cases	No. F.Pos	No. F.Neg	Sensitivity	Specificity	Accuracy
1	Rosa et al <sup>6</sup>	1993	407	0(0%)	7(1.72%)	97.6%	99.4%	98.3%
2	Veneti et al <sup>7</sup>	1996	351	1(0.28%)	5(1.4%)	97.1%	99.4%	98.3%
3	Scucchi et al <sup>8</sup>	1997	1197	0(0%)	9(0.75%)	97.5%	100%	99.2%
4	Albert et al <sup>9</sup>	2000	173	3(1.7%)	4(2.3%)	96.5%	90%	95.4%
5	Creager et al <sup>10</sup>	2002	137	15	20	80%	85%	74.4%
6	Khudier et al <sup>2</sup>	2006	107	0(0%)	1(0.99%)	96.3%	100%	98.9%
7	Present study	2014	100	1(1%)	2(2%)	98%	96.1%	97%

**Table 7: Comparison of statistical parameters to assess efficacy of imprint cytology in various breast imprint smears**

In the present study, diagnostic accuracy, sensitivity, specificity, false positive and false negative values were determined by comparing imprint cytological diagnosis with final histopathological diagnosis.

In the present study diagnostic accuracy, sensitivity and specificity of imprint cytology was 97%, 98% and 96.1% respectively. There were 2% cases of false negative and 1% case of false positive.

The low percentage of false-positive diagnoses in this study suggested that a diagnosis of malignancy by the imprint method is reliable.

## ORIGINAL ARTICLE

---

**False-negative reports were generally due to one of the following two reasons:**

**(a) Interpretative errors:** These occur in cytologically well-differentiated tumors. The morphological changes of the neoplastic cells in these tumors were often subtle. A conservative attitude is warranted in order to avoid over diagnosis.

**(b) Insufficient cells:** There was a dense fibrous stroma in some tumors.

The first false positive diagnosis was CA breast on the imprint cytology, due to the high cellularity and mild to moderate nuclear pleomorphism noted in the breast epithelial cells. But in histopathology a diagnosis FA was made. It has been found that on imprinting fibroadenoma a surprisingly large amount of cellular material was transferred to the slide. This hypercellularity which is that usually associated with malignant imprints was a confusing element in the cytological diagnosis of these tumors. Similar observations were noted a study done by Al- Rikabi.<sup>2,3</sup>

The second false positive was a case which was diagnosed as IDC on imprint cytology because of florid cell population and considerable atypia, it turned out to be proliferative fibrocystic disease on histopathological examination. Similar findings were mentioned by Akthar et al.<sup>4, 11</sup>

One case was diagnosed as fibroadenoma because of cellular arrangement, larger, cohesive, monolayered sheets of epithelial cells, nuclear enlargement and atypia. But on histopathology a diagnosis tubular carcinoma was made which was the only false negative case in the present study.<sup>12</sup>

This study revealed a diagnostic accuracy of 97% on imprint cytology, which was comparable to the studies done by Rosa et al,<sup>6</sup> Vineti et al,<sup>7</sup> Scucchi et al,<sup>8</sup> Albert et al<sup>9</sup> and Khudier et al.<sup>2</sup> However it was much higher than that reported by Creager et al.<sup>10</sup>

The specificity of imprint cytology in the present study was 96.1% which was lesser than that reported by Scuchhi et al,<sup>8</sup> Khudier et al,<sup>2</sup> Rosa et al<sup>6</sup> and Veneti et al<sup>7</sup> but it was higher than the study done by Creager et al<sup>10</sup> and Albert et al.<sup>9</sup>

In the present study sensitivity of imprint cytology was 98% which was comparable to the study by Rosa et al,<sup>6</sup> Vineti et al,<sup>7</sup> Scucchi et al,<sup>8</sup> Albert et al<sup>9</sup> and Khudier et al.<sup>2</sup> But it was much higher than that reported by Creager et al.<sup>10</sup>

To conclude, the imprint method allows cytological techniques to be used for the examination of individual cells yet preserves to some extent the histological pattern of the imprinted tissue. Differentiating between benign and malignant lesions prior to or during surgery helps the surgeon to decide on the extent of surgery. As a diagnostic method it lies between cytological smear techniques and routine histopathological sections.

In the present study the overall diagnostic accuracy was 97%. The positive predictive value was 96% and the negative predictive value was 98%.

To conclude, imprint cytology is a simple, accurate, rapid & cost effective diagnostic tool which can be used intraoperatively, wherein facilities for frozen sections are not available. Imprint smears prepared from fresh surgical specimens give excellent cytological clarity.

### REFERENCES:

1. Hiregoudar AD, Godhi AS, Malur PR, Gogeri BV, Metgud SC. Accuracy of intraoperative imprint smears in breast tumours: A study of 40 cases with review of literature. *Indian Journal of Surgery*; 2006; 68: 302-305.



## ORIGINAL ARTICLE

2. Khudier HH, Hawramy TA, Abdul QGA. Role of imprint cytology in breast lesions. *Iraqi J Med sci.*2009; 7(4):61-6.
3. Al-Rikabi AC, Al-Sohaibani MO. Intra-operative cytology and frozen sections of breast lesions: a comparison from a saudi teaching hospital. *Bahrain Medical Bulletin.*1996; vol 18(1).
4. Akthar ZN, Qureshi SA, Aziz N, Niazi S, Qureshi SS. Evaluation of accuracy of intra-operative imprint cytology for detection breast lesions. *Annals* 2010; 16: 48-53.
5. Su MS. The Cytological diagnosis in the imprint smears of breast biopsy. *Bulletin of Taipei medical.* 1985; 14: 143-153.
6. Rosa GD, Boschi R, Boscanio A, Petrella G, Vetrani A, Palombini L, Pettinato G: Intraoperative cytology in breast cancer diagnosis: Comparison between cytologic and frozen section technique. *DiagCytopathol*, 1993; 9:623-631.
7. Veneti S, Mouzaka LI, Toufexi H, Xenitides J, Anastasiadis P: Imprint cytology: A rapid, reliable method of diagnosing breast malignancy. *Acta Cytol*, 1996; 40: 649-652.
8. Scucchi LF, Stefano DD, Cosentino L, Vecchione A: Value of cytology as an adjunctive intraoperative diagnostic method. An audit of 2,250 consecutive cases. *Acta Cytol*, 1997; 41: 1489-1496.
9. Albert US, Duda V, Hadji P, Goerke K, Hild F, Bock K, et al. Imprint cytology of core needle biopsy speci-mens breast lesions. *Acta Cytol* 2000; 44: 57-62.
10. Creager AJ, Shaw JA, and Young PR, Geisinger KR: Intraoperative evaluation of lumpectomy margins by imprint cytology with histologic correlation. A community hospital experience. *Archives of Pathology and Laboratory Medicine*, 2002(b); 126 (7): 846- 848.
11. Schnitt SJ, Connolly JL, Tavassoli FA, et al.: Interobserver reproducibility in the diagnosis of ductal proliferative breast lesions using standardized criteria. *Am J Surg Pathol* 1992; 16(12): 1133-1143.
12. Cibas ES, Ducatman BS. *Cytology Diagnostic principles and clinical correlates.* 3<sup>rd</sup> ed. Philadelphia: Saunders Elsevier; 2009. p. 221-254.

### AUTHORS:

1. M. R. Shashidhar
2. Zulfikar Ahmed
3. Umaru N.

### PARTICULARS OF CONTRIBUTORS:

1. Post Graduate Student, Department of Pathology, A. J. Institute of Medical Sciences & Research Centre, Mangalore.
2. Associate Professor, Department of Pathology, A. J. Institute of Medical Sciences & Research Centre, Mangalore.

### FINANCIAL OR OTHER

**COMPETING INTERESTS:** None

3. Professor & HOD, Department of Pathology, A. J. Institute of Medical Sciences & Research Centre, Mangalore.

### NAME ADDRESS EMAIL ID OF THE CORRESPONDING AUTHOR:

Dr. Zulfikar Ahmed,  
Department of Pathology,  
A. J. Institute of Medical Sciences &  
Research Centre, Kuntikana, Mangalore-575004.  
E-mail: zulfikaraha@gmail.com

Date of Submission: 27/02/2015.  
Date of Peer Review: 28/02/2015.  
Date of Acceptance: 14/03/2015.  
Date of Publishing: 25/03/2015.