

REVIEW ARTICLE

PULMONARY EMBOLISM- UNRAVELLING PERPLEXITY

Sudeep Pathak¹, Renu Sharma².

HOW TO CITE THIS ARTICLE:

Sudeep Pathak, Renu Sharma. "Pulmonary embolism- unravelling perplexity". Journal of Evolution of Medical and Dental Sciences 2013; Vol2, Issue 28, July 15; Page: 5167-5173.

ABSTRACT: Pulmonary embolism (PE) is frequent in our country and accounts for thousands of hospitalization with significant mortality and morbidity. Diagnosing PE in our country is very difficult where there is paucity of high resolution multi-detector 64 slice CT scan along with financial limitations of patients. We can diagnose moderate to large pulmonary embolism with the help of D Dimer assay, electrocardiography, echocardiograph, Chest X ray along with symptoms which are highly suggestive of pulmonary embolism apart from the gold standard that is high resolution 64 slice multi-detector CT scan. There is a greater need to confirm and diagnose PE with the help of D-dimer assay, electrocardiography, Echocardiograph, Chest X ray in patients who present with features of PE(wells criteria) in our country because either most hospital in our country do not have multi detector CT scan or patient is not financially sound to afford it. We can still diagnose PE without CT scan and thus in turn can treat most of the patients with moderate to large pulmonary embolism without high resolution CT scan.

INTRODUCTION: Pulmonary embolism accounts for millions of hospitalizations annually worldwide. Although D-Dimer testing for exclusion of PE and chest computed tomography(CT)for imaging PE have revolutionized the diagnostic approach, PE remain difficult to detect unless high index of clinical suspicion is kept during management of critically ill patients.

Our understanding of the precipitants of PE has improved especially the role of hypercoagulable states and potentially modifiable risk factors such as long-haul air travel and obesity. Doctors in critical care and cardiologist must provide expertise in the treatment of hemodynamically compromised patients with PE as well as those with right ventricular failure who maintain a stable blood pressure and heart rate. This requires rapid and accurate risk stratification, often with echocardiography, elevation of troponin, D-dimer assay, brain natriuretic peptide levels, so that those patients with adverse prognosis will be identified and treated with thrombolysis or embolectomy.

PATHOPHYSIOLOGY: There are various precipitating factors for venous thrombosis which in turn can cause PE.

A- INHERITED FACTORS

HYPERCOAGULABLE STATES	
1	Mutation in factor v gene(factor v laden)
2	Resistance to activated protein C
3	Prothrombin gene mutation
4	Mutation in protein C gene
5	Protein S deficiency
6	Antithrombin 3 deficiency
7	Hyperhomocysteinemia
8	Anti-phospholipid antibody

REVIEW ARTICLE

B- ACQUIRED CONDITIONS

ACQUIRED CONDITIONS MAY PRECIPITATE VENOUS THROMBOSIS

1. Long -haul air travel
2. Surgery / immobilization / trauma
3. Hospitalization with medical illness such as pneumonia or congestive heart failure, stay in medical or surgical intensive care unit .
4. Obesity
5. Increasing age
6. Cigarette smoking
7. Systemic arterial hypertension
8. Diabetes mellitus
9. Use of oral contraceptives / pregnancy / postpartum state
10. Cancer and cancer chemotherapy
11. Stroke / spinal cord injury
12. Indwelling central venous catheter , pacemakers and internal cardiac defibrillators

Relationship between Deep Venous Thrombosis and Pulmonary Embolism When venous thrombi detach from their sites of formation, they flow toward pulmonary circulation. Extremely large embolus lodge at the bifurcation of pulmonary artery, forming a saddle embolus. More commonly a major pulmonary vessel is occluded.

RIGHT VENTRICULAR DYSFUNCTION. As pulmonary artery obstruction increases, pulmonary artery pressure rises. The release of vasoconstriction compounds such as serotonin, reflex pulmonary artery vasoconstriction, and hypoxia may further increase pulmonary vascular resistance and result in pulmonary hypertension. The injured right ventricle release brain natriuretic peptide and troponin which predict increase likelihood of adverse outcome.

VENTRICULAR INTERDEPENDENCY. The sudden rise of pulmonary artery pressure reflect an abrupt rise in right ventricular after load and consequent elevation of right ventricular wall tension followed by right ventricular dilation and dysfunction. As right ventricle dilates the inter-ventricular septum deviates towards the left with resultant under-filling and decrease diastolic distensibility of this chamber. There is increase in right ventricular myocardial oxygen demand which results in ischaemia and possibly cardiogenic shock. It can lead to right ventricular infarction, circulatory collapse and death.

CLINICAL PRESENTATION: Diagnosis of PE is more difficult than treatment or prevention. Dyspnea is the most frequent symptom and tachypnea is the most frequent sign of PE. In general, severe dyspnea syncope, or cyanosis portends a major life threatening PE.

REVIEW ARTICLE

MOST COMMON SYMPTOMS AND SIGNS OF PULMONARY EMBOLISM	
SYMPTOM OR SIGN	PERCENT
Dyspnea	82
Respiratory rate >20/min	60
Heart rate >100beats/min	40
Chest pain	49
Cough	20
Syncope	14
Hemoptysis	7

Well and colleagues has developed a rapid seven question bedside assessment, they designated a score of 4.0 or lower as "PE unlikely."

WELLS CLINICAL BEDSIDE SCORING SYSTEM FOR SUSPECTED PULMONARY EMBOLISM	
PARAMETER	POINTS
Clinical sign and symptom of DVT(minimum of leg swelling and pain with Palpation of the deep veins)	3.0
An alternative diagnosis is less likely than PE	3.0
Heart rate greater than 100	1.5
Immobilization or surgery in the previous 4 weeks	1.5
Previous DVT / PE	1.5
Hemoptysis	1.0
Malignancy (on treatment, treated in the last 6 month, or palliative)	1.0

CLINICAL SYNDROMES OF PULMONARY EMBOLISM

Classification of PE into various syndromes is useful for prognostication and for deciding on subsequent clinical management.

A-Massive PE: Present with breathlessness, syncope, cyanosis with persistent systemic arterial hypotension; typically >50 percent obstruction of pulmonary vasculature. They have right ventricular dysfunction and are treated with Heparin plus thrombolytic therapy or mechanical ventilation.

B-Moderate to large PE: Present with normal systemic arterial blood pressure; typically more than 30 percent perfusion defect on lung scan. They have right ventricular dysfunction and are treated with Heparin plus or minus thrombolytic therapy or mechanical intervention.

C-Small to moderate PE-They have normal arterial blood pressure, right ventricular dysfunction is absent and are treated with heparin.

D-Pulmonary infarction -They present with pleuritic chest pain, hemoptysis, pleural rub or evidence of lung consolidation; typically peripheral small emboli. Right ventricular dysfunction is rare and is managed by heparin and nonsteroidal anti-inflammatory.

E-Paradoxical embolism- Present with sudden systemic embolic event such as stroke, RV dysfunction is rare and is treated with Anticoagulation +/- closure of right-left cardiac shunt.

REVIEW ARTICLE

F-Non-thrombotic embolism –Are due to most commonly air, fat, tumor fragments or amniotic fluid. RV dysfunction is rare and is managed by supportive measures.

NON IMAGING DIAGNOSTIC METHOD: A-PLASMA D-DIMER ELISA: In most patient with ongoing endogenous fibrinolysis, there is breakdown of fibrin clot to D dimer. Elevated levels of D-dimer is suggestive of PE but it is not specific of PE .It is found in various other conditions .A negative D-dimer value is sensitive marker to rule out PE.

B-ELECTROCARDIOGRAM: Patients with PE may have sinus tachycardia, minor ST and T wave abnormality, negative T wave in precordial leads V1 to V4, incomplete or complete right bundle branch block, S1Q3T3 or as most of the time it could be completely normal.

IMAGING DIAGNOSTIC METHOD:

A-CHEST RADIOGRAPHY: Chest X-ray could be completely normal, or there could be focal oligemia (westermark, s sign) indicates massive central embolic occlusion. A peripheral wedge shape density (Hampton, s hump) usually indicates pulmonary infarction .

B- CHEST COMPUTED TOMOGRAPHY: Chest CT has supplanted pulmonary radionuclide perfusion scintigraphy as the initial imaging test in most patients with suspected PE for the evaluation of suspected PE; the CT examination can include scanning of venous system from popliteal veins to the sub segmental pulmonary arteries. It can also provide information regarding the size and function of right ventricle and right ventricular dysfunction .The latest generation of multidetector-row CT scanners permits image acquisition of the entire chest with 1 mm or sub-millimetre resolution with a breath hold of less than 10 seconds. It has become as gold standard for PE imaging.

C- **LUNG SCANNING:** It is no longer the principle diagnostic imaging test, it is usually reserved for patients with renal insufficiency, contrast allergy or pregnancy (because of lower fetal radiation exposure than CT)

D-ECHOCARDIOGRAPHY: Following are the sings of PE on echocardiography;

- Direct visualization of thrombus.
- Right ventricular dilatation
- Right ventricular hypokinesia (with sparing of apex)
- Abnormal inter-ventricular septal motions.
- Tricuspid valve regurgitation.
- Pulmonary artery dilatation
- Lack of decreased inspiratory collapse of inferior vena cava.

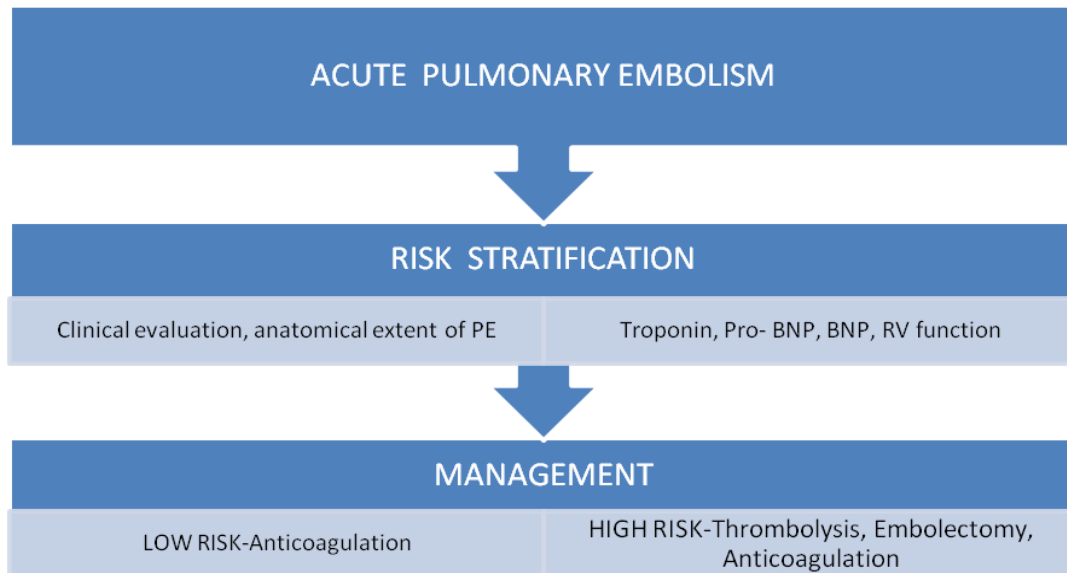
MANAGEMENT: RISK STRATIFICATION: The three key components for risk stratification are (1) Clinical evaluation (with Geneva prognostic index. (2) Biomarkers such as troponin, Pro-BNP and BNP (3) Assessment of right ventricular function usually accomplished with echocardiography

REVIEW ARTICLE

Geneva point score to assess Pulmonary Embolism prognosis	
Variable	Point score
Cancer	+2
Heart failure	+1
Prior DVT	+1
Hypotension	+2
Hypoxemia	+1
DVT on ultrasonogram	+1

Geneva prognostic index has quantified and validated a predictive model of clinical outcome, based on clinical history and physical examination. Patients with higher the Geneva point score has more adverse out come.

Management Approach for Acute Pulmonary Embolism.



THROMBOLYSIS: It is life saving in patients with cardiogenic shock due to massive PE .For patients with contraindication to thrombolysis, embolectomy is done. Thrombolysis may prevent (1) The downhill spiral of right heart failure.(2) Prevent continued release of serotonin and other neurohormonal factors which worsen pulmonary hypertension.(3)Dissolve much of thrombus in pelvic and peripheral veins

ANTICOAGULATION: Heparin is corner stone of treatment for PE. Before heparin therapy is begun, risk factor for bleeding should be considered, thrombocytopenia, vitamin K deficiency, increasing age.

Intravenous Unfractionated Heparin schedule	
Variable	Action
Initial heparin bolus	80u/kg then 18u/kg/hr
PTT<35seconds	80u bolus then increase by 4u/kg/hr
PTT35-45seconds	40u bolus then increase by 2u/kg.hr
PTT46-70seconds	No change
PTT 71-90 seconds	decrease infusion rate by 2u/kg/hr
PTT >90seconds	hold infusion for 1 hour then decrease infusion rate by 3u/kg/hr

REVIEW ARTICLE

LOW MOLECULAR –WEIGHT HEPARIN:

- 1-ENOXAPARIN is given as 1.0 mg/kg twice daily or 1.5mg/kg once a day
- 2-DELTAPARIN given as 100u/kg twice daily, or 200 units /kg once a day.
- 3-TINZAPARIN 175u/kg once daily.

WARFARIN SODIUM: Warfarin is a vitamin K antagonist that prevent gamma carboxylation activation of coagulation factors II, VII, IX, X. The full anticoagulation effect will not be evident before 5 days, therefore it is overlapped with heparin for five day. The warfarin dose is monitored to keep PT INR between 2-3 INR during initial full intensification phase .

Optimal duration and intensity of Anticoagulation: The PREVENT trial showed that anticoagulation can be administered safely and effectively for an indefinite period with low intensity target INR of 1.5-2.0. With this regimen ,the incidence of PE and DVT was more than halved, and patient required INR testing once in 8 weeks.

INFERIOR VENA CAVAL INTERRUPTION: Two major indication for IVC filter are (1) Major haemorrhage that precludes anticoagulation.(2)Recurrent PE despite well documented anticoagulation.IVC filter prevent PE, not DVT.

PULMONARY EMBOLECTOMY: Emergency surgical embolectomy with cardiopulmonary bypass is re-emerging as an effective and often successful strategy for managing patients with massive PE, or patients who have contraindications to thrombolysis with moderate sized PE as well as those who require surgical excision of right atrial thrombus or closure of patent foramen ovale.

PREVENTION STRATEGIES for Pulmonary Embolism and Deep Venous Thrombosis

A-Hospitalization with medical illness: Enoxaparin 40 mg daily or Dalteparin 5000u daily or Graduated compression stocking(GCS) /Intermittent pneumatic compression (IPC) for patients with contraindication to anticoagulation and for very high risk patients Combine LMWH or UHF plus GCS /IPC B-General surgery: UFH q8h,first dose 2hr pre operatively, continued for 7 days, or LMWH once daily. C-Cancer surgery: Enoxaparin 40 mg daily, first 10-14hr pre operatively, for 28 days. D-Total hip replacement: Enoxaparin 40 mg daily, beginning preoperatively evening, continuing out of hospital for 21-28 Days or Dalteparin 2500 u 4 hr postoperatively then 5000u daily until hospital discharge or 35 days. E-Total Knee replacement: Enoxaparin 30 mg bid 12 -24 hour postoperative continued for average of 9days F-Hip fracture surgery :Fondaparinux 2.5mg first dose 4-8 hr post operative second dose >12 hour after the first dose then daily for 5-9 days.

CONCLUSION: In critical care and trauma units there is paucity of time for an complete investigational approach in rapidly deteriorating patients where clinical explanation of hemodynamic compromise is not acceptable. A high index of suspicion of pulmonary embolism can resolve the issue in certain patients and lead to a definitive diagnosis of pulmonary embolism. Therapy of pulmonary embolism is tailored according to the patient's clinical presentation, the anatomical extent of the embolus, presence of underlying cardiopulmonary disease, cardiac biomarkers such as troponin, D-Dimer and detection of right side heart dysfunction by physical examination, electrocardiogram and echocardiogram. High risk patients warrant thrombolysis or

REVIEW ARTICLE

embolectomy as primary therapy to dissolve or remove the embolus, in addition to anticoagulation to prevent recurrent venous thromboembolism. In low risk patients, anticoagulation should suffice. The important aspect is that we know there are less than 2% of hospital in our country who has in-house multidetector with 64 slice latest CT scan which is the gold standard for diagnosis of PE. Therefore it is important for critical care specialist and cardiologist to detect and recognize massive PE so that they can timely investigate aggressively with multidetector CT and manage by thrombolysis or embolectomy. On the other hand we can manage other grades of PE with Anticoagulation and supportive treatment, without CT scan and thrombolysis effectively and can save a large number of patients who form the majority of ambiguous PE.

REFERENCES:

1. Suarez JA, Meyerrose GE, Phisitkul S, Kennedy S, Roongsritong C, Tsikouris J, Huang SK. Review of catheter thrombectomy devices. *Cardiology*. 2004; 102: 11-15.
2. Wan S, Quinlan DJ, Agnelli G, Eikelboom JW. Thrombolysis compared with heparin for the initial treatment of pulmonary embolism: a meta-analysis of the randomized controlled trials. *Circulation*. 2004; 110: 744-749.
3. Schoepf UJ, Kucher N, Kipfmueller F, Quiroz R, Costello P, Goldhaber SZ. Right ventricular enlargement on chest computed tomography: a predictor of early death in acute pulmonary embolism. *Circulation*. 2004; 110: 3276-3280.
4. Torbicki A, Galie N, Covezzoli A, Rossi E, De Rosa M, Goldhaber SZ. Right heart thrombi in pulmonary embolism: results from the International Cooperative Pulmonary Embolism Registry. *J Am Coll Cardiol*. 2003; 41: 2245-2251.
5. Stein PD, Hull RD, Ghali WA, Patel KC, Olson RE, Meyers FA, Kalra NK. Tracking the uptake of evidence: two decades of hospital practice trends for diagnosing deep vein thrombosis and pulmonary embolism. *Arch Intern Med*. 2003; 163: 1213-1219.
6. Muller-Hulsbeck S, Grimm J, Leidt J, Heller M. In vitro effectiveness of mechanical thrombectomy devices for large vessel diameter and low-pressure fluid dynamic applications. *J Vasc Interv Radiol*. 2002; 13: 831-839

AUTHORS:

1. Sudeep Pathak
2. Renu Sharma

PARTICULARS OF CONTRIBUTORS:

1. Physician, Department of Cardiology Intensive, Narmada Hospital
2. Intensiveivist. Department of Anesthesiology Intensive, Narmada Hospital.

NAME ADDRESS EMAIL ID OF THE CORRESPONDING AUTHOR:

Dr. Sudeep Pathak.
3. Nupur Kunj E-3 Adena
Colony. Bhopal-462016
E-mail: pathakhospital@gmail.com

Date of Submission: 03/07/2013.
Date of Peer Review: 03/07/2013.
Date of Acceptance: 06/07/2013.
Date of Publishing: 12/07/2013