

**A CLINICOPATHOLOGICAL STUDY ON CERVIX**Jyothi V<sup>1</sup>, V. Manoja<sup>2</sup>, Sridhar Reddy K<sup>3</sup>**HOW TO CITE THIS ARTICLE:**

Jyothi V, V. Manoja, Sridhar Reddy K. "A Clinicopathological Study on Cervix". Journal of Evolution of Medical and Dental Sciences 2015; Vol. 4, Issue 13, February 12; Page: 2120-2126, DOI: 10.14260/jemds/2015/305

**ABSTRACT: BACKGROUND:** The infections of female genital tract are the "Gateway" predisposing the women not only to tubal infertility but also increase the risk of ectopic pregnancy. Now-a-days leucorrhoea is the common gynaecological problem in the women of all ages. Chronic nonspecific cervicitis is the commonest non-neoplastic lesion in all age groups, usually between 20-60 years, but rare before menarche or after menopause. Agents from bacterial, viral & metabolic diseases like diabetes mellitus, the infections are also due to local trauma, parturition, foreign bodies, diaphragm, pessaries and IUCD's. The HPV and HSV play a major role and strongly associated with carcinoma. The age at first coitus, smoking, parity is the other etiological factors. These factors cause dysplastic changes in epithelium leading to carcinoma. The present study is undertaken in view of disease sequelae of chronic cervicitis, Ca - in situ & Ca cervix. **AIM:** To analyse the cervical lesions and also early detection of carcinoma. **OBJECTIVES:** To determine the incidence, relation to age, parity, and etiological factors and to study different benign, premalignant and malignant lesions of cervix. **MATERIALS AND METHODS:** The present prospective study is done for a period of 3 years in the Dept. of Pathology, RIMS, Kadapa. Cases were analysed pathologically according to WHO classification. **RESULTS:** The commonest lesions were neoplastic - Large cell non-keratinising squamous cell carcinoma (36.9%) noted in the age group of 40-50 yrs. Next common lesion noted was non-neoplastic with chronic cervicitis (25.5%) noted in the age group of 30-40yrs. The 3<sup>rd</sup> common lesion noted was chronic endocerviitis (14.4%) seen in 40-50 yrs of age group. The next common were squamous intraepithelial lesions (5.6%) in the age group of 30-40yrs. Rare cases of leiomyomas of cervix, tuberculous cervicitis, actinomycosis, adenocarcinoma and adenosquamous carcinomas were noted. Precancerous and cancerous lesions were associated with increased parity and poor personal hygiene.

**KEYWORDS:** Clinicopathology , cervix, kadapa, (India).

**INTRODUCTION:** Reproductive tract infections (RTI's) are endemic in developing countries and entail a heavy toll on women. If untreated, RTI's can lead to adverse health outcomes such as infertility, ectopic pregnancy and increased vulnerability to transmission of the human immunodeficiency. Now-a-days leucorrhoea is the common gynaecological problem in the women of all ages. The prevalence of infection of cervix is more in developed and in developing countries. The women are usually exposed to infection at the time of menstruation causing inflammation leading to non-neoplastic and neoplastic diseases.

The etiology of cervicitis is variable. Chronic nonspecific cervicitis is the commonest non-neoplastic lesion in all age groups, usually between 20-60 yrs, but rare before menarche or after menopause. The bacterial and viral agents are the etiological agents along with the STD's causing the cervicitis. The other associated features causing cervicitis are bad hygiene tampons etc. tuberculous cervicitis though not common, can also contribute to 2- 6% of infections among women.

## ORIGINAL ARTICLE

---

Apart from bacterial, viral and metabolic diseases like diabetes mellitus, the infections are also due to local trauma, parturition, foreign bodies, diaphragm, pessaries and intrauterine contraceptive devices.

The human papilloma virus and Herpes simplex virus play a major role and strongly associated with carcinoma. The HPV causes spectrum of changes ranging from condyloma acuminatum, cervical intraepithelial neoplasia to invasive squamous cell carcinoma. There are more than 100 human papilloma viruses, about 40 viruses infect the female genital tract and 15 of them cause cervical cancer.

The neoplastic lesions of cervix are also commonly encountered in young women. The age of first coitus, smoking, parity are other etiological factors. These etiological factors causes dysplastic changes in epithelium leading to carcinoma.

The advancement of investigative procedures like Pap smear examination, colposcopy are very helpful to identify the non-neoplastic diseases of cervix. The Pap test is the simple and easy procedure to detect the inflammation and neoplastic diseases of cervix. The cervical biopsy plays an important contribution for much understanding of the disease process and clinicopathological correlation of the disease. The present study is undertaken in view of disease sequelae of chronic cervicitis, Ca.in situ & Carcinoma cervix.

**MATERIAL AND METHODS:** The present prospective study is done for a period of 3 years (Jan 2012- Dec. 2014) in the Dept. of pathology, RIMS, Kadapa. During the above period all the gynecological cervix biopsies obtained were analysed. In this study 603 cases were analysed pathologically. Relevant clinical data were collected. The specimens were received in 10% formalin. These specimens were subjected to detailed microscope study by hematoxylin and eosin staining. The lesions were analysed according to WHO classification. This study includes all non-neoplastic and neoplastic lesions of uterine cervix. The hysterectomy specimens were excluded in the present study.

**RESULT:** During this period of 3 yrs (Jan. 2012 – Dec. 2014), 6634 surgical specimens were received among them the total of 3828 gynecological specimens were received, among which total cervical biopsies were 603(15.75%). 268 cases (44.44%) of squamous cell carcinoma were noted. In them 223 cases (36.98%) were large cell non keratinizing squamous cell carcinoma, 40 cases (6.6%) were small cell and 2 cases (0.33%) were large cell keratinizing type. 260 cases (96.2%) were multi parous and 8 cases (3.8%) were nulliparous women. 203 cases (75.11%) showed poor personal hygiene. The common age group was 50-60 years. There were 2 cases (0.33%) of adenocarcinomas noted in the age group of more than 60 yrs, both were multiparous. One case (0.16%) of adenosquamous carcinoma was noted in 60 yr old multiparous women.

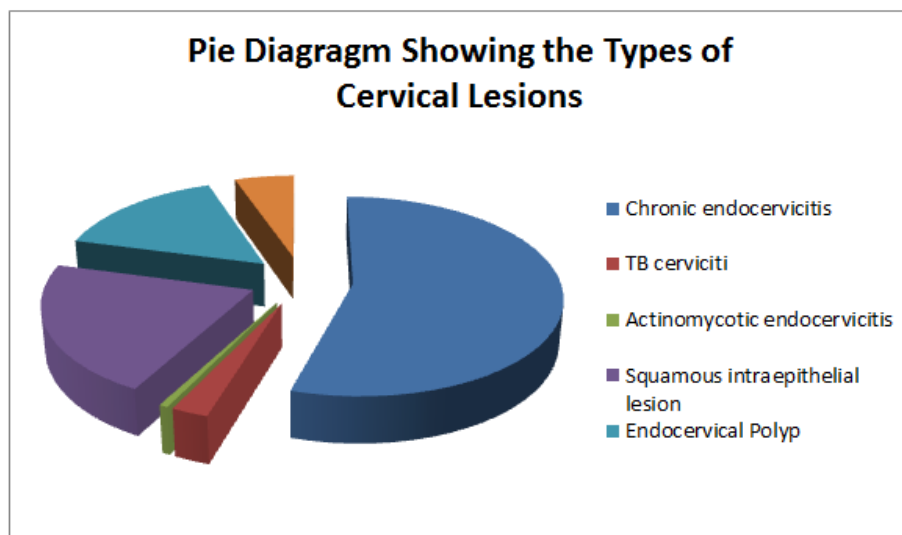
154 cases (25.5%) showed chronic nonspecific cervicitis. In them 14 cases (2.29%) showed koilocytic change, 3 cases (0.49%) showed nabothian cyst and 2 cases (0.33%) showed squamous metaplasia. 120 (78.2%) were multiparous, and 34 cases (21.7%) were nulliparous women, 97 patients (62%) were with poor personal hygiene. In 87 cases (14.4%) of endocervicitis, 79 cases (90.7%) were multiparous and 8 cases (9.3%) were nulliparous women and 65 cases (74.6%) were with poor hygiene. The common age group for all the inflammatory condition was between 20- 40 yrs. 34 cases (5.63%) showed squamous intraepithelial lesion (SIL). 18 cases (2.9%) of low grade SIL, and 16 cases (2.64%) of high grade SIL. Among these dysplastic cases 31 cases (91.1%) were multi

## ORIGINAL ARTICLE

parous and 3 cases (8.8%) were nulliparous women. The common age group was 30 – 40 yrs. Poor hygiene was noted in 19 cases (55.8%).

There were 25 cases (4.14%) of endocervical polyps with common age group of 40 – 50 yrs and 9 cases (1.49%) of leiomyoma of cervix. With common age group of 30 – 40 yrs. 4 cases (0.66%) of tuberculous cervicitis were noted in 20-30yrs age group presented with infertility. And one rare case of actinomycosis was noted in 35 yrs old women with history of long term use of IUCD's.

Type of lesion	Total no. of cases	Percentage
Chronic nonspecific cervicitis	154	25.5%
Chronic cervicitis with nebothian cyst	15	2.4%
Chronic cervicitis with squamous metaplasia	2	0.33%
Chronic cervicitis with koilocytic change	14	2.3%
Chronic endocervicitis	87	14.42%
TB cervicitis	4	0.66%
Actinomycotic endocervicitis	1	0.16%
Squamous intraepithelial lesion:	34	5.6%
Low grade SIL	18	2.9%
High grade SIL	16	2.6%
Endocervical Polyp	25	4.1%
Leiomyoma of cervix	9	1.4%
Squamous cell Carcinoms:	268	44.4%
Large cell keratinizing	2	0.33%
Large cell nonkeratinising	223	36.9%
Small cell carcinoma	40	6.6%
Adeno carcinoma	2	0.33%
Adeno squamous carcinoma	1	0.16%



## ORIGINAL ARTICLE

---

**DISCUSSION:** In the present study majority of uterine cervical lesions were neoplastic (44.4%), followed by non-neoplastic lesions. Most of the epidemiological studies of cervical neoplasia suggested direct relation with multiple sexual partners, early onset of sexual activity and HPV.<sup>[1]</sup> Chronic cervicitis was the commonest non neoplastic lesion (25.5%). It was observed in all age groups between 20-60yrs. This was diagnosed by the presence of heavy mixed infiltrate consisting of lymphocytes and histiocytes. It is rare before menarche or after menopause.<sup>[2]</sup>

Nabothian cyst was seen in 1.8% cases, showed cystically dilated endocervical glands, lined by flattened epithelium, filled with mucoid material and associated with chronic cervicitis.<sup>[3]</sup> Squamous metaplasia can sometimes be found in the endocervix, as it is composed of simple columnar epithelium, whereas the ectocervix is composed of stratified squamous non-keratinized epithelium.<sup>[4]</sup>

Koilocytosis or koilocytic atypia<sup>[5]</sup> was seen in 2.3% of cases, histologically shows squamous cells with nuclear enlargement (two to three times normal size), irregularity of the nuclear membrane contour, hyperchromatic nucleus with perinuclear halo, Collectively, these types of changes are called a cytopathic effect; various types of cytopathic effect can be seen in many different cell types infected by many different types of virus.<sup>[6],[7]</sup>

Tuberculous cervicitis was noted in 0.66% cases in the age group of 20-30yrs. It is significant that its gross appearance often closely resembles that of carcinoma. Tuberculosis of the cervix is rare and accounts for 0.1-0.65% of all cases of tuberculosis and 5-24% of genital tract TB.<sup>[8]</sup> These cases presented with infertility. It is involved in about 5-16% of cases of infertility among Indian women, though the actual incidence may be under-reported due to asymptomatic presentation of genital tuberculosis and paucity of investigations.<sup>[9,10,11]</sup>

One case of actinomycosis cervix (0.16%) was noted in 35yrolid women, related with long lasting IUCD usage.<sup>[12,13]</sup>

Squamous intraepithelial lesions showed mitotic activity in the parabasal layer noted in the age group of below 40yrs.<sup>[14]</sup> The World Health Organization classification<sup>[15,16]</sup> system was descriptive of the lesions, naming them mild, moderate or severe dysplasia or carcinoma in situ (CIS). The term, Cervical Intraepithelial Neoplasia (CIN) was developed to place emphasis on the spectrum of abnormality in these lesions, and to help standardize treatment.<sup>[16]</sup>

Endocervical polyps occur in 2-5% multigravida women in the age range of 30-59 yrs. The cause of cervical polyps is uncertain, but they are often associated with inflammation of the cervix.<sup>[17]</sup> Leiomyoma of cervix constitute 8% of uterine leiomyomas, appear as pedunculated masses in the endocervix.<sup>[18,19]</sup>

Large group of cases were neoplastic, common histological type was squamous cell carcinoma(44.44%) with sub-types,<sup>[20,21]</sup> large cell non-keratinising squamous cell carcinoma (36.9%), large cell keratinizing squamous cell carcinoma (0.33%), small cell carcinoma (6.6%), less common were adenocarcinoma (0.33%), and adenosquamous carcinoma (0.16%). Most of the cases were noted in the age group of 40-60yrs. 2 cases of adenocarcinoma (0.33%) were noted in the age group of 60 yrs.<sup>[22]</sup> One case of adenosquamous carcinoma was noted showing both glandular and squamous component.<sup>[23]</sup> Pre-cancerous and cancerous cervical lesions showed increased incidence in parous women<sup>[24]</sup> and also increase in age, illiteracy, poor sexual hygiene.<sup>[25]</sup> The prevalence and burden of cervical cancer is much higher among women of low Socioeconomic status, as well as among rural women in India.<sup>[26,27]</sup>

## ORIGINAL ARTICLE

---

The primary reason given for this is lack of access to screening and health services, and lack of awareness of the risk factors of cervical cancer. HPV infection and precancerous lesions go unnoticed and develop into full blown cancer before women realize they need to go for medical help. Moreover, due to difficulties of access and affordability, compliance to, and follow up of, treatment is much. Cervical cancer remains the second leading cause of cancer deaths among women in developing countries.<sup>[28]</sup> By 2030, WHO predicts that virtually all cervical cancer deaths - fully 98% - will occur in developing countries, furthering disparities between richer and poorer countries.<sup>[29]</sup>

**CONCLUSION:** The results reported here reflect a limited view of uterine cervical lesions and represent only an experience rather than true incidence. Cervical cancer still remains the major cause of cancer death worldwide. Meanwhile, scientific advancements have continued to improve secondary prevention methods. For example, a liquid-based Pap test with better detection results became available. Another significant development was the invention of an HPV DNA test to identify high-risk HPV strains in vaginal or cervical samples. The biggest technological game-changer has been the introduction of the HPV vaccine as a primary prevention tool. The U.S. Food and Drug Administration (FDA) has approved two variations - Gardasil in 2006 and Cervarix in 2009 - that provide protection against the viral strains that cause the large majority of cervical cancers.

Among the most important strategies being promoted in developing countries are single-visit or "screen-and-treat" approaches. Although screening efforts based on Pap smears have been introduced in several developing countries, many have achieved only limited success, for a number of reasons, including limited cytologic services and lack of follow-up diagnostic and treatment services. Despite much advancement, there remain serious challenges to lowering rates of cervical cancer cases and deaths. Still, the fact remains that cervical cancer is highly preventable and treatable, and many of the medical and technological tools to radically reduce - if not eliminate - cervical cancer as a killer of women are now in place and affordable. What is needed going forward is the leadership and commitment - among developed and developing country policymakers and donor agencies alike - to activate and sustain them.

### REFERENCES:

1. Arends, MJ; Whitley, MW Rapid real time PCR to distinguish between high risk human papilloma virus types 16 and 18 JOURNAL OF CLINICAL PATHOLOGY – MOLECULARPATHOLOGY, H.A. Cubie et al., “ Rapid real time PCR to distinguish between high risk human papilloma virus types 16 and 18”, JCLPATH-M, 54(1), 2001, pp.24-29.
2. Lowe D G 1988 carcinoma of cervix with massive eosinophilia. British journal of Obstetrics and Gynaecology 95:393-401.
3. Clement P B, Scully R E1992 carcinoma of cervix: histological types. Seminars in Oncology 9:251-264.
4. Kumar, Vinay; Abbas, Abul K.; Fausto, Nelson; & Mitchell, Richard N. (2007) Robbins Basic Pathology (8th ed.). Saunders Elsevier. pp. 716-720.
5. Nucci MR, Oliva E., ed. (2009). Gynecologic pathology: A volume in the series - Foundations in diagnostic Pathology. Elsevier Churchill Livingstone. ISBN 978-0-443-06920-8.

---

## ORIGINAL ARTICLE

---

6. DeMay, Richard M. (2007). Practical Principles of Cytopathology Revised. American Society for Clinical Pathology. ISBN 0-89189-549-3.
7. Krawczyk E, Suprynowicz FA, Liu X, et al. (September 2008). "Koilocytosis: a cooperative interaction between the human papillomavirus E5 and E6 oncoproteins". *Am. J. Pathol.* 173 (3): 682–8. doi:10.2353/ajpath.2008.080280. PMC 2527066. PMID 18688031.
8. Carter JR: Unusual presentations of genital tract tuberculosis. *Int J Gynaecol Obstet* 1990, 33:171-6.
9. Krishna UR, Sheth SS, Motashaw ND: Place of laparoscopy in pelvic inflammatory disease. *J Obstet Gynaecol India* 1979, 29:505-510.
10. Parikh FR, Naik N, Nadkarni SG, Soonawala SB, Kamat SA, Parikh RM: Genital tuberculosis - a major pelvic factor causing infertility in Indian women. *Fertil Steril* 1997, 67:497-500.
11. Roy A, Mukherjee S, Bhattacharya S, Adhya S, Chakraborty P: Tuberculous endometritis in hills of Darjeeling: a clinicopathological and bacteriological study. *Indian J Pathol Microbiol* 1993, 36:361-369.
12. Westhoff C. IUDs and colonization or infection with *Actinomyces*. *Contraception*. 2007;75 6 Suppl:S48–50.
13. Bowden GHW. *Actinomyces*, *Propionibacterium propionicus*, and *Streptomyces*. Medical Microbiology, University of Texas at Galveston. <http://www.utmb.edu/gsbs/microbook/ch034.htm>. Accessed 2010 February 5.
14. Meisels A. Cytologic diagnosis of human papilloma virus. Influence of age and pregnancy stage. *Acta cytol* 1992: 36:480-2.
15. "Cancer Research UK website". Retrieved 2009-01-03.
16. DeMay, M (2007). Practical principles of cytopathology. Revised edition. Chicago, IL: American Society for Clinical Pathology Press.
17. "Cervical Polyps" (PDF). Doncaster and Bassetlaw Hospitals (NHS). Retrieved 2007-10-21.
18. Tiltman AJ. Leiomyomas of the uterine cervix: a study of frequency. *Int. J. Gynecol. Pathol.* 1998; 17 (3): 231-4.
19. Okamoto Y, Tanaka YO, Nishida M et-al. MR imaging of the uterine cervix: imaging-pathologic correlation. *Radiographics*. 23 (2): 425-45.
20. Garcia A Hamid O, El-Khoueiry A (2006-07-06). "Cervical Cancer". eMedicine. WebMD. Retrieved 2007-12-02.
21. Dolinsky, Christopher (2006-07-17). "Cervical Cancer: The Basics". OncoLink (Abramson Cancer Center of the University of Pennsylvania). Retrieved 2007-12-02.
22. Christopherson W M, Neelson N, Gray LA 1979, Noninvasive precursors of adenocarcinoma and mixed adenosquamous carcinoma of cervix uteri. *Cancer* 44: 975-983.
23. Kudo R, Sasano H, Koizumy M, Orenstin JM, Silverberg SG 1990 immunohistological comparison of new monoclonal antibody IC5 and carcinoembryonic antigen in the differential diagnosis of adenocarcinoma of uterine cervix. *International journal of gynaecological pathology*: 9: 325-336.
24. Dutta PK: a case control study of cancer cervix patients attending Command Hospital, Pune. *Indian journal of cancer*, June 1990; 27:101-6.
25. Varghese C, Amma NS, Chitrathara K, Dhakad N, Rani P, Malathy L. et. al. Risk factors for cervical dysplasia in Kerala, India. *Bulletin of the World Health Organization*, 1999, 77 (3).



## ORIGINAL ARTICLE

26. Vallikad E, "Cervical Cancer: The Indian Perspective", International Journal of Gynecology Obstetrics, 95(1) (November 2006): S215-S233.
27. Kurkure AP, and Yeole BB, "Social inequalities in cancer with special reference to South Asian countries", Asian Pacific Journal of Cancer Prevention, 7(1) (Jan-March 2006): 36-40.
28. Ferlay J et al, GLOBOCAN 2008 v1.2, Cancer Incidence and Mortality Worldwide: IARC CancerBase No. 10, Lyon, France: International Agency for Research on Cancer, 2010, <<http://globocan.iarc.fr>>, accessed Feb. 23, 2012.
29. Alliance for Cervical Cancer Prevention (ACCP), Cervical Cancer Prevention Fact Sheet, Recent Evidence on Cervical Cancer Screening in Low-Resource Settings, Seattle, WA: ACCP, 2011, <[http://www.alliance-cxca.org/files/ACCP\\_cxca\\_screening\\_2011.pdf](http://www.alliance-cxca.org/files/ACCP_cxca_screening_2011.pdf)>, accessed Feb. 23, 2012.

**AUTHORS:**

1. Jyothi V.
2. V. Manoja
3. Sridhar Reddy K.

**PARTICULARS OF CONTRIBUTORS:**

1. Assistant Professor, Department of Pathology, RIMS, Kadapa, A. P.
2. Senior Resident, Department of Pathology, KMC, Kurnool, A. P.
3. Assistant Professor, Department of Pathology, RIMS, Kadapa, A. P.

**FINANCIAL OR OTHER****COMPETING INTERESTS:** None**NAME ADDRESS EMAIL ID OF THE CORRESPONDING AUTHOR:**

Dr. Jyothi V.  
H. No. 1/2618, LIG,  
APHB Colony, Kadapa-516004, A. P.  
E-mail: vaddadijyothi@gmail.com

Date of Submission: 20/01/2015.  
Date of Peer Review: 21/01/2015.  
Date of Acceptance: 04/02/2015.  
Date of Publishing: 10/02/2015.