

## REVISION ENDOSCOPIC DCR SURGERIES: OUR EXPERIENCE

N. Venkat Ram Reddy<sup>1</sup>, K. Anjani Kumari<sup>2</sup>, T. Shankar<sup>3</sup>, Manish Kumar<sup>4</sup>, Juveria Majeed<sup>5</sup>

<sup>1</sup>Associate Professor, Department of ENT, Osmania Medical College/Govt. ENT Hospital, Koti, Hyderabad.

<sup>2</sup>Assistant Professor, Department of ENT, Osmania Medical College/Govt. ENT Hospital, Koti, Hyderabad.

<sup>3</sup>Professor, Department of ENT, Osmania Medical College/Govt. ENT Hospital, Koti, Hyderabad.

<sup>4</sup>Assistant Professor, Department of ENT, Osmania Medical College/Govt. ENT Hospital, Koti, Hyderabad.

<sup>5</sup>Resident, Department of ENT, Osmania Medical College/Govt. ENT Hospital, Koti, Hyderabad.

**ABSTRACT:** Patients presenting with “Wet eye” after dacryocystorhinostomy are quite challenging, to treat the recurrence and to find an explanation for the failure of surgery. Surgical treatment for lacrimal obstruction is Dacryocystorhinostomy (DCR) which involves marsupialisation of lacrimal sac into nasal cavity. DCR can be performed externally or endoscopically. The results of both the techniques are almost similar ranging between 85 - 95% in the literature. A prospective study of 40 cases of recurrent dacryocystitis following both endoscopic and external DCR were analysed for probable causes for recurrence in primary endoscopic DCR and external DCR surgery and results of the revision surgery are evaluated.

**OBJECTIVES:** This study is aimed to determine the probable causes of failure of primary DCR surgery and its subsequent management. The study involves the role and usefulness of the powered instrumentation, silicon stent, Mitomycin C application in the revision DCR surgeries.

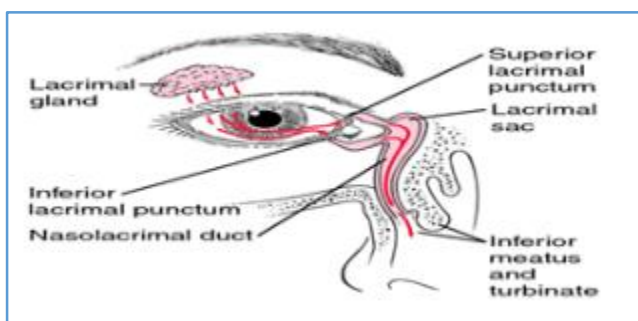
**MATERIALS AND METHODS:** A prospective study was conducted on 40 cases of recurrent dacryocystitis of which 10 cases are following primary external DCR surgery and 30 cases following primary endoscopic DCR surgery. All the 10 cases of recurrent dacryocystitis following external approach were referred from Sarojini Devi eye hospital Hyd-Bad and 30 recurrent Dacryocystitis following endoscopic DCR surgery are picked from Govt ENT hospital, Koti and Nightingale hospital, Hyderabad between Jan. 2009 to Jan. 2014.

**RESULTS:** In 62.5% of the cases, the cause for the failure is inadequate exposure of the lacrimal sac. 15% had uncorrected deviated nasal septum which could be the cause for obstruction of neo stoma postoperatively. 12.5% had associated nasal pathology, such as nasal polyps and sinusitis. In 5%, faciomaxillary trauma was the cause. 2.5% had atrophic rhinitis and another 2.5% mibomian cancer as the cause for recurrence.

**KEYWORDS:** Recurrent Dacryocystitis, Epiphora, Revision Surgery by Endoscopic DCR, Neo-Ostium.

**HOW TO CITE THIS ARTICLE:** N. Venkat Ram Reddy, K. Anjani Kumari, T. Shankar, Manish Kumar, Juveria Majeed. “Revision Endoscopic DCR Surgeries : Our Experience”. Journal of Evolution of Medical and Dental Sciences 2015; Vol. 4, Issue 93, November 19; Page: 15853-15856, DOI: 10.14260/jemds/2015/2300.

**INTRODUCTION:** A watery eye is a common complaint among ophthalmic patients. Among patients attending eye clinics, between 3-4% complain of excessive tears.<sup>1,2</sup> any mechanical or functional abnormality in the production, distribution, and drainage of tears disrupts this process.



**Fig. 1: Anatomy of Lacrimal System**

Financial or Other, Competing Interest: None.

Submission 24-10-2015, Peer Review 26-10-2015,

Acceptance 10-11-2015, Published 18-11-2015.

Corresponding Author:

Dr. N. Venkat Ram Reddy,

Associate Professor,

Department of ENT,

Govt. ENT Hospital, Koti,

Hyderabad, Telangana State.

E-mail: venkatramreddyn@yahoo.com

DOI:10.14260/jemds/2015/2300.

Conventional dacryocystorhinostomy (DCR) involves external approach with skin incision medial to medial canthus of eye, dissection through periosteum on the lateral aspect of the nose, extensive removal of bone at lacrimal fossa and incision of lacrimal sac and nasal mucosa to create a fistula in the nasal cavity.<sup>3</sup> The first description of the external DCR procedure was demonstrated by Adeo Toti in 1904.<sup>4</sup> This was the gold standard for nearly over a century. The preoperative workup includes lacrimal syringing and plain x-ray paranasal sinuses to exclude any problem of sinusitis.

The advent of rigid nasal endoscopes<sup>5</sup> brought a fresh consideration of lacrimal surgery. The unprecedented views of nasal cavity and the magnificent illumination provided by endoscopes avoided facial incision which give rise to scar and unnecessary dissection of both orbicularis muscle and orbital periosteum. Ever since the endoscopic endonasal DCR was popularised by many authors two decades ago for obvious reasons of avoidance of facial scars, relative ease with which the surgery is executed even in medically unfit patients for general anaesthesia, for external DCR surgery and day care surgery.<sup>6,7</sup>

In case of recurrence the revision surgery is more easily done by endoscopic approach. Above all it preserves lacrimal pump mechanism unlike in external DCR surgery and final results are as good as external approach.<sup>8</sup> In today's practice the bulk of cases of “chronic epiphora” are still dealt by ophthalmologists.

Most of the surgeries done by ENT surgeons are referred by eye surgeons. The recurrence rate, whichever approach (External or internal) is in the range of 10 -20% in primary surgery. There are not many studies in the literature of a case series of revision surgery for recurrent dacryocystitis. In this regard we conducted a study of 40 cases of recurrent dacryocystitis cases done by both approaches (endoscopic and external).<sup>9,10</sup>

Patients with epiphora after dacryocystorhinostomy (DCR) can be quite challenging with regard to diagnosing the cause of surgical failure and planning and execution of surgery at second attempt. Both the surgeon and patient are understandably quite frustrated with a watering eye after DCR surgery.<sup>11,12</sup> Epiphora or watering of eye is the most common presenting symptom, followed by pus discharge and abscess formation.<sup>13</sup> The preoperative workup of recurrent cases was done and preoperative findings are analysed and post op results are evaluated.

**MATERIALS AND METHODS:** A prospective study was conducted on 40 cases of recurrent dacryocystitis of which 10 cases are following primary external DCR surgery and 30 cases following primary endoscopic DCR surgery. All the 10 cases of recurrent dacryocystitis following external approach were referred from SD eye hospital Hyd-Bad. 30 cases of Recurrent dacryocystitis following endoscopic DCR surgery are picked from Govt ENT hospital, Koti and Nightingale hospital, Hyderabad between Jan 2009 to Jan 2014. The youngest in our study is 7 yrs old while oldest was 79 yrs. Males: 12, Females: 28, Rt sided recurrence: 14, Lt sided recurrence: 24, Bilateral :2

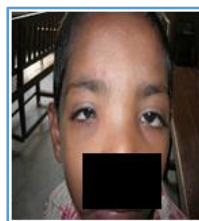All patients presented with epiphora beyond 3 months after the primary surgery, were examined thoroughly to establish the etiology and to exclude the causes of hyperlacrimation. The diagnosis of recurrence was established on the basis of clinical examination by doing the regurgitation test and lacrimal syringing. The cases of presacral block (punctal stenosis, lid abnormality and facial palsy etc) were excluded from study.

In selected cases dacryocystogram was done to exclude "Canalicular block" and functional block due to muscle abnormality to establish the diagnosis of NLD obstruction. Thorough examination of nose and paranasal sinuses was done to exclude the nasal and sinus problems like sinusitis, polyps, DNS, Airway patency, accessibility to the site of operation, scarring due to primary surgery etc.

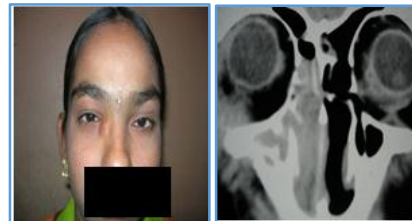All the patients underwent CT scan plane 5mm cuts, to exclude sinonasal problems. Atrophic rhinitis cases were given medical treatment for 6 weeks till mucosa is healthy and nasal cavity is free from crusts before taken up for revision surgery. Diagnostic nasal endoscopy is done with 30 degrees nasal endoscope in all cases to ascertain the accessibility to the site of lacrimal sac, presence of scarring/adhesions, DNS, polyps, sinusitis etc. Depending upon the pathology concomitant septal surgery, sinus surgery (FESS), adhesion release, wedge resection of the middle turbinate if necessary to expose the scarred area of lacrimal fossa.

Most of the cases were done under local anaesthesia (4% xylocain with 1 in 30,000 adrenaline half an hour before surgery as surface anaesthesia. 1% xylocain with 1 in 1 lakh adrenalin for infiltration at site of operation) except children, apprehensive adults with extensive sinus pathology. Of the total 40 cases, in 62.5%, the cause for the failure is

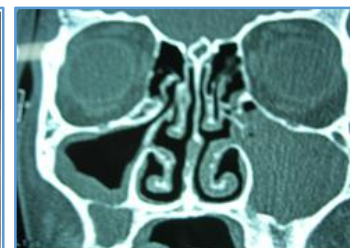
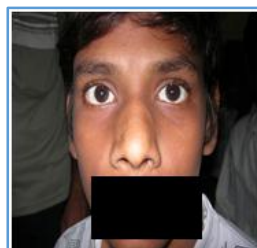inadequate exposure of the lacrimal sac. 15% had deviated nasal septum which could be the cause for obstruction of neo stoma postoperatively. 12.5% had associated nasal pathology, such as nasal polyps and sinusitis. In 5%, faciomaxillary trauma was the cause. 2.5% had atrophic rhinitis and another 2.5% mibomian cancer as the cause for recurrence.



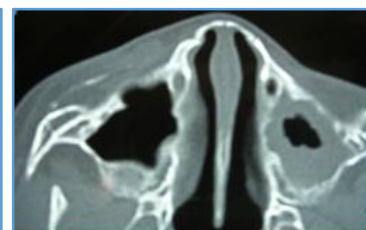
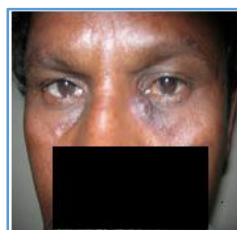**Fig. 2: Faciomaxillary Injury**



**Fig. 3: Mibomian cancer**



**Fig. 4: Lt. Dacryocystitis with sinusitis**



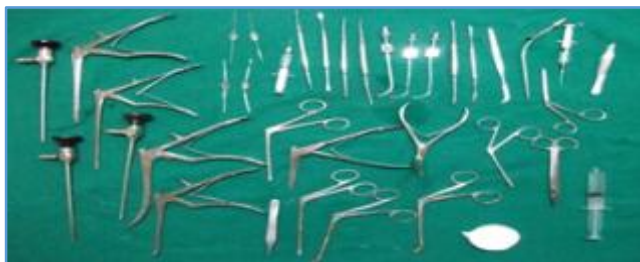**Fig. 5: Ext. DCR lacrimal abscess**

**SURGICAL TECHNIQUE:** Incision is made on the lateral wall of nasal mucosa with a 12 number conventional scalpel blade. A curvilinear incision is made at 8 to 10 mm above the middle concha insertion point, in the lateral nasal wall few mm anterior to the base of uncinata and moving on anteriorly until about 10mm over the frontal process of the maxilla. Following that, we raise the mucosal flap, keeping it always in contact with the bone. A Kerrison's punch forceps is utilized to start removing the stronger portion of bone in the lacrimal fossa. 5mm DCR burr (Xomed microdebrider) was used in most of the cases to expose the lacrimal sac adequately.

**The operative surgical principles that are followed during revision surgery include:**

- Mucosal preservation and use of microdebrider.
- Adequate bone removal (3mm, 4mm Kerrison's punches & 5mm DCR burr)
- Prevent exposure of raw bone
- Optimal lacrimal window was created ranging between 5-8mm.
- Horizontal incisions at cranial and caudal end of the sac
- Posterior flap is approximated with nasal mucosal flap. No tamponade (Nasal packing) in most cases except in cases of adhesion release, and concomitant sinus surgery merocel packing was done for 24hrs.

Microdebrider, DCR burr is used in most of the cases, DCR stent is done in 8 revision cases where the sac was not well defined. MitomycinC was applied in 7 cases. The patients were discharged the following day and put on antibiotics, antiinflammatory and nasal decongestans and antibiotic + steroid eye drops for 3-4 wks.



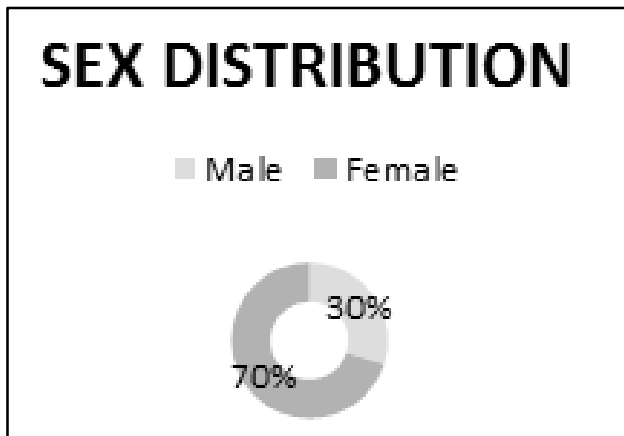
**Fig. 6: Instruments Used In Endoscopic Endonasal DCR**

**FOLLOW UP:** The patients were instructed to do digital massage on external aspect of sac and alkaline nasal douch every morning for 2 weeks following surgery to prevent crusting and good healing. Patients were advised to come for follow up and endoscopic examination at 1week, 3<sup>rd</sup> week, 6 weeks, 3months to see and remove any granulations and synechia formation and record approximate size of the rhinostoma.

**OBSERVATIONS AND DISCUSSION:** Observations based on prospective study done on 40 patients attending Govt. ENT Hospital and Nightingale Hospital from Jan 2009 to Jan 2014.

**SEX DISTRIBUTION:**

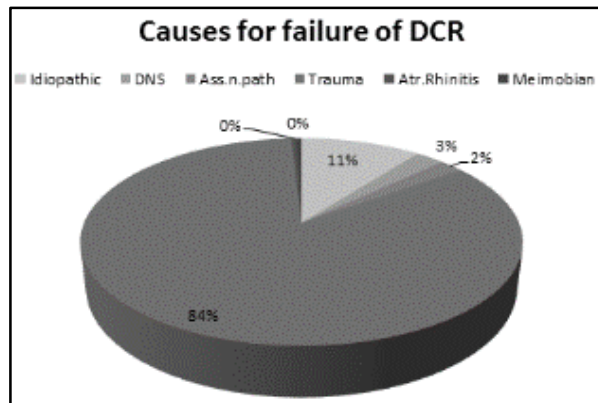
Males – 12  
Females- 28



**Fig. 7: Sex Distribution**

**CAUSES OF FAILURE OF PREVIOUS DCR:**

Inadequate lacrimal sac exposure:	25
Uncorrected DNS :	6
Chronic rhinosinusitis/ polyps:	5
Fasciomaxillary injury:	2
Atrophic rhinitis:	1
Malignancy (mibomian carcinoma):	1



**Fig. 8: Showing Causes for failure of DCR**

**FOLLOW UP ASSESSMENT: Of 10 cases of revisions following primary external DCR surgery:**

- 7 cases there was small scarred rhinostoma and there was inadequate bone removal
- 3 cases although the rhinostoma was patent there seemed to be persistent epiphora, probably due to lacrymal pump failure due to injury to orbicularis muscle and medial palpebral ligament.

**RESULTS OF REVISION DCR: 40 total cases**

29: relief from epiphora- 72.5% (Successful revision surgery)

11: no relief -27.5% (Unsuccessful revision surgery)

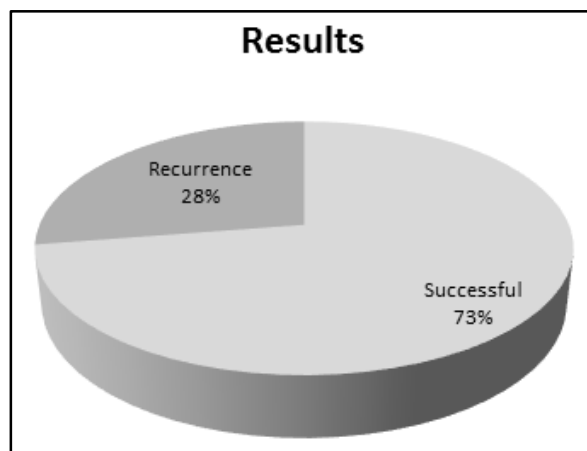
2: fasciomaxillary injury

1: atrophic rhinitis

1: mibomian carcinoma

3: silicon stent

4: fibrosis & stenosis



**Fig. 9: Showing Outcome of Revision Endoscopic Endonasal DCR**

**CONCLUSION:**

- Revision endoscopic DCR is a surgical challenge, especially to identify the Probable cause of recurrence.
- Execution of meticulous surgical technique and good post op care has longway to yield good results.
- CT scan of paranasal sinuses is extremely useful in the evaluation of cases to identify cause of failure in primary DCR surgery.

- Microdebrider and DCR burr are extremely useful tools in revision surgery for mucosal preservation exposure of sac completely and adequately and prevents exposure of raw bone so as to make adequate sized rhinostoma.
- Silicon stenting found to yield disappointing results( Allen & Berlin 1990).<sup>19,20</sup> can cause punctual erosion and scarring.(Anderson and Edward in 1992)
- Application of Mitomycin C during Revision surgery is found to be extremely useful in preventing closure of Rhinostoma.
- Overall success rate is about 72.5%.

#### REFERENCES:

1. Jacob basil H. symptomatic epiphora.Br J of oph 1959; 43:415-34.
2. Welham RA. Management of Unsuccessful lacrimal surgery, Brazilian Journal of Ophthalmology. Feb 1987; 71(2): 152–157.
3. Camara JG, Bengzon AU, Henson RD. The safety and efficacy of mitomycin C in endonasal endoscopic laser-assisted dacryocystorhinostomy. Ophthal Plast Reconstr Surg 2000; 16:114–118.
4. Jun Ho Yoo, Hwa Lee, Hyung Ho Shin, Jong Mee Lee, Min Wook Jang, Se Hyun Baek. The Effects of Transcanalicular Diode Laser-Assisted Revision Surgery for Failed Dacryocystorhinostomy. J Korean Ophthalmol Soc. 2012 Apr; 53(4):493-498.
5. McDonogh M, Meiring H. Endoscopic transnasal dacryocystorhinostomy. J Laryngol Otol. 1989; 103:585–7. [PubMed]
6. Rinki Saha, Anuradha Sinha and Jyoti Prakash Phukan Endoscopic versus external approach dacryocystorhinostomy: A comparative analysis Niger Med Journal. 2013 May-Jun; 54(3): 165–169.
7. Khan MK, Hossain MA, Hossain MJ, Al-Masud A, Rahman MZ. Comparative study of external and endoscopic endonasal dacryocystorhinostomy for the treatment of chronic dacryocystitis. JAFMC Bangladesh.2011; 7:15–7.
8. Zhou W, Zhou M, Li Z, Wang T. Endoscopic intranasal dacryocystorhinostomy in forty-five patients. Chin Med J (Engl) 1996; 109:747–8. [PubMed].
9. Grenman R, Puukka P, Seppa H. Prospective randomized comparison of endonasal endoscopic dacryocystorhinostomy and external dacryocystorhinostomy. Ophthalmology 1998; 105:1106–1113.
10. Dutton J J. Orbital Nerves. in: J.J. Dutton (Ed.) Atlas of Clinical and Surgical Orbital Anatomy. Saunders, Philadelphia, PA; 1994: 33–64.
11. Hartikainen J, Antila J, Varpula M, Puuka P, Seppa H, Grenman R. Prospective randomized comparison of endonasal endoscopic dacryocystorhinostomy and external dacryocystorhinostomy. Laryngoscope 1998; 108: 1861–1866.
12. Adam J. Cohen, F. Campbell Waldrop, and David A. Weinberg. Revision Dacryocystorhinostomy. Springer/242/244-254.
13. Welham RA, Wulc AE Management of unsuccessful lacrimal surgery. Br J Ophthalmol. 1987 Feb; 71(2):152-7.