

ELASTIC-STABLE INTRAMEDULLARY NAILING OF MIDCLAVICULAR FRACTURES IN ADULTS: A NOVEL TREATMENT OPTIONS. B. Kamareddy¹, Anand Garampalli², Sanjeevi Bharadwaj³**HOW TO CITE THIS ARTICLE:**

S. B. Kamareddy, Anand Garampalli, Sanjeevi Bharadwaj. "Elastic-Stable Intramedullary Nailing of Mid Clavicular Fractures in Adults: A Novel Treatment Option". Journal of Evolution of Medical and Dental Sciences 2014; Vol. 3, Issue 42, September 08; Page: 10595-10603, DOI: 10.14260/jemds/2014/3381

ABSTRACT: BACKGROUND: This prospective consecutive case series was done to evaluate indications, technical pearls and pitfalls and functional outcomes of elastic stable intramedullary nailing of displaced mid clavicular fractures and the effectiveness of the titanium elastic stable intramedullary nails in the surgical treatment of the mid clavicular fractures in adults. **MATERIALS & METHODS:** A total of 80 patients (60 men, 20 female) were included in this study. Constant score and radiographs were evaluated after 1 and 6 weeks, 3 months and 6 months in 80 patients. Mean age was 28 years. **RESULTS:** Length of incision, operation time, blood loss and duration of hospital stay were significantly less. The average follow-up was 17 months. Mean operation time was 62 minutes. Open reduction through an additional small incision was necessary for some fractures. Mean hospital stay was 1.2 days. The Constant score averaged 81 after 1 week, 96 after 6 weeks and 98 after 6 months. Compared to the contralateral side, average shortening of the clavicle was 1.7 mm. **CONCLUSION:** Elastic Intramedullary Nailing provided a good restoration of the length of the clavicle allowing immediate active mobilization and early return to normal activity with excellent functional results.

KEYWORDS: Clavicle fractures; Intra medullary nailing; elastic stable intramedullary nails.

INTRODUCTION: Fracture of the clavicle is a frequently seen injury which represents about 10-15% of all fractures in adults.⁽¹⁾ In most cases a fall with a direct trauma causes the clavicle to fracture. About 80% of all clavicular fractures involve the middle third of the bone.⁽²⁾

Standard treatment for this fracture pattern is non-operative, using an arm sling or figure-of-eight bandage for external fixation. For open fractures, imminent skin perforation, neurovascular involvement, floating shoulder or in combination with multiple ipsilateral rib fractures, open reduction and plating is generally accepted.⁽³⁾

While fracture healing and functional outcome is generally good for non-operatively treated mid clavicular fractures, a poor cosmetic result due to shortening and angulation is not uncommon.⁽²⁾ Non-unions occur in an average of 5%.⁽³⁾

Furthermore decreased shoulder function due to clavicular shortening of more than 1-2 cm after non-operative fracture management has been reported.^(5,12) Whereas a mild decrease in shoulder function is easily tolerated by most patients, restoration of the clavicle length and early return to full activity with unimpaired function is of great importance for every individual irrespective of the profession or socio-economic group they belong to.

As non-operative treatment is successful in most cases for this fracture, relevant clinical benefit may be limited to a selected group of patients with a high demand on shoulder function.

ORIGINAL ARTICLE

Elastic stable intramedullary nailing (ESIN) of the clavicle is a minimally invasive procedure and aims at exact restoration of the clavicular length with early return to full activity, with a good cosmetic result and minimal morbidity.

MATERIALS AND METHODS: Between June 2012 and June 2014, a total of 80 patients with closed displaced midclavicular fractures were admitted in our hospital. Patients were recruited according to particular inclusion and exclusion criteria. Informed consent was obtained. Only isolated closed fractures of the midclavicle (OTA 06-A/B) with a clavicular shortening of at least 1 cm and/or lack of inter fragmentary contact were included.

Patients between the age of 16-50 years for whom impairment of shoulder function would interfere with their activities were accepted for the study. Patients were excluded if they had fractures with marked comminution, duration of more than 4 weeks, open fractures, pre-existent morbidity of the ipsilateral arm, shoulder or hand, presence of neurovascular injury, and ipsilateral injuries. Radiographs of the fractured clavicle were obtained in anteroposterior and 45° cephalic tilt views. No additional imaging for the assessment of the clavicle was performed.

Operation time, intraoperative technical problems, local complications and functional outcome were analyzed. The patients were encouraged to use their shoulder without restriction immediately after surgery. Standard analgesia was given (Ibuprofen 500 mg and Tramadol 50 mg) when required.

Clinical examinations and radiological studies were performed on days 7 and 42, at 3 and 6 months and after hardware removal. Clavicular length was clinically measured when bony consolidation was evident (distance from the center of the jugular fossa to the lateral tip of the acromion) and compared with the contralateral side. Functional outcome was assessed using the Constant shoulder score.⁽⁶⁾ Hardware removal was performed once bony consolidation was evident or later according to the patient's preference.

SURGICAL PROCEDURE: The intervention was performed under inter scalene & superficial cervical nerve blocks. Standard antibiotic single shot prophylaxis (Cefuroxime 1.5 g iv.) was given. The patient was placed on a radiolucent operating table in the supine position. A towel roll was placed between the scapulae to provide extension of the shoulder girdle. It is important to scrub the whole ipsilateral upper extremity to allow free manipulation of shoulder and arm during the procedure. A single imagine intensifier was used for the procedure.

A short skin incision of about 1cm was made just lateral to the sternoclavicular joint centered above the medial end of the clavicle (Fig. 1). The medullary cavity of the clavicle was opened using a k-wire about 1cm lateral to the sternoclavicular joint. The k-wire was pointed laterally in-line with the clavicle and angled at about 30 degrees to the coronal plane (Fig. 2). Care was taken not to perforate the dorsal cortex in order to avoid major complications.

Once the medullary cavity was opened, a 3mm awl was used to widen the entry point (Fig. 3) and a preselected ESIN was carefully inserted. The implanted nails had diameters between 2.0 and 3.0 mm according to the patient's dimensions. No reaming was necessary. The nail was fixed in a universal chuck with a T handle and advanced with oscillating movements (Fig. 4) once the Ti nail reached the fracture site (Fig. 5), closed reduction by direct pressure on the fragments combined with manipulation of the arm was performed.

ORIGINAL ARTICLE

Usually reduction was facilitated when a small pointed reduction forceps was applied per cutaneously to the lateral fragment. The fracture was bridged using the rounded and angled tip to guide the Ti nail into the lateral fragment. To determine the exact position of the Ti nail, fluoroscopy with true perpendicular views is crucial. In some cases closed reduction may not be accomplished. In these cases a short incision directly over the fracture site (2 cm) with minimal dissection is suggested to reduce the fracture.

The ESIN was then pushed gradually into the distal part of the clavicle close to its extremity by oscillating it. The protruding medial end of the nail was left out of the cortex and shortened close to its entry point into the bone followed by wound closure.

RESULTS: A total of 80 patients (60 men, 20 female) qualified for the study according to the inclusion criteria between 06/2012 and 06/2014. No potential candidate refused to enter the study by preferring non-operative treatment. Mean age was 28 years (range: 16 to 40). The mechanism of injury was a direct trauma to the shoulder in 76 patients, 4 patients fell on their extended arm.

Sixty four fractures were caused by road traffic accidents and 16 were sports injuries. The fractures were graded according to the Orthopaedic Trauma Association classification (OTA). There were sixteen 06-A1, twenty four 06-A2 and sixteen 06-A3 fractures in our series. Wedge fractures were found in 24 patients (3 06-B2 and 3 06-B3 fractures).

The operation was performed 6 days (1-26 days) after trauma. Only Ti nail diameters of 2.0, 2.5 and 3.0 mm were used. Closed reduction was possible in 40 cases. A short incision of about 2 cm above the fracture site was necessary to obtain fracture reduction in 10 patients. Mean operation time was 62 minutes (range: 20 to 123). Operation time was much shorter when closed reduction was successful compared with the open technique 39 minutes (range: 20 to 60) vs. 84 minutes (range: 37 to 123).

No correlation was found between reduction technique and fracture classification. When the operation was delayed for more than 7 days closed reduction was never achieved suggesting that patients benefit from an early intervention with better chances for successful closed reduction. A smaller implant should be chosen if it is not possible to advance the Ti nail by oscillating movements only. No metal fatigue failure was observed with either size of implant. No other intraoperative complication occurred. Hospital stay was 1.2 days (range: 1 to 3).

Post-operatively, painless shoulder range of movements was possible (Fig.6) in all patients.

All the patients could be followed according to the study protocol. Mean follow-up was 17 months (range: 12 to 24). No infection or migration of the Ti nail was observed. All fractures healed, no delayed or non-union was observed.

Time to healing was 7.7 weeks (range: 6 to 12) determined by visible osseous callus formation on the radiographs. Clavicular shortening was 1.7 mm (range: 0 to 7) compared with the contralateral side measured after fracture healing. Hardware removal was performed electively in 68 patients within 18 to 56 weeks after implantation (mean: 29 weeks) as day cases.

The Constant shoulder score averaged 81 (range: 37 to 96) after 7 days. Mean Constant shoulder score was 96 (range: 85 to 100) after 6 weeks. After 6 months and after hardware removal, all patients (n = 80) presented with basically normal shoulder function (mean: 98, range: 93 to 100).

Until the date of the last clinical follow-up (mean: 17 months, range: 12 to 24) no re fracture was observed. All patients returned to their activities within four weeks after the procedure.

ORIGINAL ARTICLE

DISCUSSION: Simple closed fracture of the mid third clavicle is a frequent injury and mostly treated non-operatively. Although fracture healing and functional outcome is usually satisfactory,⁽⁷⁾ significant shortening with mal-union or non-union is described in the literature.^(8,9,10) Whereas some authors report good functional results in patients with clavicular shortening,⁽¹¹⁾

Matis et al.⁽¹²⁾ found an impaired shoulder function in half of their patients with a shortening of 1cm and in 100% when shortening was 2 cm. Hill et al⁽⁴⁾ reported a clear correlation of non-unions (15%) with clavicular shortening of more than 2 cm. They found unsatisfactory results in 31% of completely displaced mid clavicular fractures after non-operative treatment. Beside non-union residual persistent pain, brachial plexus irritation and poor cosmetic results were observed.⁽¹³⁾

According to Jupiter and Leffert,⁽⁸⁾ the initial displacement is one of the most predisposing factors in the development of non-unions. Furthermore non-operatively treated clavicular fractures cause pain, discomfort and disability which are often not adequately appreciated by the treating physician.⁽¹⁴⁾

For patients with a high demand on shoulder function and good cosmetic appearance, such prospects are barely acceptable. To meet these patient's expectations a minimally invasive procedure which provides restoration of the clavicular length combined with early resumption of activities, complete functional recovery and a good cosmetic result may be an attractive alternative to non-operative management.

Open reduction with plate fixation is the operative standard treatment for clavicular shaft fractures.⁽⁹⁾ Potential complications include deep infection, injury to the sub clavian vessels, screw loosening with implant failure, non-union and re-fracture after hardware removal. Bostman et al⁽¹⁵⁾ reported a complication rate of 23% following plate fixation. The cosmetic results are unsatisfactory caused by an inevitable and often hypertrophic scar. Due to these problems non-operative treatment of uncomplicated mid clavicular fractures is still favored by most surgeons.

In contrast, ESIN as a potential alternative overcomes several disadvantages of plate fixation. The incision is kept short, providing a better cosmetic result. Restoration of clavicular length can reliably be maintained with minimal exposure and a limited amount of hardware. In about half of the interventions closed reduction of the fracture is successful, which provides the best conditions for undisturbed fracture healing.

Even when open reduction cannot be avoided, exposure can be kept to a minimum in order to avoid additional tissue damage. Most patients can be treated as day cases and full mobility of the shoulder is achieved early on. As postoperative instructions for the patients include no restrictions regarding range of motion the level of activity is determined only by pain and the patient's motivation for an early resumption of full shoulder function. Despite this rather aggressive postoperative regimen we observed neither implant failure nor migration. All fractures healed correctly resulting in a symmetrical shoulder girdle.

Resumption of normal daily activities with full function was achieved by all patients within 4 weeks postoperatively.

Intramedullary fixation of clavicular shaft fractures is not a new idea; it dates back to Lambotte at the beginning of the last century. Murray⁽¹⁶⁾ published his technique of intramedullary Kirschner wire fixation in 1940. Since then, numerous technical variations have been published.^(17,18,19,20)

ORIGINAL ARTICLE

Implant migration with fatal complications, implant failure and mal- and non-unions have been described in the literature.^(5,21) Due to the complication rate which exceeds the problems of non-operative management, all these techniques have never found general acceptance.

In contrast to Kirschner wire fixation, ESIN is a truly intramedullary stabilization technique.

The flexible Ti nail is firmly anchored in the S-shaped clavicle according to the principles described by Ligier et al.⁽²²⁾ The largest series of Elastic Intramedullary Nailing for mid clavicular fractures so far was published by Jubel et al⁽²³⁾ in 2002. In their case series 65 mid clavicular fractures were stabilized applying the Elastic Intramedullary Nailing technique.

Patient age ranged from 13 to 74 years. Unlike our study, they also included patients with neurovascular involvement, multiple injuries and floating shoulders. No major complications were observed. Only one non-union in a polytrauma patient and one secondary shortening of 1.5 cm in a multi-fragment fracture were seen.

Intramedullary advancement of the blunt Ti nail makes an injury to the neurovascular structures very unlikely. No such complication has been described in the literature using this technique. Other fatal complications like implant migration into the chest cavity have not been observed either. Migration in a lateral direction would cause damage to the acromio clavicular joint whereas migration medially would simply lead to skin perforation.

Despite our enthusiasm for Elastic Intramedullary Nailing in midclavicular fractures, we remain restrictive regarding its indications. In our opinion non-operative management is still the gold standard which provides good results in most cases, leaving Elastic Intramedullary Nailing as a valuable technique for selected cases. From a technical point of view simple fractures with a lack of bony contact or with considerable shortening are ideal indications.

For fractures with one intermediary fragment, meticulous analysis of the fracture is crucial. Elastic Intramedullary Nailing can be safely performed if the two main fragments have osseous contact after reduction, ensuring correct clavicular length with the Ti nail in place.

If the intermediary fragment involves the entire clavicular circumference it is mandatory to string this fragment as well in order to prevent secondary shortening and implant perforation through the skin. Elastic Intramedullary Nailing can certainly not be recommended for comminuted fractures as the above principles do not apply in these fracture patterns.

Further studies are necessary comparing Elastic Stable Intramedullary Nailing with non-operative treatment. The cost needs to be justified against the potential patient risk and statistically significant improvements need to be demonstrated for different patient groups.

However, in selected cases Elastic Stable Intramedullary Nailing is a safe and effective method for midclavicular fractures with a low complication rate once potential technical pitfalls are appreciated. Restoration of clavicular length is reliable. Cosmetic and functional results are excellent and a quick recovery makes early resumption of activities possible.

REFERENCES:

1. Klonz A, Hoeckertz T, Reilmann H. Klavikulafrakturen. *Unfallchirurg* 2001; 104: 70-81.
2. Robinson CM. Fractures of the clavicle in the adult. *J Bone Joint Surg* 1998; 80-B: 476-484.
3. Schwarz N, Leixnering M. Failures of clavicular intramedullary wire fixation and their causes. *Aktuelle Traumatol* 1984; 14: 159-163.

ORIGINAL ARTICLE

4. Hill JM, McGuire MH, Crosby LA. Closed treatment of displaced middle-third fractures of the clavicle gives poor results. *J Bone Joint Surg* 1997; 79-B: 537-539.
5. Matis N, Kwasny O, Gaebler C. Effects of clavicular shortening after clavicular fracture. *Hefte Unfallchirurg* 1999; 275: 314-315.
6. Constant CR. A clinical method of functional assessment of the shoulder. *Clin Orthop* 1987; 214: 160-164.
7. Eskola A, Vainionpää S, Myllynen P et al. Outcome of clavicular fracture in 89 patients. *Arch Orthop Trauma Surg* 1986; 105: 337-338.
8. Jupiter JB, Leffert RD. Non-union of the clavicle. *J Bone Joint Surg* 1987; 69-A: 753-760.
9. Schwarz N, Sim E, Pienaar S. The treatment of shaft fractures of the clavicle. *Eur J Trauma* 2001; 27: 211-217.
10. Wilkins RM, Johnston RM. Ununited fractures of the clavicle. *J Bone Joint Surg* 1983; 65-A: 773-778.
11. Nordqvist A, Redlund-Johnell I, von Scheele A, Petersson CJ. Shortening of clavicle after fracture. Incidence and clinical significance, a 5-year follow-up of 85 patients. *Acta Orthop Scand* 1997; 68: 349-351.
12. Matis N, Kwasny O, Gaebler C. Effects of clavicular shortening after clavicular fracture. *Hefte Unfallchirurg* 1999; 275: 314-315.
13. McKee MD, Wild LM, Schemitsch EH. Mid shaft malunions of the clavicle. *J Bone Joint Surg* 2003; 85-A: 790-797.
14. Rowe CR. An atlas of anatomy and treatment of midclavicular fractures. *Clin Orthop* 1968; 58: 29-42.
15. Lengua F, Nuss JM, Lechner R et al. Treatment of fractures of the clavicle by closed pinning inside-out without back and forth. *Rev Chir Orthop* 1987; 73: 377-380.
16. Bostman O, Manninen M, Pihlajamaki H. Complications of plate fixation in fresh displaced midclavicular fractures. *J Trauma* 1997; 43: 778-783.
17. Murray G. A method of fixation for fracture of the clavicle. *J Bone Joint Surg* 1940; 22: 616-620.
18. Leppilähti J, Jalovaara P. Migration of Kirschner wires following fixation of the clavicle: A report of 2 cases. *Acta Orthop Scand* 1999; 70: 517-519.
19. Ngarmukos C, Parkpian V, Patradul A. Fixation of fractures of the midshaft of the clavicle with Kirschner wires. Results in 108 patients. *J Bone Joint Surg* 1998; 80-B: 106-108.
20. Schwarz N, Leixnering M. Technique and results of clavicular medullary wiring. *Zentralbl Chir* 1986; 111: 640-647.
21. Glauser F, Kremens V. Unusual sequela following pinning of medial clavicle fracture. *Am J Roentgenol Radium Ther Nucl Med* 1956; 76: 1066-1069.
22. Ligier JN, Metaizeau JP, Prevot J. Closed flexible intramedullary nailing in paediatric traumatology. *Chir Pédiatr* 1983; 24: 283-285.
23. Jubel A, Andermahr J, Schiffer G, Rehm KE. The technique of elastic-stable intramedullary nailing of midclavicular fractures. *Unfallchirurg* 2002; 105: 511-516.

ORIGINAL ARTICLE

Fig. 1: Incision is taken 1cm lateral to the sternoclavicular joint centered above the medial end of the clavicle

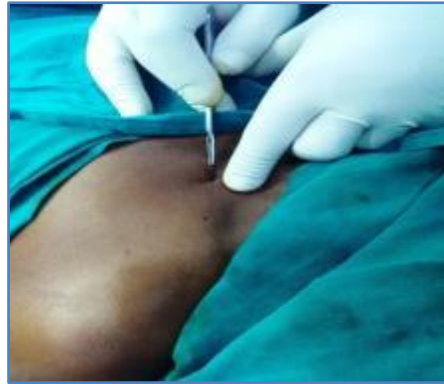

FIG. 1

Fig. 2: The medullary cavity of the clavicle was opened using a k-wire about 1cm lateral to the sternoclavicular joint. The k-wire was pointed laterally in-line with the clavicle and angled at about 30 degrees to the coronal plane.

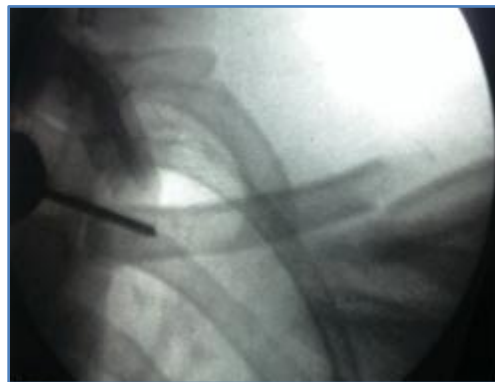

FIG. 2

Fig. 3: Once the medullary cavity was opened, a 3mm awl was used to widen the entry point.

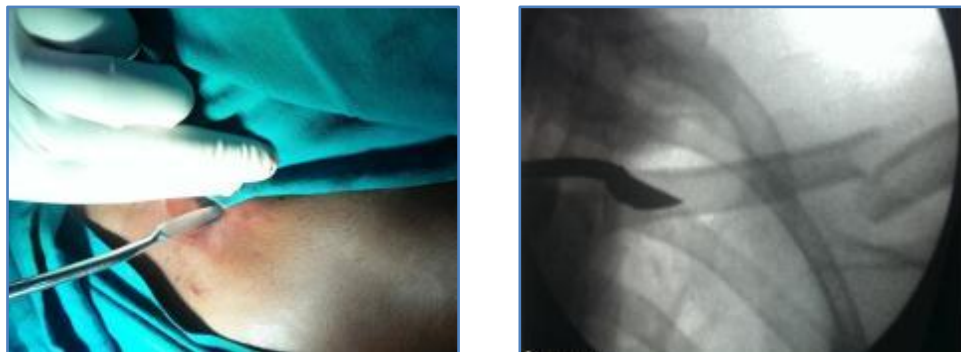


FIG. 3

ORIGINAL ARTICLE

Fig. 4: The nail was fixed in a universal chuck with a T handle and advanced with oscillating movements.

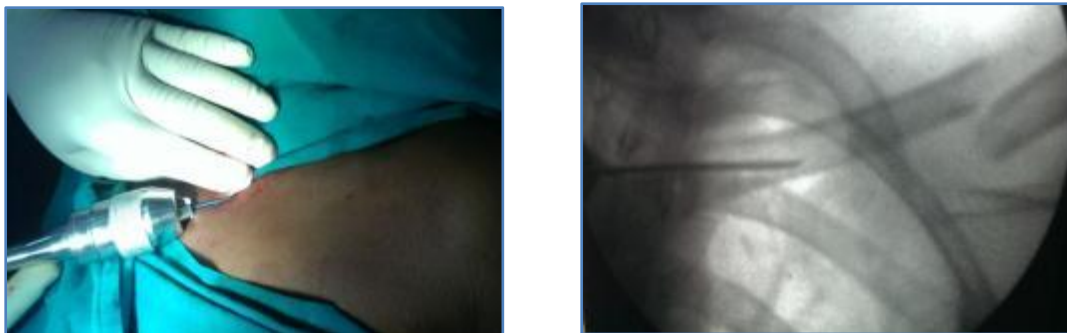

FIG. 4

Fig. 5: Once the nail reaches the fracture site the lateral end of the clavicle is held in position with a reduction forceps.

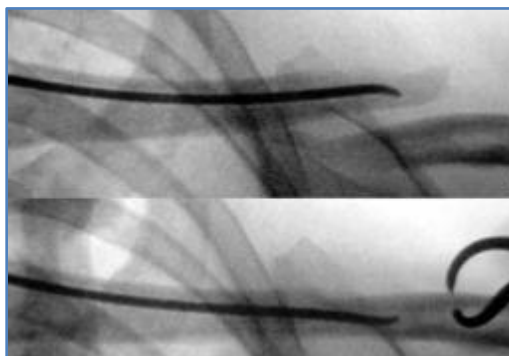


FIG. 5

Fig. 6: Postoperatively, painless shoulder range of movements were possible.

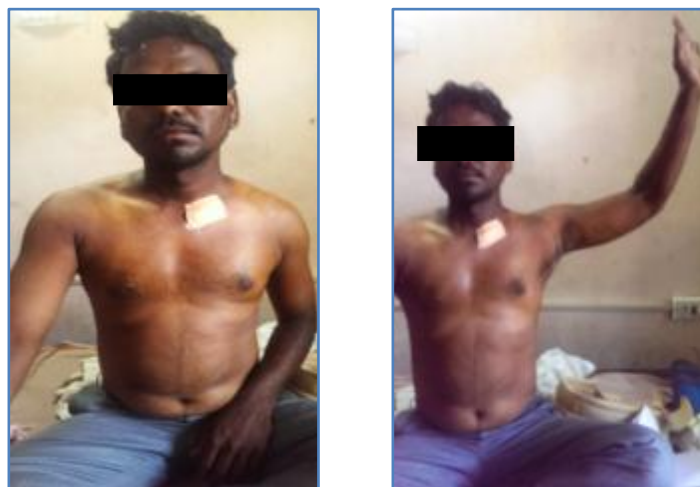

FIG. 6

AUTHORS:

1. S. B. Kamareddy
2. Anand Garampalli
3. Sanjeevi Bharadwaj

PARTICULARS OF CONTRIBUTORS:

1. Associate Professor, Department of Orthopaedics, Mahadevappa Rampure Medical College, Gulbarga, Karnataka and Senior Consultant & Director – Kamareddy Ortho and Trauma Care Hospital
2. Consultant Orthopaedic Surgeon, Department of Orthopaedics & Trauma, Kamareddy Ortho & Trauma Care Hospital, Gulbarga, Karnataka.
3. Post Graduate Resident, Department of Orthopaedics, Mahadevappa Rampure Medical College, Gulbarga, Karnataka.

NAME ADDRESS EMAIL ID OF THE CORRESPONDING AUTHOR:

Dr. Sanjeevi Bharadwaj,
#28/1, Eswari Flats,
2nd Street, Parameswari Nagar,
Adyar, Chennai-600020,
Tamilnadu.
Email: drsanjeevibharadwaj@gmail.com

Date of Submission: 22/08/2014.
Date of Peer Review: 23/08/2014.
Date of Acceptance: 30/08/2014.
Date of Publishing: 08/09/2014.