

STUDY OF LUMBRICALS IN HANDManjunath C. S¹, Naveen Kumar B. D², Sunitha R³**HOW TO CITE THIS ARTICLE:**

Manjunath C. S, Naveen Kumar B. D, Sunitha R. "Study of Lumbricals in Hand". Journal of Evolution of Medical and Dental Sciences 2014; Vol. 3, Issue 08, February 24; Page: 2047-2056, DOI: 10.14260/jemds/2014/2101

ABSTRACT: BACKGROUND AND AIM OF THE STUDY: Lumbricals are four small fasciculi which arise from the tendons of flexor digitorum profundus. First and second lumbricals arise from the radial side and palmar surface of the tendons of index and middle fingers. Third lumbrical arises from adjacent sides of the tendons of middle and ring fingers. Fourth arises from adjacent sides of tendons of ring and little fingers. Each lumbrical passes to the radial side of the corresponding finger and is attached to lateral margin of dorsal digital expansion. First and second lumbricals are supplied by median nerve (C8, T1) third and fourth lumbricals by deep branch of ulnar nerve (C8, T1). The purpose of our study is to review attachment and nerve supply of lumbricals and evaluate the variation of the above mentioned objects. **MATERIALS AND METHODS:** The study was done at from Department of Anatomy, J.J.M. Medical College, Davangere, and S. S. Institute of Medical Sciences and Research Centre, Davangere. 40 embalmed human cadaveric hands are used for the study. Dissection of lumbricals and their nerve supply is carried out and the attachments and nerve supply noted. Photograph of each specimen was taken after the dissection with digital camera. **RESULTS:** Variation in the nerve supply and attachment of lumbricals was noted. **CONCLUSION:** These findings will be useful for surgeons who wish to specialize in hand surgery.

KEYWORDS: Lumbrical.

INTRODUCTION: The lumbrical muscle is so named because it resembles the shape, size and color of an earthworm.¹ Compared to their size, they play very significant role in dynamics of the intricate movements of the fingers required for the precise work.²

The proximal attachment of lumbricals especially first and second may predispose to the development of carpal tunnel syndrome, in those individuals whose occupation requires repetitive finger movement.²

The tiny lumbricals provide muscular bridges and harmonise the functions between lateral band interphalangeal extensor mechanism and flexor digitorum profundus, a unique occurrence which may have importance in adjusting the position of finger joints when using the hands.³

With change in balance of power, the lumbrical tends to pull the profundus distally as it shortens the lateral band.³

The rapidity and delicacy of lumbrical muscle action is similar to orbicularis oculi. Because of its radioulnar position with respect to metacarpophalangeal joint axis and continuation into the lateral band, active contraction of the lumbrical muscle will flex and pronate the metacarpophalangeal joint and extend the interphalangeal joints. These movements are helpful to the violinist in fingering the strings of his instrument hence the term 'Fiddler's muscle'.³

The study of innervation of lumbrical helps to know the etiology in the paralysis of the muscle and in electrical stimulation, physiotherapy and plastic reconstruction in leprosy.

ORIGINAL ARTICLE

An aberrant lumbrical muscle with abnormal origin or insertion may be the principal cause for compadodactyly which is a painless flexion contracture of the proximal interphalangeal joint that is a gradually progressive condition.⁴

In mangled hand preserving or reconstructing flexor tendon function is to avoid lumbrical plus deformity.⁴

Because of the increased hand injuries in road traffic accidents, knowledge about the attachments and innervation is very important for the surgeons in hand surgery.

The articular system in the digit is connected by mechanical link and lumbrical muscle is one of the links in this system that produces dynamic controlled extension of interphalangeal joints.²

The present study was undertaken to observe and record the attachments and innervation of lumbricals in south Indian in properly fixed cadaveric hands. These findings will be useful for surgeons who wish to specialize in hand surgery.

MATERIALS AND METHODS: 40 embalmed human cadaveric hands, from Department of Anatomy, J.J.M. Medical College, Davangere, and S.S. Institute of Medical Sciences and Research Centre, Davangere.

Materials used:

- Dissection instruments for dissection, scale and magnifying lens.
- 10% formalin solution – used as a preservative for specimens.

METHOD: Dissection of lumbricals and their nerve supply is carried out and the attachments and nerve supply noted. Photograph of each specimen was taken after the dissection with digital camera.



Fig. 10: Specimen No. 17 & 18

ORIGINAL ARTICLE

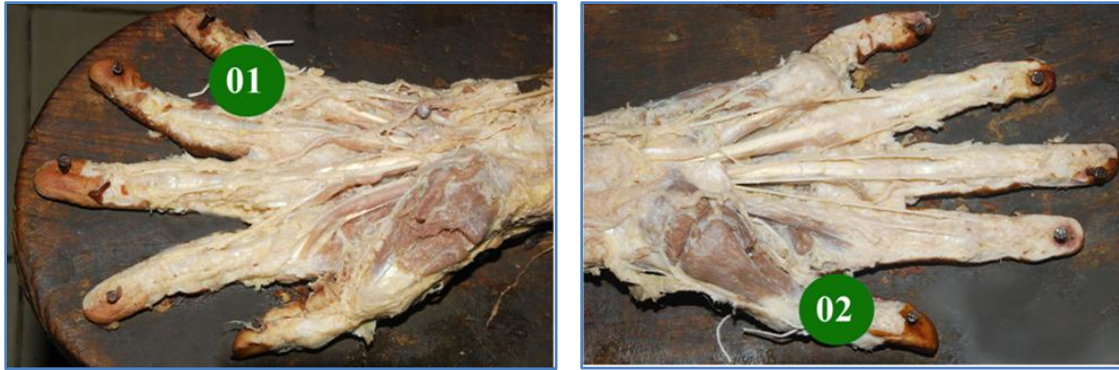

Fig. 2: Specimen No. 1 &2

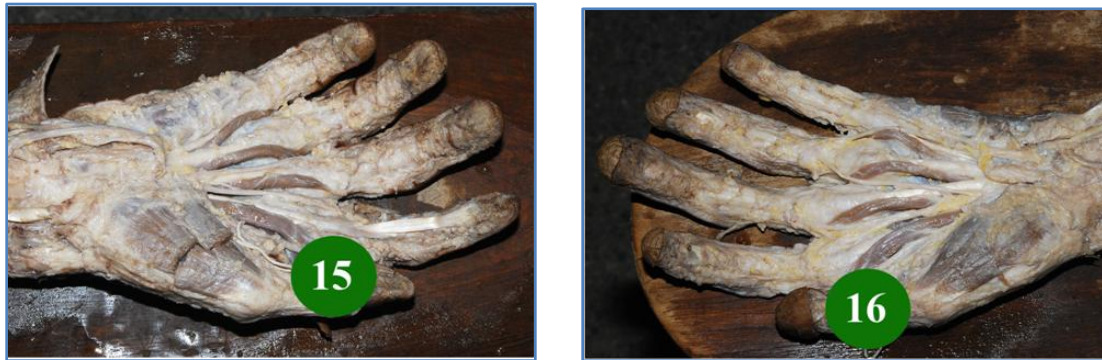

Fig. 9: Specimen No. 15&16

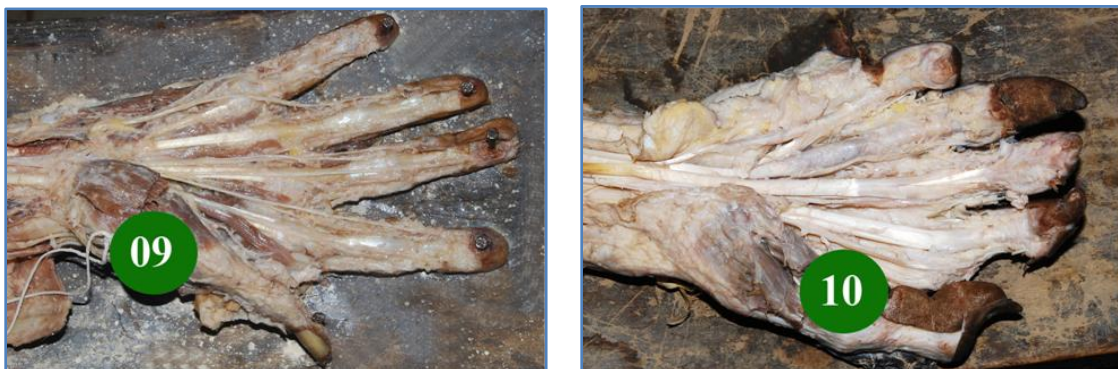

Fig.6: Specimen No. 9&10

ORIGINAL ARTICLE



Fig.19: Specimen No. 35&36

RESULTS:

Lumbrical Muscle No.	Normal type	
	No	%
1	40	100
2	40	100
3	40	100
4	40	100

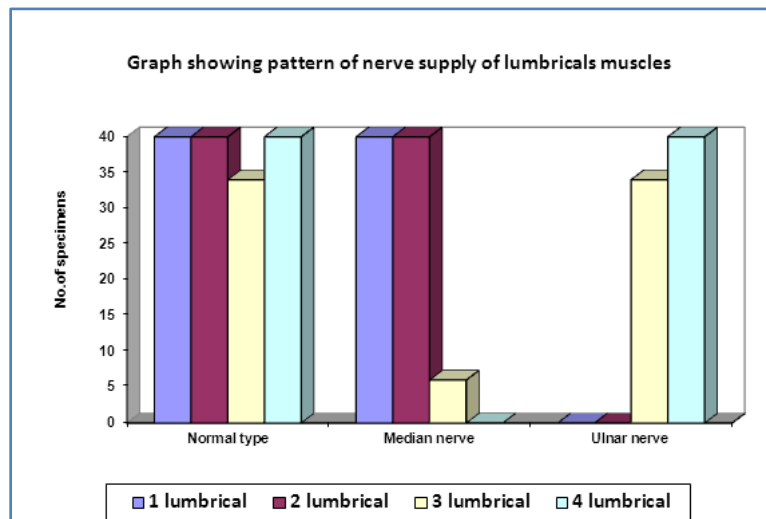
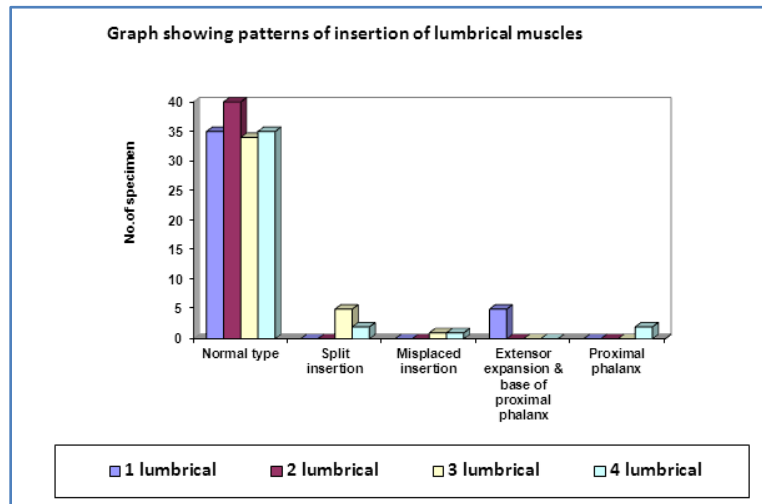
PATTERN OF ORIGIN OF LUMBRICAL MUSCLES (STUDY OF 40 HANDS)

Lumbrical muscle No.	Normal type		Split insertion		Misplaced insertion		Extensor expansion and base of proximal phalanx		Proximal phalanx	
	No	%	No	%	No	%	No	%	No	%
1	35	87.5	0	0	0	0	5	12.5	0	0
2	40	100	0	0	0	0	0	0	0	0
3	34	85	5	12.5	1	2.5	0	0	0	0
4	35	87.5	2	5	1	2.5	0	0	2	5

PATTERN OF INSERTION OF LUMBRICAL MUSCLES (STUDY OF 40 HANDS)

Lumbrical muscle No.	Normal type		Median nerve		Ulnar nerve	
	No	%	No	%	No	%
1	40	100	40	100	0	0
2	40	100	40	100	0	0
3	34	85	6	15	34	85
4	40	100	0	0	40	100

PATTERN OF NERVE SUPPLY OF LUMBRICAL MUSCLES (STUDY OF 40 HANDS)



DISCUSSION: Forty specimens were selected to study the lumbrical muscles in hand of its origin, insertion and innervation.

FIRST LUMBRICAL: In the present study, first lumbrical takes origin from the radial side and palmar surface of the tendon flexor digitorum profundus to the index finger in all specimens. Russel T, Wood Burne A.M. mention that the lateral two muscle arises just beyond the flexor retinacular from radial side and palmar surface of flexor digitorum tendon of second digit.⁵ Bruce Batter has reported an aberrant first lumbrical arising from the lateral surface of flexor digitorum superficialis at about the junction of middle and distal one third of forearm, partially or completely responsible for carpal tunnel syndrome.⁶ Bergman R.A. has mentioned 20% variations in the lumbrical muscles. A case has been observed in which fasciculus arising from the muscular belly of the superficial or deep flexor joined the first lumbrical.⁷

Goto S. has reported anomalous lumbrical muscle originating from the forearm and inserted in the region of the index finger compressing the median nerve.⁸ In the present study the first

ORIGINAL ARTICLE

lumbrical was unicipital in all the specimens. Gurmit Singh observed rare case of bipennate first lumbrical muscle with the additional origin from the flexor digitorum superficialis in the hand distal to flexor retinaculum.⁹

Mark E. has reported that first lumbrical of anomalous origin compress the radial branch of the median nerve.¹⁰ Joshi SD. et. al, have mentioned that proximal attachment of first lumbrical extended into the carpal tunnel in 20% of cases studied.²

Bhagath Kumar Potu have mentioned origin of first lumbrical from the tendon of flexor digitorum profundus with its proximal extension upto proximal border of flexor retinaculum which may compress the median nerve.¹¹

In the present study, first lumbrical muscle is inserted into dorsal digital expansion in 35 specimens. In 5 specimens (10%) they are inserted into base of first phalanx and extensor expansion. Bary J. Anson has mentioned the tendon is inserted into the ulnar side of the base of the digit to which tendon is attached or the tendon may divide and go to adjacent sides of fingers.¹²

In the present study first lumbrical was supplied by the common palmar digital branch of median nerve in all the 40 specimens.

W. Henry Hollinshead says that nerve of first lumbrical enters the muscle anteriorly from digital branch of median nerve.¹³

In the present study, total length of first lumbrical is maximum 8.5cm and minimum 5.0 cm. The belly circumference is maximum 1 cm and minimum 0.3 cm.

Siegel DB states that patients whose job required repetitive hand motion had large lumbricals found in hands of fresh cadavers.

SECOND LUMBRICAL: In the present study, second lumbrical takes origin from the radial side and palmar surface of the tendon of flexor digitorum profundus of the middle finger in all the 40 specimens.

Russel T, has mentioned that second lumbrical arises just beyond the flexor retinaculum from radial side and palmar surface of flexor digitorum tendon of third digit.⁵ Bergman R.A. has mentioned that second lumbrical arises from the two tendon between which it lies.⁷ Joshi SD has mentioned that second lumbrical extended into the carpal tunnel in 20% of cases studied.²

In the present study, second lumbrical is unipennate in all the 40 specimens.

In the present study, the second lumbrical is inserted into radial side of middle finger and attached to lateral margin of dorsal digital expansion in all the 40 specimens.

Ernest Gardner observed variations in insertion are common. The lumbrical are inserted into lateral side of extensor expansion of third finger just distal to interossi.¹⁵ Russel T. mentioned that it is inserted by fanning out at the level of proximal phalanx into the radial border of the expansion of tendon of extensor digitorum muscle.⁰⁵

In the present study, the second lumbricals are supplied by common palmar digital branch of median nerve in all the 40 specimens.

W.J. Hamiton has mentioned that second lumbrical is also supplied by ulnar nerve.¹⁶ W. Henry Hollinshead says that second lumbrical receives the nerve anteriorly from digital branch of median nerve.¹³

In the present study, maximum length of the second lumbrical is 8.5 cm and minimum length 5.5 cm. The belly circumference is maximum 1cm and minimum 0.3 cm.

ORIGINAL ARTICLE

Chaundrue et al have found compression of radial and ulnar collateral arterial system by hypertrophy of lumbrical muscle producing whitefinger.¹⁷

THIRD LUMBRICAL: In the present study third lumbrical takes origin from adjacent sides of the tendon of flexor digitorum profundus to the middle and ring fingers in all the 40 specimens.

Bary J. Anson has mentioned third lumbrical may be doubled or missing. It may arise from tendon of flexor digitorum superficialis and from belly of deep flexors.¹² Bergman RA has mentioned third lumbrical arises from one tendon only; the origin may be displaced proximally arising from flexor retinaculum.⁷ Koizumi et al have observed anomalous lumbrical muscle origin in forearm, considered as accessory lumbrical. The position of muscle belly shifted distally present important clue to phylogenic origin of flexor digitorum superficialis.¹⁸

In the present study, third lumbrical are all of bipennate type of muscle in all the 40 specimens.

In the present study, the third lumbrical is inserted to lateral margin of dorsal digital expansion of ring finger in 34 specimens (85%). 5 specimens (12.5%) show split insertion, and 1 specimen (2.5%) shows misplaced insertion.

K.F. Russel has observed that third lumbrical is inserted to tendon of third dorsal interosseus.¹⁹ Bergman RA has mentioned third lumbrical may be bifid distally going to two fingers in 40% of individuals.⁷

In the present study, third lumbrical is supplied by deep branch of ulnar nerve in 34 specimens (85%), 6 specimens (15%) are supplied by median nerve.

H. St. John Brooks has mentioned variation in nerve supply to third lumbrical whole or part by median nerve in 12 out of 21 hands.¹⁹ J.T. Wilson observed that third lumbrical was innervated from median as well as deep division of ulnar nerve.²⁰ Lowell AA observed arborization of the deep branch of ulnar nerve to third lumbrical within middle third.²¹ David D. have mentioned that third lumbrical has dual innervation in 50% of upper extremity. In such cases claw hand deformity affect only little finger.⁴ Ernest Gardner observed third lumbrical commonly receives twig from median nerve.¹⁵

In the present study, third lumbrical shows maximum length of 8 cm and minimum length of 4.5 cm and belly circumference is maximum 0.7 cm and minimum 0.2 cm.

FOURTH LUMBRICAL: In the present study, fourth lumbrical takes origin from adjacent side of the tendon of flexor digitorum profundus of ring and little fingers in all the 40 specimens.

Bergman RA has mentioned that fourth lumbrical replaces the fourth tendon of flexor superficialis.⁷ Joshi SD has mentioned fourth lumbrical is absent in 4%.²

In the present study, fourth lumbrical is bipennate muscle in all the 40 specimens.

G. Windisch observed unipennate fourth lumbrical muscle.²²

In the present study, fourth lumbrical is inserted into lateral margin of dorsal digital expansion in 35 specimens (87.5%) 2 specimens (5%) have split insertion, 1 specimen (2.5%) misplaced insertion and 2 specimens (5%) into proximal phalanx.

Bary J. Anson has mentioned tendon of insertion may go to ulnar side of base of digit to which the tendon is attached or tendon may divide and go to the adjacent sides of the fingers.¹³ Inour G and Maeda M, have reported abnormal insertion of lumbrical muscle into flexor digitorum superficialis of right little finger causing camptodactyly.²³ G. Windisch observed fourth lumbrical muscle dividing

ORIGINAL ARTICLE

into ulnar and radial slip at fifth metacarpophalangeal joint. It is inserted into flexor digitorum superficialis as well as proximal and middle phalanges.²² Thomas H. has reported trigger finger is caused by insertion of lumbrical muscle into flexor digitorum superficialis tendon of little finger.²⁴

In the present study, fourth lumbrical is supplied by deep branch of ulnar nerve in all the 40 specimens.

Russel T. mentioned that fourth lumbrical is innervated by deep branch of ulnar nerve (C8T1) that enters the middle from deep surface.⁰⁵ W. Henry Hollinshead says fourth lumbrical is supplied by deep branch of ulnar nerve.¹³ Lowell AA observed arborization of deep branch of ulnar nerve into fourth lumbrical along its distal third.²¹

In the present study, the fourth lumbrical has maximum length of 7.0 cm and minimum 3.5 cm. The maximum belly circumference is 0.5 and minimum 0.2 cm.

CONCLUSION:

Lumbrical muscle had normal origin from the tendons of flexor digitorum profundus.

The first and second lumbricals were unipennate; third and fourth were bipennate.

The first lumbrical showed variation in the insertion. 12.5% were inserted to the base of proximal phalanx and dorsal digital expansion.

The third lumbrical showed variation in the insertion. 12.5% had split insertion and 2.5%, misplaced insertion.

The fourth lumbrical showed variation in the insertion. 5% had split insertion, 2.5% misplaced insertion, 5% to first phalanx.

The third lumbrical was innervated by median nerve in 15%.

These findings will be useful for surgeons who wish to specialize in hand surgery.

REFERENCES:

1. John. V. Basmajiah. M. D Grant's method of anatomy. 8th Ed. Baltimore USA: Williams and Wilkins; 1971. p143.
2. Joshi SD, Joshi SS, Athavala SA. Lumbrical muscle and carpal tunnel. J Anat Soc India 2005; 54(1):12-15.
3. John Marquis. Reconstructive Plastic surgery. Vol.6, USA: W.B. Saunders Company, 1977: p2962, 3128.
4. David P. Green, Robert N. Hotchkiss, William C. Pederson, Scott W. Wolfe. Green's operative hand surgery. 5th Ed., Vol.2, Elsevier Churchill Livingstone; 2005. p.1541,1597, 1165, 1948
5. Russel T, Woodburne A.M. Essential of human anatomy. 3rd Ed., U.S.A.: Oxford University. 1965:p135-36.
6. Bruce Butter, Jr. Alexandria and Elmer C. Bigley, Arlington, Virginia. Aberrant index (first) lumbrical tendinous origin associated with carpal tunnel syndrome. J Bones & Joint Surg 1971 Jan;53-A(1):
7. Bergmann RA, Affi AK, Miyacchi R. Compendium of human anatomic variation Baltimore: Urban and Schwarzenberg; 1988. p.17.
8. Goto S, Kojima T. An anomalous lumbrical muscle with an independent muscle belly associated with carpal tunnel syndrome. Department of Plastic/Reconstructive Surgery Jikei

ORIGINAL ARTICLE

- University School of Medicine, Tokyo Japan. *Hand chri Mikrochir Plast Chir* 1993 Mar; 25(2): 72-4.
9. Gurmit Singh, Boon-Huat Bay, George WC, Yip and Samuel Tay. Lumbrical muscle with additional origin in the forearm. *Aust & Newzel J Surg* 2001 May; 71(5). p301.
 10. Mark E. Pruzansy. Compression of radial branch of median nerve due to anomalous muscle belly of first lumbrical in child. *The Mount Signal Journal of Medicine* 2004 Sep; Vol.71 (4): p285.
 11. Bhagath Kumar Potu. Anomalous origin of the first lumbrical in the hand and its possible role in carpal tunnel syndrome. *Internet J of Neurol* 2007;8(1):
 12. Barry J. Anson Morris human anatomy. 12th Ed., U.S.A.: McGraw Hill; 1966 p 517.
 13. Henry W., Hollinshead, Cornelius Rose. Text book of anatomy. 4th Ed., Philadelphia: Harper and Row Publishers; 1985. p.261.
 14. Siegel DB, Kuzma G, Eakins D. Tucson Orthopaedic institute A2 85712 USA. Anatomic investigation of the role lumbrical muscle in carpal tunnel syndrome. *J Hand Surg (Am)* 1995 Sep; 20(5): 860-3.
 15. Ernest Gardner, Donald J Gray, Ronan D. Rahilly. Anatomy a regional study of human structure. 2nd Ed., W.B. Saunders Company; 1963. p.188.
 16. Boyd JD, et al. Text book of human anatomy. By W.J. hamilton. 2nd Ed., Great Britain: 1976. p.175.
 17. Chaudruc JM, Fiorenza F, Riviere C, Arnaud JP. White finger and hypertrophy of the lumbrical muscle. *Chri Main* 2000 Sep; 19(4): 232-4.
 18. Koizumi M, Kawai K, Honma S, Kodama K. Anomalous lumbrical muscle arising from the deep surface of flexor digitorum superficialis muscle. Department of Anatomy, Honjo, Japan, *Anna Anat* 2002 Jul; 184(4): 387-92.
 19. H.ST. John Brooks. Variation in nerve supply of lumbrical muscles in the hand and foot, with some observation on the innervation of the perforating flexors. *J AnatoPhysiol* 1887 July; 21(Pt 4): 575-585.
 20. Wilson JT. Two cases of variation in the nerve supply of first lumbrical muscle in hand. *J AnatPhysiol* Oct 1889; 24 Pt (1):22-6.
 21. Lowell A.A, Hughes, Howard M.A, Clarke. Normal arborization of deep branch of the ulnar nerve into the interossi and lumbricals. University of Toronto, Ontario, Canada. *J Plast Surg* 1995 Jan; 20(1):10-4.
 22. Windisch G. Institute fur anatomie, Karl Franzens – Universitat Graz, Harrachgasse 21, A 8010 Graz, Austria. 22nd May 2000.
 23. Inoue G, Tamuea Y. Camptodactyly resulting from paradoxical action of an anomalous lumbrical muscle. *Scanda J Plastic ReocnstrSurg Hand* 1994 Dec; 28(4): 309-11.
 24. Thomas H. Bartell, Sameer I. Shehadi. Trigger finger secondary to anomalous lumbrical insertion – a case report and review of literature. *Plast Recon Surg* 1991 Feb; 87(2): 354-7.

AUTHORS:

1. Manjunath C. S.
2. Naveen Kumar B. D.
3. Sunitha R.

PARTICULARS OF CONTRIBUTORS:

1. Assistant Professor, Department of Anatomy, Hassan Institute of Medical Science, Hassan.
2. Tutor, Department of Anatomy, Hassan Institute of Medical Science, Hassan.
3. Post Graduate, Department of Anatomy, Hassan Institute of Medical Science, Hassan.

NAME ADDRESS EMAIL ID OF THE CORRESPONDING AUTHOR:

Dr. Manjunath C. S,
Assistant Professor,
Department of Anatomy,
Hassan Institute of Medical Science,
Hassan - 573201, Karnataka.
E-mail: csmanjunath41@gmail.com

Date of Submission: 13/02/2014.

Date of Peer Review: 14/02/2014.

Date of Acceptance: 19/02/2014.

Date of Publishing: 24/02/2014.