

CASE REPORT

A RARE CASE OF ENDOBRONCHIAL NEUROFIBROMA.

P. B. Nichkaode, Rohan Umalkar, Nilesh Tulaskar, Kapil Panchbhai, Rahul Zamad

1. Associate Professor, Department of General surgery, NKP Salve institute of medical sciences, Nagpur
2. Junior Resident, Department of General surgery, NKP Salve institute of medical sciences, Nagpur.
3. lecturer, Department of General surgery, NKP Salve institute of medical sciences, Nagpur.
4. lecturer, Department of General surgery, NKP Salve institute of medical sciences, Nagpur.
5. Junior Resident, Department of General surgery, NKP Salve institute of medical sciences, Nagpur.

CORRESPONDING AUTHOR:

Dr Rohan umalkar
Dept of Surgery,
Lata mangeshkar hospital, Digdoh hill,
Nagpur -440019.
E-mail: dr_umalkar@yahoo.co.in

ABSTRACT: Among benign tracheobronchial neoplasms, neurofibromas of neurogenic origin are exceedingly rare. In a search of world literature, only few cases of endo tracheobronchial neurofibromas were reported. We report another case of a 17 yrs female who presented to our hospital with the symptoms of recurrent fever, intermittent non productive cough and short of breath on exertion. Chest X ray shows total opacity on right side, tracheal shift on right and well compensated Left lung . Bronchoscopy revealed a round tumor obstructing the lumen of the right main bronchus. Computed tomography demonstrated a homogenous tumor located within the right main bronchus with obstructive pneumonitis of the right lung. Right posterolateral thoracotomy done. Bronchotomy done for excision of endobronchial tumour followed by end to end bronchoplasty with live pericardial flap. Endobronchial neurofibroma was confirmed by pathologic examination and immunohistochemical examination.

KEYWORDS: Endobronchial neurofibroma; Thoracotomy; Lung; Neurofibromatosis; Bronchus.

INTRODUCTION: Neurofibroma belongs to the benign tumors and it is categorised as neuroectodermal tumor. Neurofibromas are most frequently found in the posterior mediastinum, their endobronchial localisation is rather rare. Tumors arising from tracheobronchial trees are not common. Most of these tumors are malignant in origin, such as squamous cell carcinoma, adenoid cystic carcinoma, or malignant tumors of thyroid or lung with secondary tracheal or bronchial involvement [1]. Benign tumors of tracheobronchial trees include papilloma, leiomyoma, hemangiomas, and tumors of neurogenic origin [2]. Benign neurogenic tumors originate from the peripheral nervous system, are composed of Schwann cells, and appear as neurilemmomas or neurofibromas. Neurilemmomas (Schwannomas) are single, encapsulated lesions attached to a nerve but containing no neurites. Neurofibromas are usually multiple, not encapsulated, occur within the nerve sheath, and contain neurites. These two tumors can be found in the mediastinum, lung parenchyma, or within the tracheobronchial trees [3-5]. The incidence of neurofibromas involving the trachea or bronchus is lower than that of neurilemmomas. In a search of the world literature, there were only 23 cases of tracheobronchial neurofibromas reported.

CASE REPORT

CASE REPORT: A 17 yrs female presented with complaints of recurrent history of fever with chills, non productive cough, short of breath on exertion, no hemoptysis. No other comorbid conditions and familial disease. General examination was normal. No evidence of neurofibromatosis. On respiratory examination, no breath sounds on right side of chest. Blood examinations were normal. Pulmonary Function tests also well compensated, Mild restrictive. FEV1- 1.89 lt. Chest X ray shows total opacity on right side, tracheal shift on right and well compensated Left lung (Fig 1). Bronchoscopy revealed a round tumor growth with a wide base arising from the posterior wall of the right main bronchus, about 5 mm distal to the carina, obstructing nearly the whole lumen of the right main bronchus (Fig 2). Bronchoscopic brush cytology s/o Bronchial adenoma. Computed tomography demonstrated a homogenous tumor located within the right main bronchus with obstructive pneumonitis of the right lung (Fig 3). The patient underwent right-sided posterolateral thoracotomy. A firm yellowish-brown, well-defined tumor was found at the posteromedial wall of the right main bronchus. The lumen of the right main bronchus was nearly occluded. There was no invasion to adjacent structure. We exposed the right main bronchus and bronchotomy done for excision of endobronchial tumour (Fig 4). Endotracheal Tube of 4 Fr. passed in to distal Right Bronchus and Jet Ventilation given to see the Inflation of Lung. End to end bronchoplasty done followed by reinforcement of bronchoplasty with live pericardial flap (Fig 5). Histopathologically, the tumor consisted of interlacing, waving, spindle-shaped cells strongly positive for S-100 protein and negative for desmin, and actin immunohistochemically, which confirmed the diagnosis of Benign Endobronchial neurofibroma. Fully expansion of lung seen in 3 weeks on chest X-ray. (Fig 6).

DISCUSSION: Benign tumors originating from the tracheobronchial trees are not common. Papilloma, polyps, fibroma, and hamartoma account for most of the benign tumors arising in the tracheobronchial trees, followed by leiomyoma and neurogenic tumors [2]. Neurogenic tumors include neurilemoma (Schwannoma), neurofibroma, and neuroma, which can also be seen in the mediastinum or lung parenchyma. Some can cause external compression of the superior vena cava or bronchus [4]. They rarely occur within the endo tracheobronchial trees as primary tumors [5]. Neurilemmomas are rarely associated with von Recklinghausen's neurofibromatosis, rarely undergo malignant change, and often contain degenerative changes. Neurofibromas are frequently associated with von Recklinghausen's neurofibromatosis, and 12% undergo malignant change. In our review of the literature, we found 14 male and 6 female patients with tracheobronchial neurofibroma, including our presenting case (Table 1). The ages ranged from 8 to 64 years (mean 33.9). Perelman and coworkers reported 2 tracheal neurofibroma cases in their series including 144 tracheal tumors [6]. No clinical detail of these 2 patients was mentioned in the article. The trachea was the most frequent site involved in the cases of endo tracheobronchial neurofibromas. There were 2 cases found to have two lesions during clinical manifestations. One patient had neurofibromas in the right intermedius bronchus and the right main bronchus when presented, while the other patient had the neurofibromas in the right lower lobe bronchus and the larynx removed in different periods of time. It is surprising that no lesion from left-sided bronchial trees was reported. Four out of 18 patients had von Recklinghausen's neurofibromatosis. The ages of these 4 patients were from 18 to 45 years, average 29 years. Three of 4 patients were male (75%). The clinical symptoms and signs of patients with tracheobronchial neurofibromas were mostly related to airway obstruction resembling patients with tracheal tumors. The initial symptoms presented clinically included cough, wheezing, and

CASE REPORT

dyspnea, which are related to airway obstruction. Repeated respiratory tract infection, hemoptysis, and chest pain are occasionally seen. The procedures for tumor removal consisted of operation, laser vaporization, and bronchoscopic removal. The size of the tumor was recorded in only 5 surgical cases and varied from 1.8 to 6 cm in diameter. There has been no recurrence reported to date. Patients with tracheobronchial tumors may be asymptomatic for years. Chest roentgenography may reveal filtration and atelectasis, though the majority of the patients have normal chest films in the initial presentation. Delayed diagnosis is not unusual, as overlying soft tissue obscures the trachea in posteroanterior radiography. Some reported that final diagnosis might be realized after a 10 to 15 month delay from the onset of symptoms [7]. The other diagnostic tools include computed tomography and magnetic resonance imaging, which can demonstrate the size of the tumor and the relationship between the tumor and adjacent tissue. Bronchoscopy may disclose a round, protruded, and sometimes hypervascular tumor. Diagnosis can be obtained through biopsy, though it carries some risk of hemorrhage. The treatment for the endo tracheobronchial neurofibromas depends on the size and the location of the tumors, and should be conservative. Some small tumors can be removed endoscopically with or without laser. However, if the tumors invade adjacent tissue or result in obstructive pneumonitis, surgery should be undertaken.

CONCLUSION: Endobronchial neurofibroma is a rare clinical entity. CT is helpful to find small lesions in airway or lesions in the lung; bronchoscopy is not only used to explore the airway, but also to biopsy in order to understand the etiology. After diagnosis of the neurofibromas, the treatment depends on the size and the location of the tumors. Some small tumors can be removed endoscopically with or without laser. However, if the tumors invade adjacent tissue, surgery should be carried out.

REFERENCES:

1. Weber AL, Grillo HC. Tracheal tumors: a radiological, clinical, and pathological evaluation of 84 cases. *Radiol Clin North Am* 1978; 16:227-46.
2. Miller DR. Benign tumors of lung and tracheobronchial tree. *Ann Thorac Surg* 1969; 8:542-60.
3. Dodge TL, Mahaffey JE, Thomas JD. The anesthetic management of a patient with an obstructing intratracheal mass, a case report. *Anesth Analg* 1977; 56:295-8.
4. El Oakley R, Grotte GJ. Progressive tracheal and superior vena caval compression caused by benign neurofibromatosis. *Thorax* 1994; 49:380-1.
5. Horovitz AG, Khalil KG, Verani RR, Guthrie AM, Cowan DF. Primary intratracheal neurilemoma. *J Thorac Cardiovasc Surg* 1983; 85:313-20.
6. Perelman MI, Koroleva N, Birjukov J, Goudovsky L. Primary tracheal tumors. *Semin Thorac Cardiovasc Surg* 1996; 8:400-2.
7. Karlan MS, Livingston PA, Baker DC Jr. Diagnosis of tracheal tumors. *Ann Otol* 1973; 82:790-9.

CASE REPORT

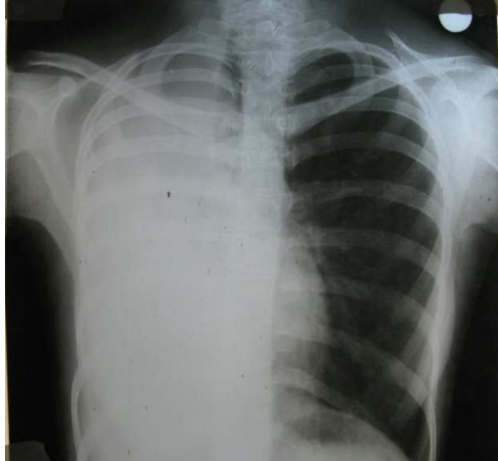

Figure 1 : Total opacity on right side, tracheal shift on right and well compensated Left lung.

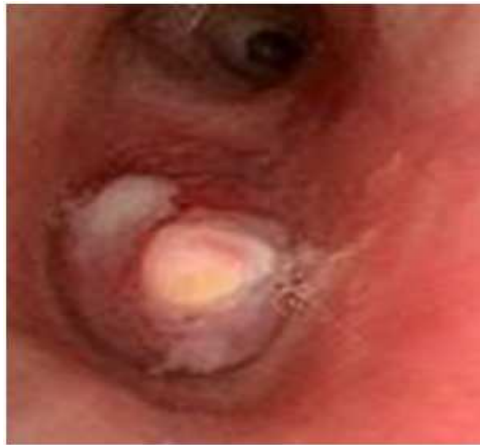

Figure 2: round tumor growth with a wide base arising from the right main bronchus obstructing nearly the whole lumen of the right main bronchus

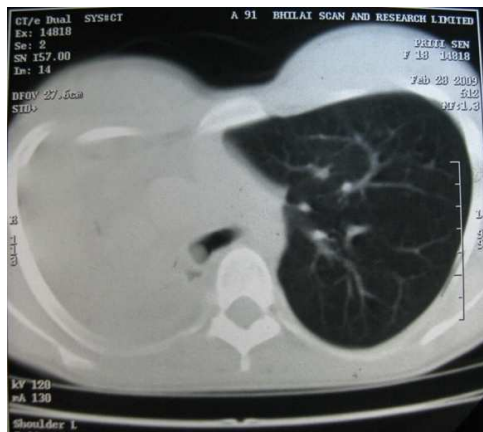


Figure 3: Tumor located within the right main bronchus with obstructive pneumonitis of the right lung

CASE REPORT

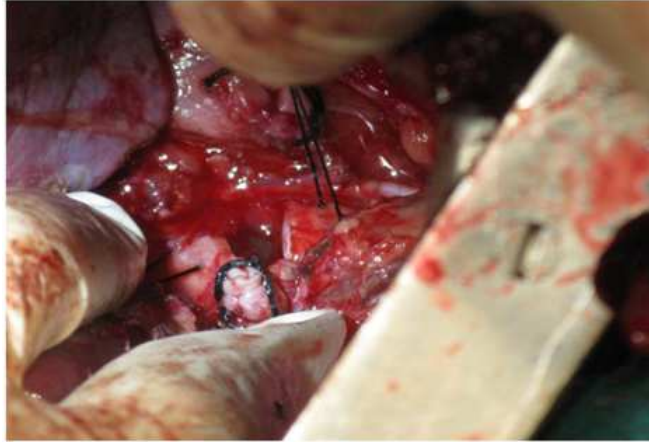


Figure 4: Bronchotomy with excision of endobronchial tumor

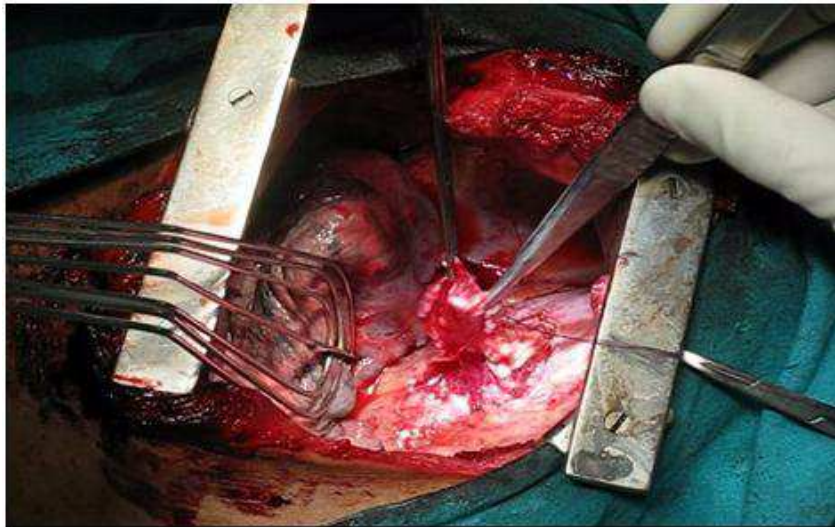


Fig 5: Live Pericardial Flap for Reinforcement of Bronchoplasty

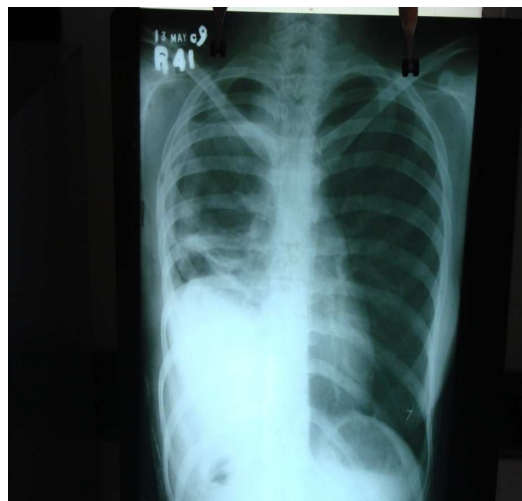
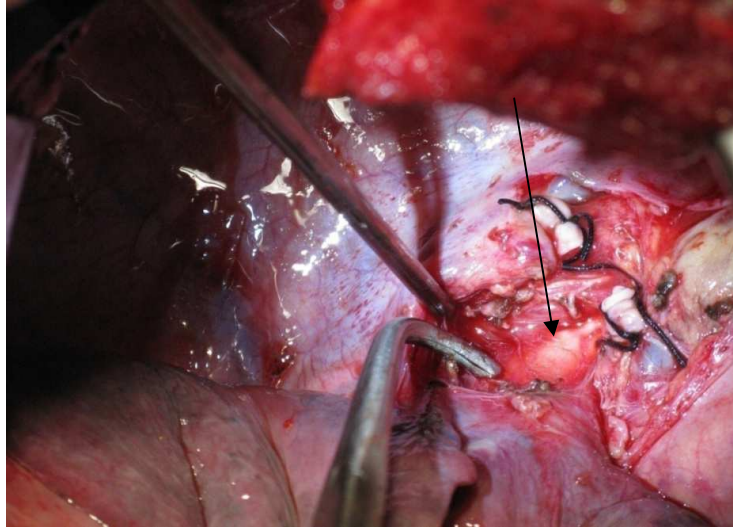


Figure 6: Fully expansion of lung

CASE REPORT



Arrow showing exposure of Rt Main Bronchus occupying tumor

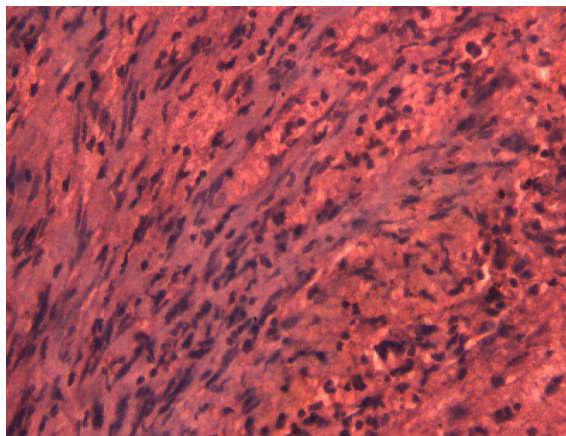
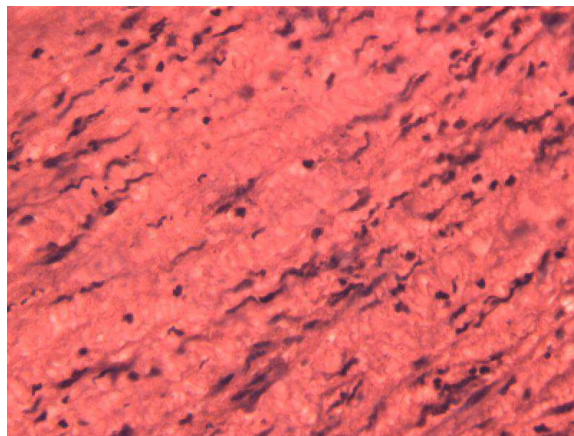


Figure 6 : showing Spindle shaped cells



s/o neurofibroma .