

## INCIDENCE OF VIRILISATION IN SEX CORD STROMAL TUMOURS OF OVARY, A 5- YEAR EXPERIENCE IN A TERTIARY CARE GYNAECOLOGICAL CENTRE

Mahendran Revathy<sup>1</sup>, Madurai Padmanabhan Kanchana<sup>2</sup>

<sup>1</sup>Assistant Professor, Department of Pathology, Institute of Obstetrics and Gynaecology, Egmore, Chennai.

<sup>2</sup>Professor, Department of Pathology, Institute of Obstetrics and Gynaecology, Egmore, Chennai.

### ABSTRACT

#### BACKGROUND

Androgen secreting ovarian tumours represents less than 5% of all ovarian neoplasms. Hyperandrogenism results in development of acne, hirsutism, androgenic alopecia, menstrual irregularities & virilisation or masculinization. The objective of this study is to look for incidence of virilisation in sex cord stromal tumours and discussion regarding various causes of hyperandrogenism.

#### MATERIALS AND METHODS

A retrospective descriptive study of virilising tumours of ovary was conducted in a tertiary care gynaecological centre at Institute of obstetrics and Gynaecology, Chennai for a period of 5 years from February 2012 to February 2017. 4 cases of sex cord stromal tumours presented with signs of virilisation.

#### RESULTS

A total of 592 ovarian malignancies were identified over a period of 5 yrs. out of which 36 cases were diagnosed as sex cord stromal tumours (6.08%). The most common age group affected are between 41 to 50 yrs. with median age of 45 yrs. Right sided ovary (58%) is more commonly involved than left sided (42%) ovary. Most of the tumours were solid in appearance with average size ranging between 6 cm – 10 cm. The most common symptom is abdominal mass (64%) with 4 cases presented with history of virilisation (11%).

#### CONCLUSION

Based on present study it may be concluded that patients with symptoms of virilisation require detailed clinical history, physical examination for signs, laboratory investigations & imaging to exclude causes other than ovarian neoplasm.

#### KEYWORDS

Hyperandrogenism, Ovarian Tumours, Virilisation, Hirsutism.

**HOW TO CITE THIS ARTICLE:** Revathy M, Kanchana MP. Incidence of virilisation in sex cord stromal tumours of ovary, a 5- year experience in a tertiary care gynaecological centre. J. Evolution Med. Dent. Sci. 2018;7(07):886-891, DOI: 10.14260/jemds/2018/202

#### BACKGROUND

Hyperandrogenism is a common endocrine disorder occurring in women of reproductive age group. Androgen secreting ovarian tumours represents less than 5% of all ovarian neoplasms<sup>1</sup>. Davis et al in the year 1900 described first case of ovarian tumour with virilisation,<sup>2</sup> & over century the number of cases reported in literature has been increased. Ovarian neoplasms like sex cord stromal tumours are associated with excess production of androgens. In other tumours of ovary like epithelial, germ cells or metastatic, the neoplastic nonsteroidogenic cells induce abnormal sex steroidal response in ovarian stromal cells which leads to the development of clinical manifestations of virilisation.<sup>3</sup> The objective of this study is to look for incidence of virilisation in sex cord stromal tumours and discussion regarding various causes of hyperandrogenism.

#### MATERIALS & METHODS

A retrospective descriptive study of virilising tumours of ovary was conducted in a tertiary care gynaecological centre in Chennai for a period of 5 years from February 2012 to February 2017. All the relevant data were collected from our record sections & histological slides were reviewed to confirm the diagnosis. During the study period, 36 cases of sex cord stromal tumours were identified out of which 4 cases presented with signs of virilisation.

#### RESULTS

A total of 592 ovarian malignancies were identified, out of which 36 cases were diagnosed as sex cord stromal tumours with incidence being 6.08%. The most common age group affected are between 41 to 50 yrs. with median age of 45 yrs. (Figure 1). The right sided ovary (58%) was most commonly involved than left sided ovaries (42%) with almost all cases are unilateral. Most of the tumours are solid (58%) in appearance followed by solid & cystic (36%) with only 2 cases cystic (6%) in appearance. The average sizes of the tumours are ranging from 6 cm-10 cm. The most common presenting symptom is abdominal mass (64%) followed by post-menopausal bleeding (11%), menorrhagia (11%), hirsutism (11%) with abdominal mass in 4 cases and 2 cases are incidental finding (3 %) in hysterectomy specimen (Figure 2).

Adult Granulosa cell tumour was the most common sex cord stromal tumour with total of 11(31%) cases followed by

*'Financial or Other Competing Interest': None.*

*Submission 02-01-2018, Peer Review 01-02-2018,*

*Acceptance 07-02-2018, Published 12-02-2018.*

*Corresponding Author:*

*Dr. Mahendran Revathy,*

*No. 25, Cholan Street,*

*Rajajipuram,*

*Trivellore-602001.*

*E-mail: drrevsagni0486@gmail.com*

*DOI: 10.14260/jemds/2018/202*



the coma 8 (22%) cases. The other cases reported were 4 cases of fibroma (10%), 3 cases of massive stromal oedema & granulosa cell tumour with the coma (8%), 2 cases of cystic variant of Adult granulosa cell tumour (6%), & 1 case each of fibrothecoma (3%), Juvenile granulosa cell tumour (3%), Sertoli Leydig cell tumour (3%), steroid cell tumour (3%) and Sclerosing stromal cell tumour(3%) (Figure 3).

The details of presenting symptoms, surgical procedure done, histopathological diagnosis & follow up details of all 4 cases of hirsutism with abdominal mass are presented in table 1.

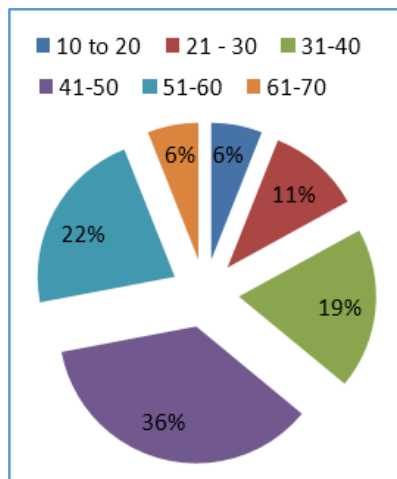


Figure 1. Distribution of cases based on age groups

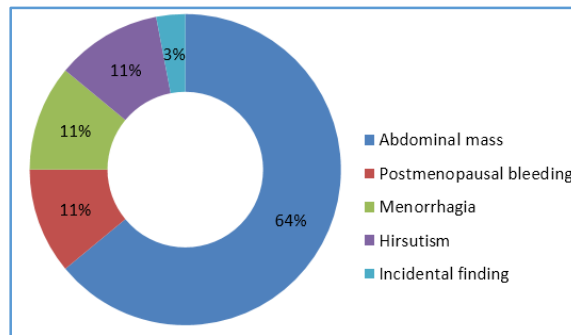


Figure 2. Distribution of cases based on symptoms

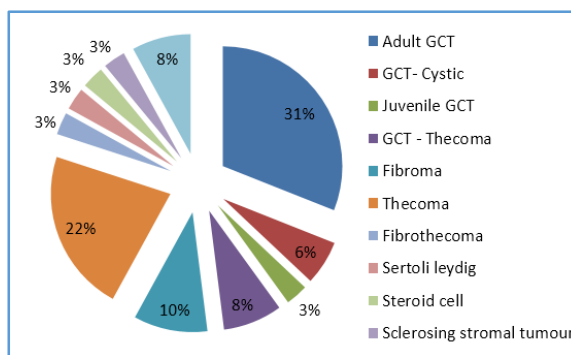


Figure 3. Distribution of cases based on Histopathological diagnosis

Sl. No.	Age Yrs.	Clinical History	Procedure Done	Hormonal Status	HPE	Follow Up (2yrs)
1	32	Amenorrhoea with hirsutism	Staging laparotomy - Right ovary	Total testosterone 4.120 ng/dl, and was persistently elevated in male pattern in dexamethasone suppression test	Sertoli Leydig cell tumour	Asymptomatic during 2 yrs. follow up period
2	36	Amenorrhoea with hirsutism	Left cystectomy	Total testosterone - 5.68 ng/dl	Adult Granulosa cell tumour- cystic variant	Patient died due to decompensated cardiac disease
3	19	Amenorrhoea with hirsutism	Left oophorectomy	Total testosterone - 10.5 ng/dl	Juvenile granulosa cell tumour	At 13 months of follow up patient developed recurrence & died due to disseminated disease.
4	42	Abdominal pain with hirsutism	Staging laparotomy- Right ovary	Not done as patient was taken up for emergency surgery	Steroid cell tumour	Asymptomatic during 2 yrs. follow up period

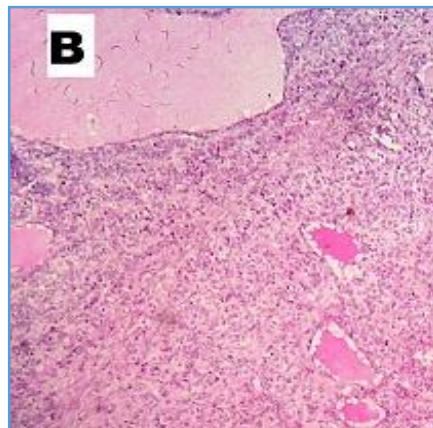
Table 1. Case series of virilisation

Common Cause	Rare Lesion
Polycystic ovarian syndrome	
Idiopathic hirsutism	Severe insulin resistance syndrome
Androgen secreting ovarian tumours <ul style="list-style-type: none"> <li>Sertoli Leydig cell tumour</li> <li>Steroid cell tumours - NOS</li> <li>Sclerosing stromal cell tumour</li> <li>Leydig cell tumour</li> <li>Stromal luteoma</li> <li>Gynandroblastoma</li> <li>Gonadoblastoma</li> </ul>	<ul style="list-style-type: none"> <li>Granulosa cell tumour</li> <li>Thecoma</li> </ul>
Androgen secreting adrenal tumours <ul style="list-style-type: none"> <li>Adrenal gland hyperplasia</li> <li>Adenoma &amp; carcinoma</li> </ul>	

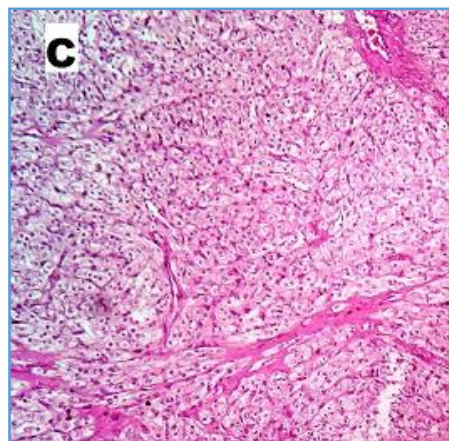
Tumour like conditions: <ul style="list-style-type: none"> <li>• Stromal hyperplasia</li> <li>• Stromal hyperthecosis</li> <li>• Pregnancy luteomas</li> <li>• Hyperreactioluteinialis</li> </ul>	Rare functioning ovarian tumours: <ul style="list-style-type: none"> <li>• Benign cystic teratoma</li> <li>• Endometrial tumours</li> <li>• Serous &amp; mucinous cystadenomas</li> <li>• Brenner tumours</li> <li>• Leiomyoma</li> <li>• Metastatic tumours.</li> </ul>
Cushing's syndrome Exogenous drugs. Congenital adrenal hyperplasia.	
<b>Table 2. Causes of hyperandrogenism</b>	

Causes	Investigations	Additional tests
Ovarian neoplasms	Increase in testosterone Normal/ mild increase in DHEAS	Imaging – USG, MRI
Adrenal neoplasms	Increase in testosterone Increase in DHEAS Increase in urine 17 ketosteroids	Imaging – USG, MRI
Congenital adrenal hyperplasia	Increase in testosterone Increase in 17 hydroxyprogesterone	ACTH stimulation test is necessary to make diagnosis
PCOS	Increase in LH, Prolactin	
Drugs Familial/ Idiopathic	Normal levels of all hormones.	
Cushing's Syndrome	Elevated serum cortisol	

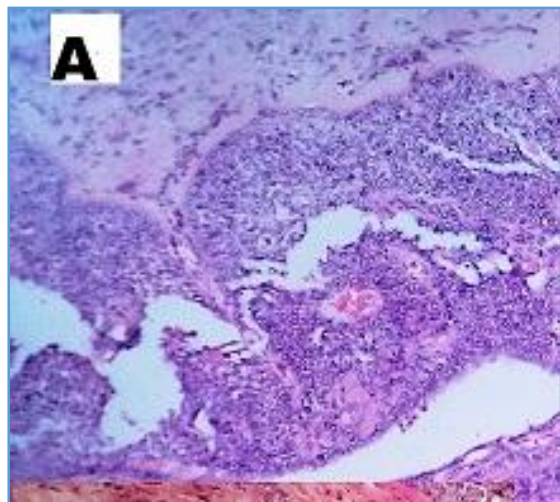
**Table 3. Laboratory investigations in Hyperandrogenism**



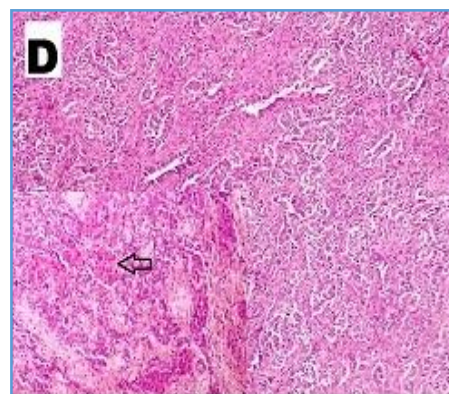
**Figure B. Juvenile granulosa cell tumour – shows follicular pattern of cells with central eosinophilic material and round nucleus without nuclear grooves. H&E x 10**



**Figure C. Steroid cell tumour – shows round to polygonal cell with granular eosinophilic cytoplasm & hyalinised stroma. H&E x 10.**



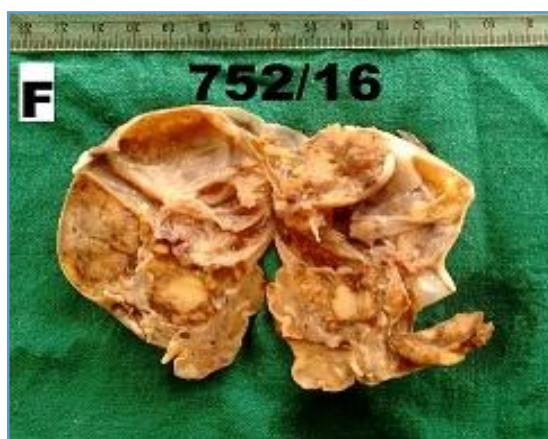**Figure A. Cystic variant of Adult granulosa cell tumour – cyst wall lined by multi-layered granulosa cells H&E x 10, insert shows Call Exner bodies within stroma. H&E x 4**



**Figure D. Sertoli Leydig cell tumour – showing Sertoli cells arranged in cords & trabeculae. Inset – Clusters of Leydig cells (arrow) H&E x 10**



**Figure E. Clinical picture of Sertoli cell tumour – showing frontal bossing, increased facial hair.**



**Figure F. Gross: Solid & cystic appearance of Sertoli Leydig cell tumour**

## DISCUSSION

In females, androgens are secreted by both adrenal glands & ovaries. The major androgens that are secreted are testosterone, dihydrotestosterone, dehydroepiandrosterone (DHEA), its sulphated form (DHEAS) & androstenedione. Adrenal glands secrete androgens in response to adrenocorticotropic hormone (ACTH) whereas ovaries produce in response to follicle stimulating hormones (FSH) & luteinising hormone (LH). The most important circulating androgen is testosterone & its active metabolite dihydrotestosterone. 80% of testosterone released is bound to sex hormone binding globulin (SHBG), 19% to albumin & remaining 1% is free testosterone which is the active form. These circulating androgens are metabolised in liver, conjugated with glucuronic acids or sulphuric acids and excreted in urine as 17 ketosteroids.<sup>4</sup>

The underlying cause of androgen excess can be assessed with detailed clinical history, age of onset, duration & severity of symptoms, physical examination & serum hormones.

## Clinical Manifestations

The clinical signs & symptoms of hormone producing tumours depend upon age, pre/post-menopausal state and amount of androgen levels in blood. In children it causes

heterosexual precocity with acceleration of growth, hirsutism & acne. In prepubertal girls it causes virilisation whereas in adult women it causes menstrual irregularities, clitoromegaly & hirsutism.<sup>5</sup>

The other symptoms that can occur in virilisation include male pattern balding, deepening of voice, skeletal muscle hypertrophy, breast atrophy & marked growth of facial and body hair.

William et al in his 10 yr study of 462 functioning ovarian tumours, has classified two definite phases of signs and symptoms in virilising tumours.<sup>6</sup> The first one is phase of defeminisation followed by phase of masculinisation. In early phase, there will be oligomenorrhoea or amenorrhoea with involution of breasts and loss of female body contour. The late phase includes acne, hirsutism, clitoral enlargement, increased libido, sterility, enlargement of larynx, deepening of the voice and temporal alopecia.<sup>7,8</sup>

## Causes of Virilisation in Ovarian Pathology

There are many tumours & tumour like conditions that secrete sex steroid resulting in hyperandrogenism & hyperoestrogenism. Ovarian tumours that usually secrete androgens are sex cord stromal tumours like Sertoli Leydig cell tumours, steroid cell tumours not otherwise specified (NOS), Leydig cell tumour (hilar & non-hilar type). The other causes of hyperandrogenism are depicted in table 2.

## Sex Cord Stromal Tumours

Sex cord stromal tumours are ovarian tumours that have unique manifestations due to hormone production both estrogenic and androgenic leading to broad spectrum of clinical features. Androgenic tumours are Sertoli Leydig cell tumours, steroid cell tumours, rarely juvenile granulosa cell tumour and cystic variant of adult granulosa cell tumour. All these entities encountered in this present study.

Sertoli Leydig cell tumours (SLCT) are the most common cause of virilising neoplasm of ovary & constitute about 1% of ovarian tumours. Demidov et al in their study of 22 cases of SLCT found that 30% of these tumours are virilising and small percentage cause estrogenic effects<sup>9</sup>. A study conducted by Taylor & Norris<sup>10</sup> on 30 lipid cell tumours of ovary shows virilisation in 77% of the cases, 5-23% shows estrogenic activity and 10% associated with Cushing's Syndrome. Granulosa cell tumour usually produces oestrogens, but rarely androgenic change may occur. 50% of granulosa cell tumours with cystic gross appearance are associated with androgenic manifestations<sup>11</sup>. Till date less than 50 cases of granulosa cell tumours with virilisation have been reported.<sup>12</sup>

## Ovarian Tumours with Functioning Stroma

Some benign or malignant (primary & metastatic) ovarian tumours are hormonally active as they secrete steroid hormones by stromal cells either within or adjacent to tumours. The most common primary ovarian tumour that produce androgens are benign cystic teratoma,<sup>13</sup> Serous<sup>14</sup> & mucinous cystadenomas,<sup>15</sup> Brenner tumour,<sup>16</sup> leiomyoma<sup>17,18</sup> and metastatic tumours that secrete androgens are Krukenberg tumour.<sup>19</sup>

Scully RE in his study of 24 cases in ovarian tumours with functioning ovarian stroma classifies these cells into 3 types. They are stromal luteal cells, Leydig cells & hilus cell types. Stromal luteal cells produce estrogenic manifestations

whereas stromal Leydig cells & hilus cell type produces androgenic manifestations.<sup>20</sup>

The major source of steroid production in these tumours occurs due to hyperplasia of adjacent stroma either with or without luteinisation. According to Baldwin et al this hyperplasia is due to mechanical effect on the stroma by the tumour which in turn stimulates stromal cells to produce androgens.<sup>21</sup> There are certain theories to support this hyperplasia of stromal cells in ovarian tumours with functioning stroma.

Alpha glutathione S transferase has shown to be Immunohistochemical (IHC) marker for delta isomerase, an enzyme active in steroidogenesis. Tiltman et al,<sup>22</sup> in their study of 53 epithelial tumours of ovary showed positive staining in luteinized stromal cells of both benign & malignant mucinous tumours. IHC staining of alpha glutathione S transferase in the cytoplasm of ovarian stromal cells of these tumours indicating steroidogenesis.

Hugheson postulated mechanical effect theory, in that the steroidogenesis by these stromal cells is due to the mechanical effect of expanding follicles.<sup>23</sup> The other theory for origin of oestrogen in postmenopausal women is due to high circulating levels of pituitary gonadotrophins / HCG leading to stromal steroidogenesis as postulated in the study of Baldwin et al<sup>21</sup> & Macdonald et al.<sup>24</sup> In tropic effect theory the tumour cells produce a substance that simulates the adjacent stromal cells to secrete hormones.

### Tumour like Lesions

82% of hyperandrogenism in women of reproductive age groups is due to polycystic ovaries<sup>25</sup>. It usually begins in puberty & causes hirsutism, menstrual irregularities, and insulin resistance. There are two mechanisms in which PCOS produces androgens-

1. Increased insulin levels in blood inhibits serum human binding globulin (SHBG) which in turn increases free androgens as shown in studies by Plymate et al in human hepatoma cell lines.<sup>26</sup>
2. Increase in LH stimulates ovarian theca cells to produce excess androgens as shown in studies conducted in PCOS theca cell cultures.<sup>27</sup>

Idiopathic hirsutism is a common cause of virilisation occurring after puberty, which are slowly progressive & are often familial. They are diagnosis of exclusion & occur due to disorder in peripheral androgen activity.<sup>28</sup>

Pregnancy luteomas are asymptomatic hyperplastic tumour like lesions that are discovered incidentally during surgery. Patients will be hormonally active, and the symptoms disappear after delivery.<sup>29</sup>

### Adrenal Causes

Adrenal causes of virilisation include Cushing's syndrome, congenital adrenal hyperplasia (classical & non-classical), adrenal adenoma & carcinoma. Cushing's syndrome must be differentiated from polycystic ovarian syndrome as both have same clinical manifestations except for the elevated level of serum cortisol in Cushing's syndrome & some physical characteristics like central obesity, facial plethora, moon face, and violaceous abdominal striae greater than 1 cm.<sup>30,31</sup>

Congenital adrenal hyperplasia (CAH) occurs due to deficiency of 21 alpha hydroxylase resulting in accumulation of steroid precursors which are subsequently converted into

androgens. There are two types, classical & non-classical. Classical CAH usually presents at birth whereas non-classical CAH does not present until early puberty. Classical type produces clitoral enlargement in females at birth & masculinising features develop as the child grows. In non-classical type there will be premature development of pubic hair, acne & menstrual irregularities.<sup>30,32</sup>

Adrenal adenomas<sup>33</sup> & carcinomas also produce androgens leading to virilisation.

### Exogenous Androgens

Many drugs induce hyperandrogenism but the most common drug to induce is synthetic progestins like norgestrel. There are two mechanisms in which synthetic progestins increases testosterone levels. First, they bind directly to androgen receptors thereby inducing androgenic effects; secondly, they decrease serum human binding globulin and increases circulating active testosterone<sup>30</sup>. Other drugs which induce hyperandrogenism are danazol & anabolic steroids.

### Investigations

The laboratory investigations that are usually done for hyperandrogenism are serum testosterone, DHEA & DHEAS, 17 hydroxyprogesterone, low dose dexamethasone suppression test, urinary 17 ketosteroid, serum cortisol & prolactin. The laboratory tests in various causes of hyperandrogenism are depicted in table 3.

### CONCLUSION

Patients presenting with symptoms of virilisation require detailed clinical history, physical examination for signs, laboratory investigations & imaging. Rapid development of hirsutism, late onset & signs of virilisation should raise suspicion of androgen secreting ovarian neoplasm from adrenal tumours. Serum testosterone level with DHEAS helps in differentiating androgen secreting ovarian or adrenal tumours.

### Abbreviations

PCOS – Polycystic ovarian syndrome.  
ACTH – Adrenocorticotrophic hormone.  
FSH – Follicle stimulating hormone.  
LH – Luteinising hormone.  
DHEA – Dehydroepiandrosterone.  
DHEAS – Dehydroepiandrosterone sulfate.  
17 OHP – 17 hydroxy progesterone.  
IHC – Immunohistochemistry.

### REFERENCES

- [1] Souto SB, Baptista PV, Braga DC, et al. Ovarian Leydig cell tumor in a post-menopausal patient with severe hyperandrogenism. *Arquivos Brasileiros de Endocrinologia & Metabologia* 2014;58(1):68-75.
- [2] Davis GG. Multilocular cystic growth of ovary, accompanied by increased growth of hair and change of voice, with recurrence in the abdominal incision. *Am J Obst* 1900;41:620-4.
- [3] Lopez-Beltran A, Calanas AS, Jimena P, et al. Virilizing mature ovarian cystic teratomas. *Virchows Archiv* 1997;431(2):149-51.

- [4] Meek CL, Bravis V, Don A, et al. Polycystic ovary syndrome and the differential diagnosis of hyperandrogenism. *The Obstetrician & Gynaecologist* 2013;15(3):171-6.
- [5] Rubido Valle CD, Fuente de la JLC, Martinez CS, et al. Ovarian steroid cell tumor associated to endometrial hyperplasia and presenting as postmenopausal vaginal bleeding. *Gynecol Obstet (Sunnyvale)* 2015;5(9):1-4.
- [6] Hill WE, Clark JFJ. Functional ovarian tumors: a ten year study at Freedmen's hospital. *Journal of the National Medical Association* 1964;56(1):66-70.
- [7] Saxena S, Meena R, Khokhar HVS, et al. Uncommon cause of secondary amenorrhea and hirsutism: steroid cell tumor of ovary (case report). *IOSR Journal of Dental and Medical Sciences (IOSR-JDMS)* 2015;14(12):16-9.
- [8] Salim S, Shantha GP, Patel AD, et al. Virilizing ovarian steroid cell tumor in a 40 year old South Indian female: a case report. *Cases Journal* 2009;2(1):7521.
- [9] Demidov VN, Lipatenkova J, Vikhareva O, et al. Imaging of gynecological disease (2): clinical and ultrasound characteristics of Sertoli cell tumors, Sertoli-Leydig cell tumors and Leydig cell tumors. *Ultrasound in Obstetrics & Gynecology* 2008;31(1):85-91.
- [10] Taylor HB, Norris HJ. Lipid cell tumors of the ovary. *Cancer* 1967;20(11):1953-62.
- [11] Young RH. Sex cord-stromal, steroid cell, and other ovarian tumors with endocrine, paraendocrine and paraneoplastic manifestations. In: Kurman RJ, Hedrick Ellenson L, Ronnett BM, eds. *Blaustein's Pathology of the female genital tract*. New York, US: Springer 2011: p. 785-846.
- [12] Kota SK, Gayatri K, Pani JP, et al. Ovarian granulosa cell tumor: an uncommon presentation with primary amenorrhea and virilization in a pubertal girl. *Indian Journal of Endocrinology and Metabolism* 2012;16(5):836-9.
- [13] Subbaiah M, Dorairajan G, Gochhait D, et al. Virilization in a postmenopausal female due to androgen secreting ovarian dermoid cyst. *J Mid-life Health* 2017;8(2):98-100.
- [14] Beauchamp PJ, Hughes RS, Schmidt WA. Virilizing serous cystadenoma. *Obstetrics & Gynecology* 1989;73(3 Pt 2):513-7.
- [15] Kucur SK, Acar C, Temizkan O, et al. A huge ovarian mucinous cystadenoma causing virilization, preterm labor and persistent supine hypotensive syndrome during pregnancy. *Autopsy & Case Reports* 2016;6(2):39-43.
- [16] Hamwi GJ, Byron RC, Besch PK, et al. Testosterone synthesis by a Brenner tumour: Part I. Clinical evidence of masculinisation during pregnancy. *American Journal of Obstetrics and Gynecology* 1963;86(8):1015-20.
- [17] Carpen O, Simberg N, Sasano H, et al. Virilizing ovarian leiomyoma: androgen production by lining stromal cells. *Acta Obstet Gynecol Scandinavica* 1996;75(1):72-6.
- [18] Parish JM, Lufkin EG, Lee RA, et al. Ovarian leiomyoma with hilus cell hyperplasia that caused virilization. *Mayo Clinic Proceedings* 1984;59(4):275-7.
- [19] Scully RE, Richardson GS. Luteinization of the stroma of metastatic cancer involving the ovary and its endocrine significance. *Cancer* 1961;14(4):827-40.
- [20] Scully RE. Ovarian tumours with functioning stroma. In: Haines, Taylor. *Obstetrical and gynaecological pathology*. 4<sup>th</sup> edn. New York: Churchill-Livingstone 1995.
- [21] Baldwin LJ, Singh N, Tiltman A. Virilisation in a case of transitional cell carcinoma of the ovary. *Journal of Clinical Pathology* 2004;57(12):1331-2.
- [22] Tiltman AJ, Ali H. Distribution of alpha glutathione S-transferase in ovarian neoplasms: an immunohistochemical study. *Histopathology* 2001;39(3):266-72.
- [23] Hughesdon PE. Thecal and allied reactions in epithelial ovarian tumours. *BJOG: An International Journal of Obstetrics & Gynaecology* 1958;65(5):702-9.
- [24] MacDonald PC, Grodin JM, Edman CD, et al. Origin of estrogen in a postmenopausal woman with a nonendocrine tumor of the ovary and endometrial hyperplasia. *Obstetrics & Gynecology* 1976;47(6):644-50.
- [25] Pidaparthi P. Hyperandrogenism due to ovarian tumour mimicking PCOS: a case report. *Int J Reprod Contracept Obstet & Gynecol* 2013;2(3):482-4.
- [26] Plymate SR, Matej LA, Jones RE, et al. Inhibition of sex hormone-binding globulin production in the human hepatoma (Hep G2) cell line by insulin and prolactin. *The Journal of Clinical Endocrinology & Metabolism* 1988;67(3):460-4.
- [27] Barbieri RL, Makris A, Ryan KJ. Insulin stimulates androgen accumulation in incubations of human ovarian stroma and theca. *Obstetrics & Gynecology* 1984;64(Suppl 3):S73-S80.
- [28] Hunter MH, Carek PJ. Evaluation and treatment of women with hirsutism. *American Family Physician* 2003;67(12):2565-72.
- [29] Wang YC, Su HY, Liu JY, et al. Maternal and female fetal virilization caused by pregnancy luteomas. *Fertility and Sterility* 2005;84(2):509.e15-e17.
- [30] Karnath BM. Signs of hyperandrogenism in women. *Hospital Physician* 2008;44:25-30.
- [31] Karnath BM, Ojo OB. Cushing's syndrome. *Hospital Physician* 2008: p. 25-9.
- [32] Speiser PW, White PC. Congenital adrenal hyperplasia. *New England Journal of Medicine* 2003;349(8):776-88.
- [33] Gangkak G, Yadav S, Verma S, et al. Pure androgen secreting adrenal adenoma: a case report and review of literature. *Clinical Nephrology and Urology Science* 2015;2(2):1-5.