

## REVIEW ARTICLE

### CAESAREAN MYOMECTOMY- A VERSATILE PROCEDURE FOR MANAGEMENT OF FIBROIDS AT C. SECTION

Miriam George Fenn<sup>1</sup>, Mini Isac<sup>2</sup>

#### HOW TO CITE THIS ARTICLE:

Miriam George Fenn, Mini Isac. "Caesarean Myomectomy- A Versatile Procedure for Management of Fibroids at C. Section". Journal of Evolution of Medical and Dental Sciences 2015; Vol. 4, Issue 11, February 05; Page: 1863-1866, DOI: 10.14260/jemds/2015/266

**ABSTRACT: OBJECTIVE:** To study all Caesarean myomectomies done at a tertiary center in South India. **METHODS:** 29 cases of Caesarean myomectomies were performed from 2004 to 2014, at our institution – a tertiary referral center. The type of fibroids, number and size of myomas, need for blood transfusions, and operating time and post-operative morbidity at Caesarean myomectomy were studied. **RESULTS:** We had equal number of subserous and intramural fibroids, and one large sub mucous fibroid removed at surgery. 7 fibroids were very large (> 10 cm diameter). 6 patients had more than 3 fibroids removed at surgery. 8 required blood transfusions, and none of our patients required hysterectomy. **CONCLUSION:** The authors find Caesarean myomectomy a feasible and safe option in women with fibroids undergoing Caesarean section.

**KEYWORDS:** Caesarean myomectomy, leiomyomas in pregnancy.

**INTRODUCTION:** The incidence of leiomyomas in pregnancy is 2–4%. Elective myomectomy at the time of Caesarean section has been traditionally discouraged due to the attendant morbidity, primarily from haemorrhage. If myomectomy during Caesarean section becomes widely accepted practice, it could eliminate the need for a second operation in these patients. Only few small randomized controlled studies are available, hence the proportion of surgeons attempting this combined procedure is low, due to concerns regarding safety.<sup>1</sup> At times, due to its location at the lower segment, large myoma removal is mandatory in order to deliver the baby, at Caesarean section.<sup>2</sup>

British gynaecological surgeon Victor Bonney, who did extensive work on cancer cervix cases, also perfected the procedure of myomectomy and introduced his instrument also for use in the same – thereby conserving fertility of many fibroid patients, who till then were having hysterectomy.<sup>3</sup>

**METHODS:** This is a retrospective analysis of case records of all patients with fibroids complicating pregnancy, which underwent Caesarean section with concomitant myomectomy. Totally 29 cases have been performed in this tertiary referral hospital, during the time period from 2004 to 2014.

Indications for LSCS	
Prev LSCS	9
Previous myomectomies	4
Lower segment fibroid	3
Primi with other indications	13

Table 1.1

## REVIEW ARTICLE

The above table gives the indications for which LSCS was performed in each of the 29 patients. This included 4 patients who had earlier undergone myomectomy, and now presented with recurrent fibroid in pregnancy. In 3 patients, fibroid was situated in the lower segment – and in two of these, the obstructing fibroid had to be excised first in order to facilitate delivery of the baby at C.section.

Sub serous and intra mural were the majority (14 patients each) with only one sub mucous variety of fibroid.

Type of fibroid	(N=29)
Sub serous	14
Intra mural	14
Sub mucous	1

Table 1.2

Large fibroids measuring more than 10cm across were 7 in number.

Size	(N=29)
< 5 cm	12
5-10 cm	10
>10 cm	7

Table 1.3

Only 6 patients had multiple fibroids removed at surgery (greater than 3).

No. of fibroids	(N=29)
Single	23
Multiple	6

Table 1.4

As far as the procedure is concerned, intra lesional injection of vasopressin greatly helped haemostasis during dissection. Though vertical incision was used over the most dependent part of the myomas till 4 years ago, currently we use transverse incision. Tumour bed was obliterated with delayed absorbable sutures (2-0 polyglactin), taking meticulous care of the haemostasis. With the above mentioned techniques, operating time was reasonable - only 3 patients needing more than 2 hours of surgical time.

Operating time	(N=29)
< 2 hrs	26
2-4 hrs	3
>4 hrs	0

Table 1.5

## REVIEW ARTICLE

8 of our patients were transfused blood during surgery. 1 patient required 2 pints of blood transfusion.

Need for blood transfusion	(n=29)
Yes	8
No	21

Table 1.6

2 patients had fever in the post-operative period, which settled without much morbidity.

**DISCUSSION:** With more and more women postponing pregnancy for career issues, fibroids in pregnancy will definitely be on the rise. Caesarean myomectomy, if done in well-equipped centers is a definite and safe option for these mothers. Also beneficial in terms of finances to the individual and the health sector, since interval myomectomy is avoided.

Puerperal uterine sub involution could be avoided, so also other complications related to fibroids – namely menorrhagia, anaemia and pain (From torsion or red degeneration) during subsequent pregnancy.<sup>4</sup>

With use of intra lesional injection of vasopressin blood loss is greatly minimized giving a good plane of dissection. Thus concomitant myomectomy along with C.section is definitely justified as a safe procedure – in our experience. Post-operative morbidity does not seem to be any higher than a routinely performed LSCS. Fertility also is not compromised as a result of the procedure.<sup>5,6,7</sup>

### OPERATIVE PHOTOGRAPHS:

Fig 1.1 Uterus showing large posterior intra mural fibroid.

Fig 1.2 myomectomy in progress.

Fig 1.3 myoma bed after closure.

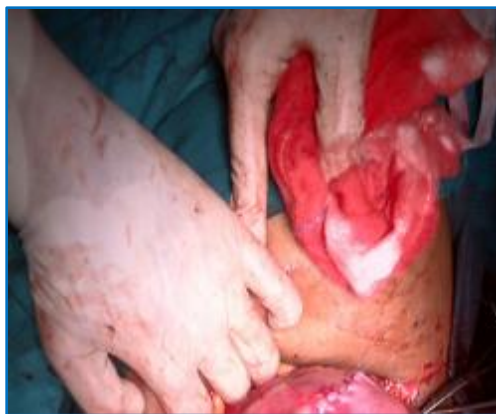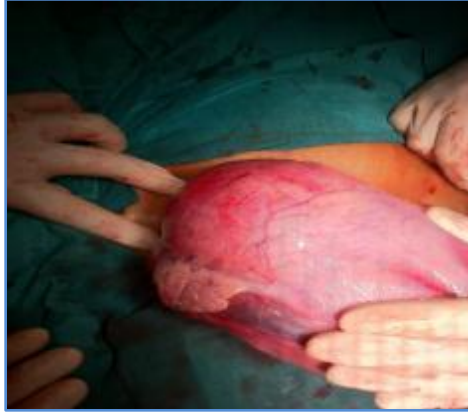


Fig. 1.1

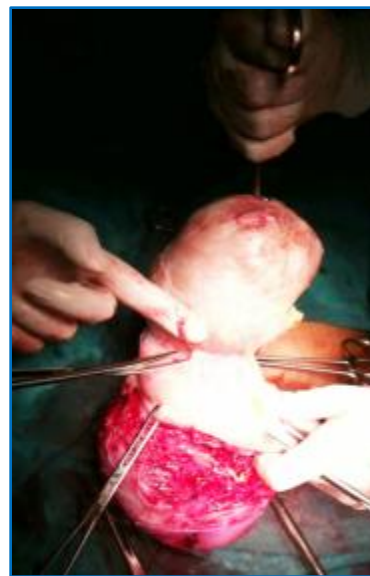

Fig. 1.2

## REVIEW ARTICLE



**Fig. 1.3**

### REFERENCES:

1. Brown D<sup>1</sup>, Fletcher HM, Myrie MO, Reid M. Caesarean myomectomy--a safe procedure. A retrospective case controlled study. *J Obstet Gynecol* 1999 Mar; 19(2):139-41.
2. Mahendru R<sup>1</sup>, Sekhon PK, Gaba G, Yadav S. At times, myomectomy is mandatory to effect delivery. *Ann Surg Innov Res* 2011 Oct 28; 5(1):9. doi: 10.1186/1750-1164-5-9.
3. Jauniaux E, Khan KS. Caesarean myomectomy: Victor Bonney reports the first case in 1913. *BJOG* 2014 Jan; 121(2):193. doi: 10.1111/1471-0528.12548.
4. Rich DA<sup>1</sup>, Stokes IM. Uterine torsion due to a fibroid, emergency myomectomy and transverse upper segment caesarean section. *BJOG* 2002 Jan; 109(1):105-6.
5. Awoleke JO<sup>1</sup>. Myomectomy during Caesarean Birth in Fibroid - Endemic, Low-Resource Settings. *Obstet Gynecol Int* 2013; 2013:520834. doi: 10.1155/2013/520834. Epub 2013 Nov 14.
6. Incebiyik A<sup>1</sup>, Hilali NG, Camuzcuoglu A, Vural M, Camuzcuoglu H. Myomectomy during Caesarean: a retrospective evaluation of 16 cases. *Arch Gynecol Obstet* 2014 Mar; 289(3): 569-73. doi: 10.1007/s00404-013-3019-1. Epub 2013 Sep 8.
7. Machado LS<sup>1</sup>, Gowri V, Al-Riyami N, Al-Kharusi L. Caesarean Myomectomy: Feasibility and safety. *Sultan Qaboos Univ Med J* 2012 May; 12(2):190-6. Epub 2012 Apr 9.

### AUTHORS:

1. Miriam George Fenn
2. Mini Isac

### PARTICULARS OF CONTRIBUTORS:

1. Associate Professor, Department of Obstetrics & Gynaecology, MOSC Medical College, Kolenchery, Kerala.
2. Professor, Department of Obstetrics & Gynaecology, MOSC Medical College, Kolenchery, Kerala.

### NAME ADDRESS EMAIL ID OF THE CORRESPONDING AUTHOR:

Dr. Miriam George Fenn,  
Associate Professor,  
Department of Obstetrics & Gynaecology,  
MOSC Medical College, Kolenchery,  
Ernakulam District, Kerala- 682311.  
E-mail: jacobchundamannil68@gmail.com

Date of Submission: 13/01/2015.  
Date of Peer Review: 14/01/2015.  
Date of Acceptance: 27/01/2015.  
Date of Publishing: 04/02/2015.