

CASE REPORT

UTERINE LEIOMYOMATOSIS WITH OSSIFICATION: CASE REPORT OF A RARE ENTITY

Lekha M. B¹, Vijaya C², Aparna Narasimha³, Archana Shetty⁴

HOW TO CITE THIS ARTICLE:

Lekha M. B, Vijaya C, Aparna Narasimha, Archana Shetty. "Uterine Leiomyomatosis with Ossification: Case Report of a Rare Entity". Journal of Evolution of Medical and Dental Sciences 2014; Vol. 3, Issue 13, March 31; Page: 3234-3237, DOI: 10.14260/jemds/2014/2273

ABSTRACT: Leiomyomas are benign and common smooth muscle neoplasms, occurring commonly in uterus. A spectrum of histological variants and secondary changes may accompany this entity; however ossification in a leiomyoma is a rare phenomenon. We hereby report a case of a 50 year old lady, with pain abdomen since two months, who underwent hysterectomy for multiple fibroids. The largest fibroid showed a focus of ossification along with hyaline degeneration, the documentation of this being very rare in literature.

KEYWORDS: Ossification, Leiomyomatosis, Calcification.

INTRODUCTION: Leiomyomas are benign and most common smooth muscle neoplasms. Most common being sites include uterus, small bowel and esophagus. Leiomyomas are also referred as fibroid, myoma, fibromyoma and fibroleiomyoma¹. Leiomyoma of uterus is of 3 types, based on location classified as submucosal, intramural and subserosal. Leiomyoma predominantly affects women of reproductive age, they can be found in 20-30% of women in their fourth decade, and >40% of women in their fifth decade².

Various secondary changes can occur in leiomyoma like hyaline degeneration, cystic change, myxoid degeneration, necrosis and calcification and ossification which is very rare. Most of these changes result from inadequate blood supply resulting in replacement of muscle fibers by hyaline material, collagen, calcium mucopolysaccharide or a combination of these^{3, 4}. There is limited literature regarding ossification. We hereby report this case because of its rarity.

CASE REPORT: A 50 year old female presented to the gynecological out-patient department with complaints of loss of appetite and pain abdomen since 2 months. Ultrasound showed an anteverted bulky uterus with a calcified intramural fibroid measuring 3.8x3.5cms arising from the anterior wall of the uterus. Further abdominal computer tomography done confirmed the findings. Laboratory studies revealed microcytic anemia with a hemoglobin level of 11g/dl. All other biochemical parameters values were within normal limits. Hysterectomy was done and the specimen was sent for histopathological examination. On gross, the specimen of uterus with cervix was bulky with bosselated external surface measuring 13 x 7x 5 cms.

Cut section shows multiple serosal and intramural fibroids, obliterating the endometrial cavity, largest measuring 4.5x3x3cm. Cut section of the fibroids was grey whit whorled appearance and at places gritty sensation on cutting along with areas of hemorrhage [Fig. 1]. On microscopic examination, showed leiomyomas composed of intersecting fascicles of closely packed cells with elongated nuclei and eosinophilic cytoplasm with secondary changes of hyalinization, ossification associated with hydropic degeneration [Fig 2, 3]. The final diagnosis of uterine leiomyomata with

CASE REPORT

secondary degeneration changes including ossification was made. The post-operative course was uneventful.

DISCUSSION: Uterine leiomyoma is a benign smooth muscle tumor that originates from the myometrium. Leiomyomas which are often multiple is designated as leiomyomatosis if they are many in number. The reason for the frequent development of leiomyoma in the uterus is suspected to be hormonal influences especially estrogen, growth hormone and progesterone. These tumors are typically found during reproductive years and are known to regress after menopause.

A variety of degenerative changes occur in leiomyomas depending on the degree and rapidity of vascular insufficiency. The types of degeneration include hyaline, myxoid, mucinous, cystic, hemorrhagic and calcification. However, ossification in leiomyoma is rare³⁻⁵. Ossification in uterine leiomyoma is heterotrophic bone formation which is generally of membranous type. Frank osteoid material may be found as a sequel to an old missed abortion, ensuring on dystrophic calcification as a metaplastic phenomenon.

Calcification is a process of deposition of calcium in the tissue in the form of carbonate and phosphate, while ossification is a process of differentiation of connective tissue along with presence of collagen fibers blended with mucopolysaccharide and enclosing living cells. The mere presence of calcium salts in inducing ossification is not sufficient but presence of proliferating mesenchymal cells capable of metaplasia are equally essential.⁶⁻⁸ Ossification in leiomyoma is rare. Only 9 cases of ossified leiomyoma have been reported of which two arose in deep soft tissue.⁹

In a study conducted by Harsh Mohan et al on 900 cases of leiomyoma only 5 cases (0.55%) showed changes of ossification, which were also associated with other degenerative changes like hyalinization and calcification indicating a gradual transformation of degeneration¹⁰. In another study conducted by Persaud et al common degenerative changes seen in leiomyomas were hyaline change (63%), myxomatous change (13%), calcification (8%), cystic (4%), fatty change (3%) and sarcomatous change (0.7%). None of the cases showed changes of ossification⁴. Xu et al reported a case of ossified leiomyoma in a 34 year old African American with sickle cell thalessemia, who presented with a painful nodule of scapular region which appeared heavily mineralized soft tissue mass on chest radiography⁹.

A case of ossification with extensive calcification of uterine leiomyoma in a postmenopausal woman on autopsy was reported by Vijayalaxmi et al¹¹. The leiomyoma in our case also showed extensive calcification and ossification with hydropic degeneration which is a rare occurrence. This secondary change of ossification in post-menopausal females could be due to ignorance of a patient with late reporting to the gynecologist in the Indian subcontinent.

CONCLUSION: Ossification as a secondary change is generally present in the long standing leiomyomas with other degenerative changes like hyalinization and calcification. The present case showed ossification, hydropic degeneration along with calcification which is a rare occurrence.

REFERENCES:

1. American society of reproductive medicine patient booklet. Uterine fibroid; Available from: [://www.wbanc.amedd.army.mil/Documents/Departments/WomenHealth/Gynaecology/Obstetrics/uterine_fibroids.pdf](http://www.wbanc.amedd.army.mil/Documents/Departments/WomenHealth/Gynaecology/Obstetrics/uterine_fibroids.pdf).

CASE REPORT

2. Tavassoli FA, Devilee P (editors). Tumours of the Breast and Female Genital organs. 1st edition, Lyon France: International Agency for Research on Cancer, 2003).
3. Reddy DB, Rao N, Gopalrao DV. Ossifying myoma of the fallopian tube (Report of a case). *Ind J Pathol Bact* 1967; 10:368-371.
4. Persaud V, Arjoon PD. Uterine leiomyoma. Incidence of degenerative change and a correlation of associated symptoms. *Obstet Gynecol* 1970; 35:432-436.
5. Bhattacharya N, Banerji AK, Sengupta J. Ossification of leiomyoma. *J Ind Med Asso* 1998; 96:99. 4.
6. Padubidri V, Daftary SN. *Shaw's textbook of Gynecology*. 10th edn. New Delhi: B I Churchill Livingstone Pvt. Ltd. 1990, 405-411.
7. Novak ER, Woodruff JD. *Novak's Gynecologic and Obstetric Pathology*, 7th Asian edn. Tokyo: WB Saunders Company 1974, 249-252.
8. Boyd W. *A Textbook of Pathology. Structure and function in disease*. 8th edn. Philadelphia: Lea & Febiger 1970, 1300 - 01.
9. Xu Y, Lacouture M, Petronic-Rosic V, Soltani K, Shea C R. Ossified soft tissue leiomyoma in a patient with sickle cell anemia. *J Cutan Pathol* Nov 2005, 32(10), 696-99
10. H Mohan, R Punia, S Kumar, P Jain, U Handa. Ossification in Uterine Leiomyomas. *The Int J Gynecol Obstet* 2003, 2(1).
11. Vijayalaxmi V Suranagi, Hema BB, Davanagere R, Datala S. Ossification with Extensive Calcification of Uterine Leiomyoma in a Postmenopausal Woman. *J South Asian Feder Obst Gynae* 2012, 4(1), 54-55.

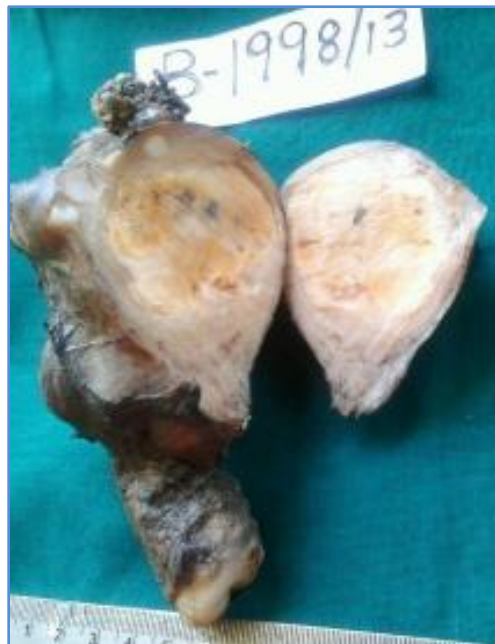

Fig. 1: Hysterectomy Specimen, cut section showing the largest fibroid with chalky white hard areas of calcification

CASE REPORT

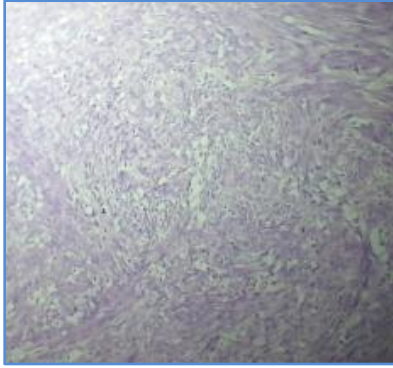


Fig. 2: H and E stain, 10X showing features of a typical leiomyoma

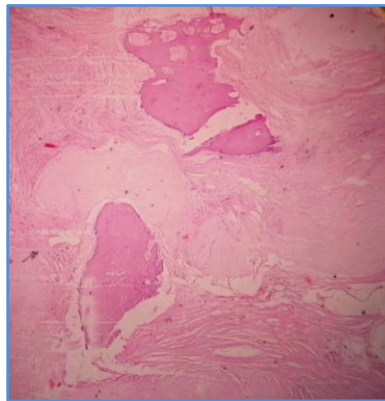


Fig. 3: Hand E stain 10x showing a focus of mature bone within the leiomyoma

AUTHORS:

1. Lekha M. B.
2. Vijaya C.
3. Aparna Narasimha
4. Archana Shetty

PARTICULARS OF CONTRIBUTORS:

1. Assistant Professor, Department of Pathology, Sapthagiri Institute of Medical Sciences and Research Center, Bangalore.
2. Professor and Head, Department of Pathology, Sapthagiri Institute of Medical Sciences and Research Center, Bangalore.
3. Professor, Department of Pathology, Sapthagiri Institute of Medical Sciences and Research Center, Bangalore.

4. Assistant Professor, Department of Pathology Sapthagiri Institute of Medical Sciences and Research Center, Bangalore.

NAME ADDRESS EMAIL ID OF THE CORRESPONDING AUTHOR:

Dr. Lekha M. B,
SIMS & RC, Hesaraghatta Main Road,
Street No.15, Chikkasandra,
Bangalore - 560090.
E-mail: dr_lekha@rediffmail.com

Date of Submission: 14/02/2014.

Date of Peer Review: 15/02/2014.

Date of Acceptance: 11/03/2014.

Date of Publishing: 25/03/2014.