

## CASE REPORT

---

### LINEAR POROKERATOSES: REPORT OF A RARE CASE WITH EFFECT OF ORAL RETINOIDS

Krishnendra Varma<sup>1</sup>, Harsh Sharma<sup>2</sup>

#### HOW TO CITE THIS ARTICLE:

Krishnendra Varma, Harsh Sharma. "Linear Porokeratoses: Report of a rare case with Effect of Oral Retinoids". Journal of Evolution of Medical and Dental Sciences 2014; Vol. 3, Issue 41, September 04; Page: 10398-10401, DOI: 10.14260/jemds/2014/3351

**INTRODUCTION:** Porokeratosis is an autosomal dominant genodermatosis with variable penetrance, characterized by a clonal disorder of keratinization with one or more atrophic patches surrounded by a clinically and histologically distinctive hyperkeratotic ridge like border called the cornoid lamella. Multiple clinical variants of porokeratosis are recognized. The original description of this entity was given in 1893 by Mibelli.<sup>[1]</sup>

#### Five different forms can be Distinguished:<sup>[2]</sup>

1. The plaque type classical porokeratosis of Mibelli,
2. Disseminated superficial actinic porokeratosis (DSAP),
3. Linear porokeratosis,
4. Porokeratosis plantaris, palmaris et disseminate,
5. Punctate porokeratosis.

**CASE REPORT:** A 15 year old girl presented with reddish-brown hyper keratotic hyper pigmented lesions on the right half of the body since birth. It was arranged in a linear pattern having a raised edge and atrophic center. They first appeared on the medial side of the right foot and then progressed linearly upwards to involve the leg, thigh and trunk on the same side.

On examination, the right half of the body was involved in the form of linearly arranged multiple discrete to coalescing hyper keratotic papules and annular plaques along the blaschko's line, in a nevoid pattern. On the trunk, lesions were mainly present in linear bands of 2-3 cm size. There was no nail dystrophy. Lesions were asymptomatic but cosmetically distressful. No response was noted to multiple topical and surgical modalities.

Routine haematological and urine analysis was normal.

Histopathological examination showed the presence of a central column of hyperkeratosis and parakeratosis, the cornoid lamella and reduced thickness of granular layer along with elongated rete ridges. Dermis showed scanty inflammatory cell infiltrate.

The patient was started on oral isotretinoin at a dose of 20 mg daily. After 3 months of therapy, flattening of lesions was observed. The patient is under regular follow up to evaluate its long term effectiveness.

**DISCUSSION:** Porokeratosis is an autosomal dominant genodermatosis with variable penetrance, characterized by a distinct peripheral keratotic ridge that corresponds histologically to the coronoid lamella. Loss of heterozygosity at 12q and sequence variations in genes at this locus are reported, but the significance of these findings is uncertain.<sup>[3]</sup>

## CASE REPORT

---

The centrifugal progress of individual lesions is thought to reflect the migration of a clone of abnormal cells. There is keratinocyte dysplasia and Otsuka et al .<sup>[4,5]</sup> have reported aneuploidy and chromosomal abnormalities in lesional keratinocytes.

Reed and Leone <sup>[1]</sup> postulated that the lesions arise in a clone of epidermal cells which can be seen as vacuolated cells underlying the cornoid lamella. This clone of cells spreads laterally with a growth rate more rapid than the resisting epithelial cells so that a fold on groove is formed at the point of pressure as the lesions spreads through the epidermis. Five different forms can be distinguished:<sup>[2]</sup>

1. The plaque type classical porokeratosis of Mibelli,
2. Disseminated superficial actinic porokeratosis (DSAP),
3. Linear porokeratosis,
4. Porokeratosis plantaris, palmaris et disseminate,
5. Punctate porokeratosis.

The exact cause of linear porokeratosis is unknown, but risk factors may include exposure to the sun or radiation, problems with the immune system (immunosuppression) or genetic predisposition.<sup>[6]</sup>

The characteristic histopathology is seen in the edge of the lesion. The stratum corneum is hyper keratotic, and at the raised border a column of poorly staining parakeratotic stratum corneum cells, the cornoid lamella. The underlying keratinocytes are oedematous with spongiosis, shrunken nuclei and a moderate dermal lymphocytic infiltrate under the lamella.<sup>[7]</sup>

Malignant degeneration and metastasis has been reported in this variety.<sup>[8]</sup>

Treatment of disseminated superficial porokeratosis usually unnecessary, but cryotherapy, carbon dioxide and pulsed dye laser therapy, and photodynamic treatment have all been used.<sup>[9]</sup> Keratolytics offer little relief. Topical tacalcitol,<sup>[10]</sup> 5-fluorouracil ointment, imiquimod cream<sup>[11]</sup> and oral etretinate<sup>[12]</sup> have been effective.

In our case clinical as well as histopathological findings correlate with the diagnosis of the linear porokeratosis. Due to the rarity of the linear type of porokeratosis and its remarkable response with isotretinoin, we are reporting this case.

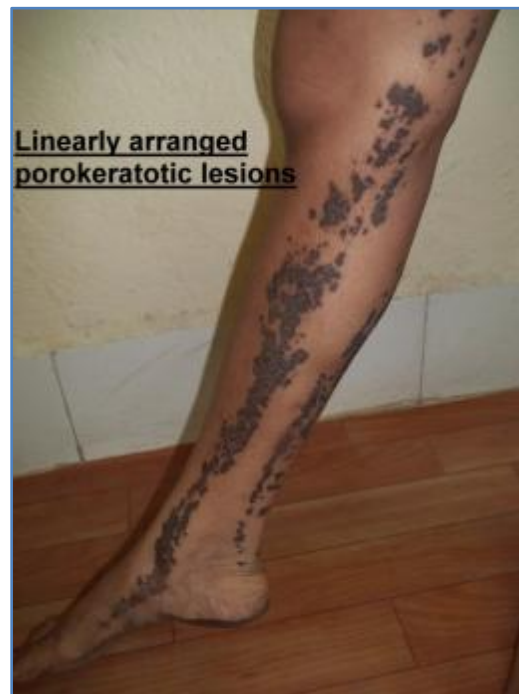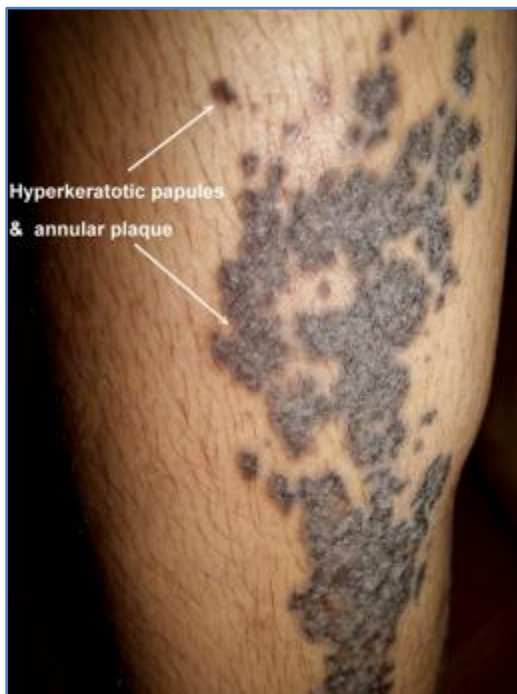### REFERENCES:

1. Reed RJ, Leone P. Porokeratosis - mutant clonal keratosis of the epidermis. Arch Dermatol 1970; 101: 340-7.
2. Lever WF, Lever SG. Histopathology of the Skin, 7th Ed. JB Lippincott co, Philadelphia 1990; 70-72.
3. Zhang ZH, Huang W, Niu ZM et al. Two closely linked variations in actin cytoskeleton pathway in a Chinese pedigree with disseminated superficial actinic porokeratosis. J Am Acad Dermatol 2005; 52: 972-6.
4. Otsuka F, Shima A, Ishibashi Y. Porokeratosis has neoplastic clones in the epidermis. Microfluorometric analysis of DNA content of epidermal cell nuclei. J Invest Dermatol 1989; 92: 231S-3S.

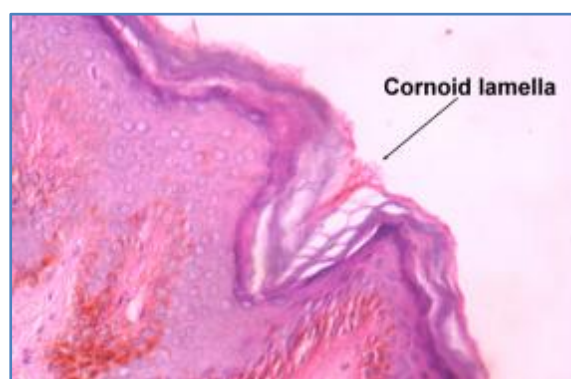
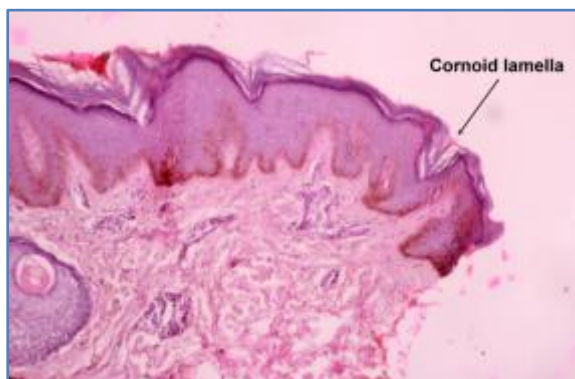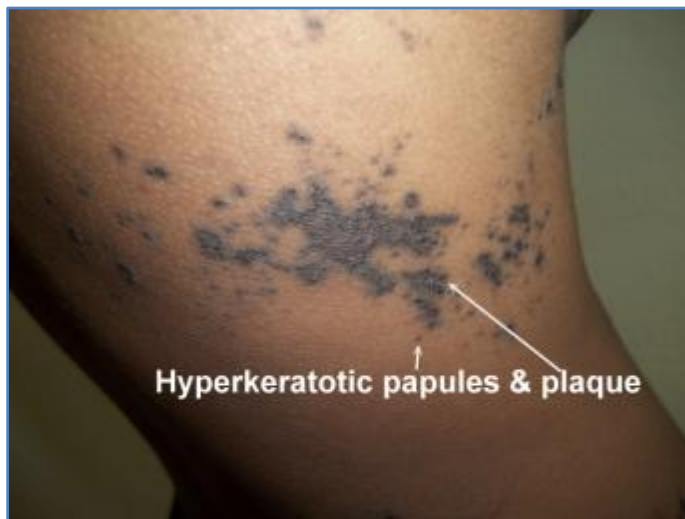
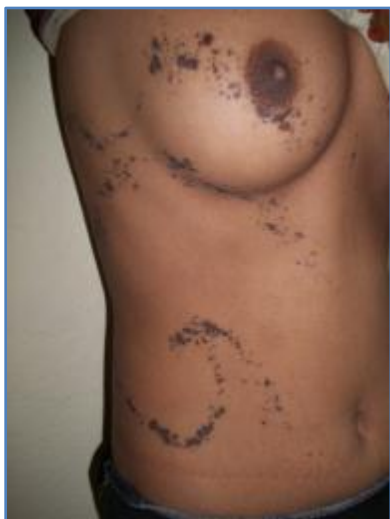## CASE REPORT

---

5. Otsuka F, Nashiro K, Kobayashi K, Ishibashi Y. Chromosome abnormalities of porokeratosis-cultured epidermal keratinocytes: comparison with those of cultured dermal fibroblasts. *Cancer Genet Cytogen* 1991; 56: 163-9.
6. Spencer LV. Porokeratosis. Medscape Reference. May 30, 2012.
7. Ginarte M, Leon A, Toribio J. Disseminated superficial porokeratosis with amyloid deposits. *Eur J Dermatol* 2005; 15: 298-300.
8. Lozinski AZ, Fisher BK, Walter JB et al. Metastatic squamous cell carcinoma in linear porokeratosis of Mibelli. *J Am Acad Dermatol* 1987; 16: 448-51.
9. Barnett JH. Linear porokeratosis: treatment with the carbon dioxide laser. *J Am Acad Dermatol* 1986; 14: 902-4.
10. Bohm M, Luger TA, Bonsmann G. Disseminated superficial actinic porokeratosis: treatment with topical tacalcitol. *J Am Acad Dermatol* 1999; 40: 479-80.
11. Agarwal S, Berth-Jones J. Porokeratosis of Mibelli: successful treatment with 5% imiquimod cream. *Br J Dermatol* 2002; 146: 338-9.
12. Danno K, Yamamoto M, Yokoo T. Etretnate treatment in disseminated porokeratosis. *J Dermatol* 1988; 15: 440-4.



## CASE REPORT



### AUTHORS:

1. Krishnendra Varma
2. Harsh Sharma

### PARTICULARS OF CONTRIBUTORS:

1. Professor and HOD, Department of Dermatology, R. D. Gardi Medical College, Ujjain, M. P.
2. Post Graduate, Department of Dermatology, R. D. Gardi Medical College, Ujjain, M. P.

### NAME ADDRESS EMAIL ID OF THE CORRESPONDING AUTHOR:

Dr. Krishnendra Varma,  
Bhratru Sneha-Bung,  
No. 114/5, Old Tempo Stand,  
Moosa Khedi Main Road,  
Indore-4520001, M. P.  
Email: krishnendra\_varmal17@yahoo.co.in

Date of Submission: 20/08/2014.  
Date of Peer Review: 21/08/2014.  
Date of Acceptance: 30/08/2014.  
Date of Publishing: 04/09/2014.