

**CHRONIC BACTERIAL SINUSITIS- A CLINICAL PROFILE**

M. Gowri Shankar<sup>1</sup>, P. V. Haridas<sup>2</sup>, B. Harish<sup>3</sup>, Anitha Mahadevan<sup>4</sup>

<sup>1</sup>Associate Professor, Department of ENT, Chengalpattu Medical College and Hospital.

<sup>2</sup>Associate Professor, Department of ENT, Chengalpattu Medical College and Hospital.

<sup>3</sup>Resident, Department of ENT, Chengalpattu Medical College and Hospital.

<sup>4</sup>ENT Surgeon, Sivan ENT Care, Chennai.

**ABSTRACT****BACKGROUND**

Sinusitis is a leading health care problem believed to be increasing in both incidence and prevalence. Various articles have been published on sinusitis and its treatment. However, its importance is diminished by the fact that sinusitis is variously defined.

The main objective of this study is to define the clinical signs and symptoms of chronic bacterial sinusitis and to grade the severity of presentation of each clinical feature correlating with radiological and endoscopic and microbiological features.

**MATERIALS AND METHODS**

This prospective study was conducted in a tertiary health care centre over a three-month period; 80 patients were chosen, 40 with nasal symptoms as their main complaint with or without headache as experimental group and 40 patients with headache as their main complaint without nasal symptoms as the control group. They were subjected to detailed clinical examination, radiological, endoscopic and microbiological examinations.

**RESULTS**

Nasal obstruction, discharge and headache form the major symptoms while hyperaemia, deviated septum with hypertrophied inferior turbinates form the major signs in the case group. Diagnostic nasal endoscopy correlated well with clinical findings, while x-ray of the sinuses was found to be abnormal in all cases.

**CONCLUSION**

A proper and detailed clinical evaluation with x-ray of the paranasal sinuses and endoscopy should form the mainstay in diagnosing chronic bacterial sinusitis. CT scan should be added if we are planning for surgery and for cases not responding to initial medical management due to radiological risk and cause factor.

**KEYWORDS**

Chronic Bacterial Sinusitis, Nasal Endoscopy, X-ray PNS.

**HOW TO CITE THIS ARTICLE:** Shankar MG, Haridas PV, Harish B, et al. Chronic bacterial sinusitis- A clinical profile. J. Evolution Med. Dent. Sci. 2017;6(20):1595-1599, DOI: 10.14260/jemds/2017/350

**BACKGROUND**

Sinusitis is a leading health care problem believed to be increasing in both incidence and prevalence.<sup>1</sup> Various articles have been published on sinusitis and its treatment. However, its importance is diminished by the fact that sinusitis is variously defined. Hence, the American Academy of Otolaryngology- Head and Neck surgery have formulated certain working definitions. Broadly speaking sinusitis may be clinically defined as the condition manifested by an inflammatory response involving the mucosa of nasal cavity and sinuses, fluids within this cavities and/or underlying bone. The patient history and routine physical examinations are insufficient for the proper diagnosis. About 90 percent of visits are to the primary care physicians. Majority of these physicians don't have adequate knowledge on radiology and endoscopy. Patients with symptoms refractory to empiric treatment and patients with evidence of impending

complications should be referred to a specialist for further evaluation namely radiology and endoscopy. As rhinosinusitis is an illness with significant impact on quality of life it must be diagnosed and treated early with the help of structured physical examinations and detailed patient history on the details of which proper medical treatment can be given.

**MATERIALS AND METHODS**

Outpatients of ENT Department of tertiary health care centre.

**Study Design**

This is a prospective study.

**Study Place**

ENT Department of Tertiary Health Care Centre, Chengalpattu, India.

**Study Period**

November 2016 to January 2017.

**Inclusion Criteria**

All patients above 10 years of age of both genders with complaints suggestive of sinusitis for a period of more than 3 months.

**Exclusion Criteria**

*Financial or Other, Competing Interest: None.*

*Submission 31-01-2017, Peer Review 24-02-2017,*

*Acceptance 02-03-2017, Published 09-03-2017.*

*Corresponding Author:*

*Dr. M. Gowri Shankar,*

*#594, Alagirisamy Road,*

*K. K. Nagar, Chennai-600078.*

*E-mail: gowrishankarmurari@rediffmail.com*

*DOI: 10.14260/jemds/2017/350*



Patients with acute sinusitis, gross nasal mass obstructing the nasal cavity, patients with allergy, patients on antibiotic and antihistaminics within 2 weeks period of examination, postoperative patients, patients on immune suppressive therapy, patient unwilling for the study.

### Study Parameters

#### Methodology

A detailed proforma with major and minor factors of chronic sinusitis graded according to the severity was used. After evaluations, clinical examination was performed in a detailed way. They were then subjected to radiological examination, i.e., plain X-ray of the PNS-Water's view. Some patients who were planned for surgery were subjected to CT scan of the PNS. The radiologically positive patients were selected for the study and subjected to endoscopic examination of the nose and paranasal sinuses under local anaesthesia with topical 4% Xylocaine. The diagnostic nasal endoscopy was done with rigid nasal endoscope of 4 mm diameter and 0° and 30° angulations. The findings were recorded and sent for microbiological examination. After explaining and getting the consent, the patients were subjected to endoscope guided middle meatal nasal swab which was done under local anaesthesia with 4% Xylocaine. The sensitivity of the organisms to common conventional antibiotics were done.

### DISCUSSION

Chronic sinusitis is a common problem encountered by otolaryngologists worldwide. It affects a significant percentage of the population and causes long term morbidity. It may be defined as persistent inflammation and suppuration of the paranasal sinuses for more than 3 months (Johnson 1992). Inflammation of the sinonasal mucosa leads to obstruction of the ostiomeatal complex (Stammler 1986) coupled with gravity and decreased mucociliary clearance, and inspissation of secretions occurs in the sinuses forming a culture medium for bacterial growth.

Over the past decades, endoscopic evaluation and sinonasal imaging techniques particularly CT scanning have revolutionised the diagnosis and treatment.

The demographic profile shows a mean age group of 35.6 for cases and 34.4 for controls. Of the 40 cases, 60% were males and 40% were females while in the 40 controls, 52.4% were males and 47.6% were females. Regarding occupation, the major group for both cases and controls were housewives with 32.5% and 40.5% respectively. The second largest group for cases was skilled labourers (22.5%) and that for controls was clerical persons (31%).

Nasal congestion with obstruction and production of thickened nasal secretions were the commonest clinical symptoms.<sup>2,3,4</sup> Facial pain and pressure are lesser features.<sup>3</sup> Most of them report a significant change in airflow.<sup>3</sup> Typical periodicity is a feature of frontal sinusitis<sup>4</sup> while swelling on the medial aspect of the orbit is a feature of acute ethmoidal sinusitis<sup>3</sup>. Thus, the acute forms of sinusitis present with straightforward clinical features. Chronic sphenoidal sinusitis rarely exist alone. Occipital headache, disabling heaviness of head are present commonly. The author of the International Headache Society Manual for Headache diagnosis<sup>6</sup> says that chronic nasal conditions are not validated as causes of headache unless relapsing into an acute phase. Migraine and tension headaches are often confused with sinus headache.<sup>5</sup>

Not more than 10% of all headaches are caused by verifiable sinus diseases.<sup>6</sup>

Transillumination of sinuses is not extremely helpful as it may be localised in recesses of the maxillary and frontal sinuses that cannot be adequately transilluminated.

The common causes for nasal obstruction are septal deviations and turbinate hypertrophy. Increase in nasal resistance resulting from mucosal congestion or airway deformity are the main factors in producing the complaint of nasal obstruction.<sup>7</sup>

Considering clinical features, most of the patients with chronic sinusitis had bilateral (70%), intermittent (87.5%) and partial (82.5%) nasal block. However, 3 out of 40 patients did not have nasal obstruction. Most of the patients had bilateral (72.5%), intermittent (85%), mucopurulent (77.5%) nasal discharge. Here again 6 patients had nasal block without any discharge. Loss of smell was not a major feature. Headache was present in 65% of cases and of which 35% were mild, 30% were moderate. 35% did not have any headache. The headache was vague, not well localised with almost every 1 of the 65% of cases complaining of frontal and bitemporal headache. They lacked any periodicity and were unassociated with vomiting. In the control group, 95.2% were mild headache and 4.8% were moderate.

Cough was present in 37.5% of cases and 4.5% of controls. Septal deviation was present in 60% of cases and 57.1% of controls. Of them, right-sided deviation was commoner than left sided. Hyperaemia was present in 80% of cases and 9.5% controls. Oedema of the nasal mucosa was noted in 42.5% cases alone. Pus in the middle meatus was found in 20% of cases. 75% of cases had normal looking middle turbinate and inferior turbinate was normal in 50% of cases. A tenderness over the sinuses was not a significant feature in the study with only 22.5% having mild tenderness.

In our study, we found that nasal obstruction was the commonest clinical symptom while nasal discharge is also common. This correlates well with American Academy of Otolaryngologist- Head and Neck Society Task Force which includes these two as major factors. Olfactory disturbance was not a major feature. Downey LL et al<sup>8</sup> says that chronic sinusitis often causes anosmia. The low incidence of anosmia in our study may be due to partial nasal block. Our study correlates well with International Society Manual that headache is not a major feature in chronic sinusitis. Fever, dental pain and earache which were included as minor factors by AAO-HNS, too had a small percentage of incidence in our study also.

Clinical examination of sinuses is limited as they cannot be examined directly.<sup>9</sup> It is characterised by polypoid and thickened mucosa.<sup>4</sup> Mucopurulent discharge may be seen around the middle meatus.<sup>10</sup> Erythema and oedema of the mucosa over the sinuses are rarely present in chronic disease.<sup>10</sup> Rhinorrhoea may or may not be present.<sup>11</sup> No one has ever investigated whether pressure over sinuses is of any real value. It seems logical that pressure over an infected sinus would produce pain. Unfortunately, it also offers pressure on the infraorbital and supraorbital nerve and makes the patient difficult to differentiate the pain caused by compression of a nerve from that of sinusitis.

Regarding nasal endoscopy, 32.5% had right-sided septal deviation, 30% had left sided and 12.5% had bilateral deviation. It was normal in 25% of cases. The middle

turbinate was abnormal in 60% of cases while inferior turbinate was abnormal in 62.5% of cases. The middle meatus was abnormal in 62.5% of cases with the common abnormalities being congestion, bent, uncinated and enlarged bulla ethmoidalis and presence of hyperaemia, crust and pus.

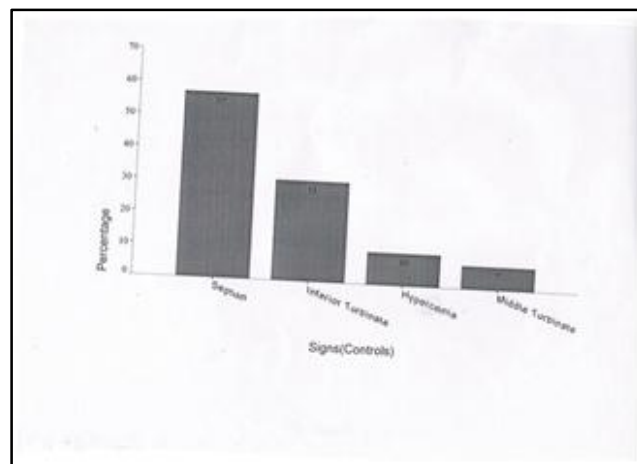
Nasal endoscopy has become an important component of diagnostic armamentarium.<sup>12</sup> Certain studies have stated that symptomatic and asymptomatic people can have septal deviation. Paradoxical middle turbinate is not a pathological condition but may cause narrowing of the ostiomeatal complex.<sup>12</sup> Uncinate process may be markedly thinned in chronic inflammatory diseases.<sup>12</sup> Markedly bulging agger nasi region is found in chronic sinusitis. Thus, in our study, middle meatal abnormalities are encountered in 80% of cases. Bertrand et al in their study concluded that sinus endoscopy has been key to the management of chronic pathology giving precise information.

Plain X-ray of the sinuses showed 72.5% of bilateral disease with involvement of maxillary and ethmoidal sinuses. 16.7% of controls who had only headache without nasal symptoms had incidental mild haziness of maxillary sinuses on one side.

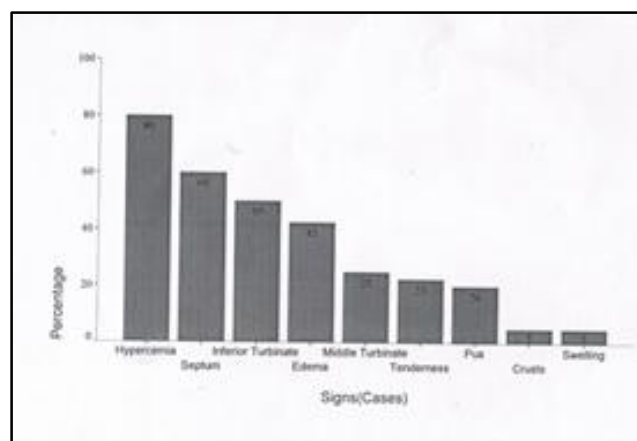
Havas et al in one study concluded that paranasal sinus abnormalities on CT scan are common in asymptomatic patients also. He stressed the importance of careful clinical correlation with radiological appearances. However, Schopfner found that opacification of sinus was an infrequent finding in asymptomatic people. Such people need further investigation. White PS et al say that high frequency of CT abnormality in normal subjects (Havas et al 1988, Bolgar et al 1991) and the significant radiation dose (MacLennan 1995) makes the use of CT as a diagnostic investigation inappropriate. It should be used prior to surgery.<sup>13</sup> Jones NS et al concluded that bony anatomical variation does not influence the prevalence of sinusitis but it is an intrinsic mucosal disease that is probably more important. Jorishen M finally says that endoscopy and CT are not concurrential but complementary.<sup>14</sup> In our study, we used X-rays as the main radiological tool than CT scan. We graded the X-ray finding as per Gliklich and Metson's Harvard system of staging.

Bacterial examination showed growth in 42.5% of cases of which 10% was alpha Streptococcus, 7.5% were coagulase-negative Staphylococcus and H. influenza and 5% Gram-negative bacilli, 2.5% Klebsiella, Citrobacter, Pseudomonas, Pneumococcus and Staphylococcus. 2.5% showed normal flora. In the control group, bacteria were not grown in 21.4%. However, 33.3% showed Staphylococcus aureus, 23.8% normal flora, 11.9% coagulase-negative Staphylococcus, 4.8% Gram-negative bacillus and 2.4% diphtheroids.

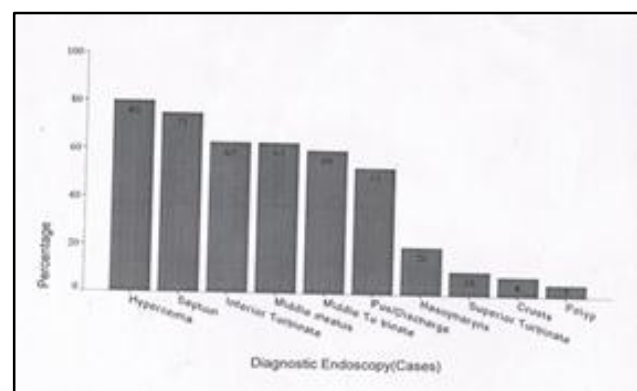
The bacteriology of chronic sinusitis is now well documented although the interpretation of results is controversial.<sup>15</sup> Of various methods of obtaining sample, endoscopic aspiration is useful.<sup>16</sup> Gold SM et al demonstrated a strong correlation between middle meatal and maxillary sinus cultures.<sup>17</sup> Hence, in our study, we collected all the samples from middle meatus. Our study correlates well with the previous studies regarding the pathogens encountered.<sup>18,19,20,21,</sup>



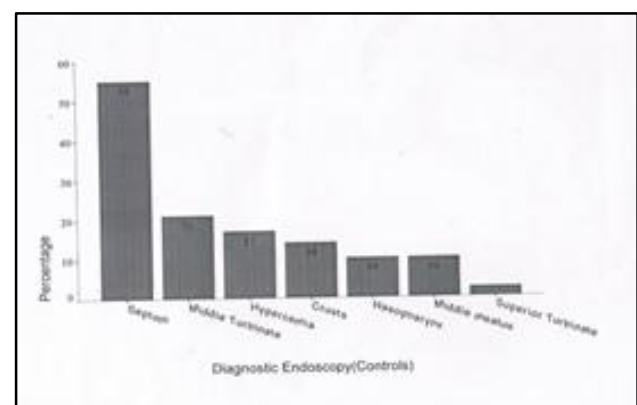
Graph 1



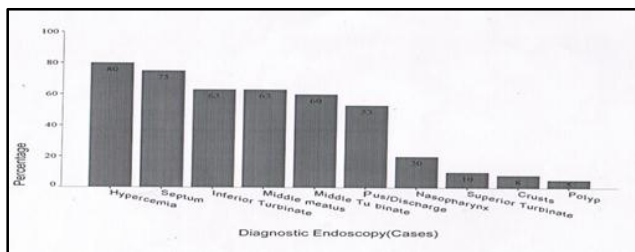
Graph 2



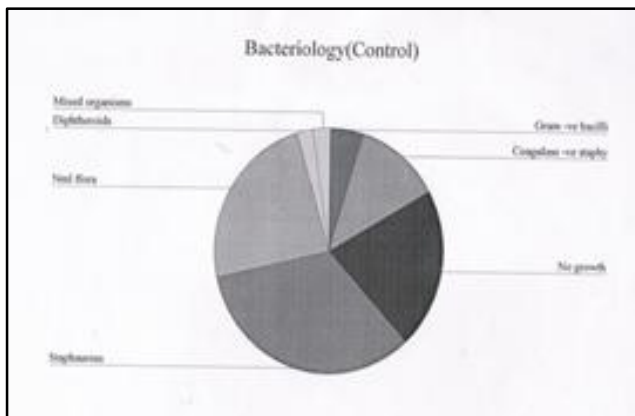
Graph 3



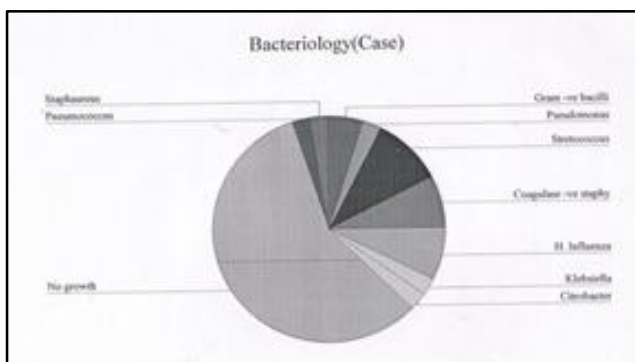
Graph 4



Graph 5



Graph 6



Graph 7

**CONCLUSION**

The present study was undertaken keeping in mind the difficulties encountered in diagnosing and managing chronic bacterial sinusitis.

Nasal obstruction, discharge and headache form the major symptoms while hyperaemia, deviated septum with hypertrophied inferior turbinates form the major signs in the case group.

Diagnostic nasal endoscopy correlated well with clinical findings while X-ray of the sinuses was found to be abnormal in all cases. Microbiological evaluation, though not significant regarding the pathogens identified, it still plays a role in proper management of patients suffering from chronic bacterial sinusitis.

Thus, a proper and detailed clinical evaluation with X-ray of the paranasal sinuses and endoscopy should form the mainstay in diagnosing chronic bacterial sinusitis. CT scan should be added if we are planning for surgery and for cases not responding to initial medical management due to radiological risk and cause factor.

**REFERENCES**

[1] Pang YT, Willatt DJ. Do antral washouts have a place in the current management of sinusitis? The Journal of Laryngology and Otology 1996;110(10):926-8.

[2] Chester AC. Chronic sinusitis. American Family Physician 1996;53(3):877-87.

[3] Hadley JA, Schaefer SD. Clinical evaluation of rhinosinusitis: history and physical examination. Otolaryngology-Head and Neck surgery 1997;117(3):S8-S11.

[4] Colman BH. Hall and Colman's diseases of nose, throat and ear, and head and neck. 14<sup>th</sup> edn. Churchill Livingstone 1992:11-73.

[5] Finkel AG, Mann JD, Lundeen TF. Headache and facial pain. In: Bailey BJ. Head and neck surgery otolaryngology. 2<sup>nd</sup> edn. Philadelphia: Lippincott Raven 1998:287-304.

[6] Ballenger JJ. Headache and neuralgia of the face. In: Ballenger JJ, Snow JB (eds). Otorhinolaryngology head and neck surgery. 15<sup>th</sup> edn. Baltimore: Williams & Wilkins 1996:158-64.

[7] Ballenger JJ. Chronic rhinitis and nasal obstruction. In: Ballenger JJ. Otorhinolaryngology head and neck surgery. 15<sup>th</sup> edn. Baltimore: Williams & Wilkins 1996:129-34.

[8] Downey LL, Jacobs JB, Lebowitz RA. Anosmia and chronic sinus disease. Otolaryngology Head and Neck surgery 1996;115(1):24-8.

[9] Havas TE, Motbey JA, Gullane PJ, et al. Prevalence of incidental abnormalities on computed tomographic scans of the paranasal sinuses. Head and Neck surgery 1998;114(8):856-9.

[10] Rosenfeld RM. Sinusitis in children. 6<sup>th</sup> edn. Current therapy in otolaryngology and head and neck surgery. Gates GA 1998:p 354.

[11] Stammberger H. Functional endoscopic sinus surgery. In: Hawke M. Chapter 4 and 5. The Messerklinger technique. Decker 1991:89-267.

[12] White PS, MacLennan AC, Connolly AAP, et al. Analysis of CT scanning referrals for chronic rhinosinusitis. The Journal of Laryngology and Otology 1996;110(7):641-3.

[13] Jorissen M. Recent trends in the diagnosis and treatment of sinusitis. European radiology 1996;6(2):170-6.

[14] Klossek JM, Dubreuil L, Rich H, et al. Bacteriology of chronic purulent secretions in chronic rhinosinusitis. Journal of Laryngology and Otology 1998;112(12):1162-6.

[15] Brook I, Frazier EH, Foote PA, et al. Microbiology of chronic maxillary sinusitis: comparison between specimens obtained by sinus endoscopy and by surgical drainage. Journal of Medical Microbiology 1997;45(5):430-2.

[16] Gold SM, Tami TA. Role of middle meatus aspiration culture in the diagnosis of chronic sinusitis. The laryngoscope 1997;107(12 Pt 1):1586-9.

[17] Batra PS, Han JK. Practical medical and surgical management of chronic rhinosinusitis. Springer 2015:19-26.

- [18] Chang CC, Incaudo GA, Gershwin ME. Diseases of the sinuses: a comprehensive textbook of diagnosis and treatment. Springer 2014:89-96.
- [19] Berry M, Suri S, Chowdhury V. Diagnostic radiology: neuroradiology: head and neck imaging. 2<sup>nd</sup> edn. Jaypee Brothers 2006:458-87.
- [20] Som PM, Curtin HD. Head and neck imaging. 5<sup>th</sup> edn. Elsevier 2011:176-91.
- [21] Rosenfeld RM, Andes D, Bhattacharya N, et al. Clinical practice guidelines: adult sinusitis. Otolaryngology Head and Neck surgery 2007;137(3 Suppl):S1-31.