

CASE REPORT

A LARGE HISTOCYTOSIS X OF THE RADIUS: AN UNUSUAL CASE

Mohammed Ibrahim¹, Sachin Shah², Meghanath Pawar³, Kausar Nazneen⁴

HOW TO CITE THIS ARTICLE:

Mohammed Ibrahim, Sachin Shah, Meghanath Pawar, Kausar Nazneen. "A Large Histiocytosis X of the Radius: An Unusual Case". Journal of Evolution of Medical and Dental Sciences 2014; Vol. 3, Issue 20, May19; Page: 5618-5621, DOI: 10.14260/jemds/2014/2637

ABSTRACT: A case of a 9-month-old patient with a lesion in the diaphyseal of the left radius is presented. The clinico-radiological suspicion was either infection or tumor of the diaphysis of radius. Subsequently, a biopsy proved the lesion to be a histiocytosis x of bone.

KEYWORDS: Histiocytosis X; tumor; osteomyelitis.

INTRODUCTION: The term histiocytosis X incorporates the multiple organ involvement in disseminated Hand Schuller Christian disease and Letterer-Siwe disease. Neither the clinical nor the radiographic presentation of histiocytosis X is specific, and the diagnosis poses a dilemma to the orthopedic surgeon.^{1,2}The commonest differential diagnosis made in a younger patient with a short history of severe bone pain and bony tenderness in the diaphysis of a long bone is either infection or tumor. Newer investigation modalities like CT and MRI help in evaluating the extent of the lesion but the diagnosis can only be confirmed by histopathology.

CASE REPORT: A 9 Month-old patient presented to the outpatient department with a history of pain over the left forearm for the past 6 weeks. There was no history of trauma or any associated constitutional symptoms. The child had not taken any treatment except occasional analgesics. On examination, he was afebrile, with marked local tenderness over almost whole length of left radius. There was no enlargement of regional lymph nodes.

The local temperature was not raised and there was local swelling. Plain radiographs of the left forearm diffuse lytic lesion almost involving whole shaft of left radius with periosteal reaction in the radius (fig. 1). Subsequently a CT-scan performed to delineate the lesion further showed destruction of the cortex of the diaphyseal region of the left radius with periosteal reaction (fig. 2). A provisional diagnosis of a subacute osteomyelitis or Ewing's sarcoma was made. A MRI done for evaluation of soft tissue involvement showed some soft tissue edema and breach in cortex (fig. 3). The patient was taken up for a J needle biopsy under C arm guidance. Intraoperatively there was no pus and tissues were sent for frozen histopathology reporting but it was inconclusive.

Than tissues send for detail reporting, Grayish tissue resembling granulation tissue was removed from the lesion and sent for Gram staining, culture, PCR test for Mycobacterium Tuberculosis and histopathology. Gram staining, bacterial culture and PCR were found to be negative. Histologically, a low-power view showed numerous eosinophils, lymphocytes and Langerhans cell histiocytes. A high-power microphotograph (fig. 4) showed Langerhans cells with grooved nuclei, mixed with eosinophils, suggestive of eosinophilic granuloma (EG).

There were no signs of infection or granulomas. Immunohistochemical stains S100 (fig. 5) were performed, confirming the diagnosis.

CASE REPORT

To look for other lesions, a skeletal survey was done, an ultrasonography of the abdomen performed. These investigations did not reveal any other focus and the diagnosis of an isolated EG of the radius was made and the patient was kept under observation.

DISCUSSION: Solitary EG of bone is the commonest manifestation of histiocytosis (60-80%).¹ The hallmark of histiocytosis X is the Langerhans cell, a histiocyte with characteristic racquet shaped Birbeck granules visible on electron microscopy. The pathogenesis of EG is not completely understood.

Infections, immune and neoplastic causes have been postulated.¹ Up to 80% of histiocytosis X lesions in children are of solitary EG type and up to 90% occur in children.¹

The usual sites of bony involvement include the skull (34%), spine (15%), ribs (7%) and long bones (15%), although any bone may be affected.² In the long bones, the diaphysis is most commonly affected (58%), followed by the metaphysis.² The presenting symptoms of the disease are variable and non-specific.

The patient may complain of pain, localized swelling of region involved and sometimes a pathological fracture. At other times, EG is discovered incidentally while screening for other medical problems or in traumatic conditions (e.g. head injury). The physical examination of the child may be essentially normal. Laboratory findings are usually non-specific except for a moderate and inconsistent rise in ESR.

In the acute phase, lesions appear rapidly, perhaps in a few weeks, and are aggressive looking with poorly defined margins.¹ Although MRI is very sensitive, the findings remain non-specific.¹ CT or MRI is useful in evaluating soft tissue involvement in EG.² The radiological diagnosis is difficult to differentiate from infection or Ewing's sarcoma.³

Irradiation is rarely used because of reports of late latent neoplasms. Irradiation is rarely used because of reports of late latent neoplasms.⁴ This may either regress to a well-defined lesion with sclerotic scalloping, cortical erosion, periosteal reaction (single or laminated 'onion peel' appearance) and soft tissue involvement.³ Solitary EG of bone has been shown to undergo spontaneous remission.⁵ The characteristic radiographic finding described for EG involvement of long bones is a lytic medullary based lesion.⁶ If a pathological fracture occurs, the radiographic findings become even more confusing.

A child suspected of having EG should be carefully investigated for the presence of other stigmata of histiocytosis. Most investigators recognize the poor reliability of bone scintigraphy.^{6,7}

Parker et al reported that only 35% of lesions are visible on a bone scan.⁶ MRI is very well suited for demonstrating bone marrow involvement and accompanying soft tissue mass or inflammation in EG of bone.

Biopsy remains the key to diagnosis³ in EG. Further confirmation is possible using immunohistochemical staining such as S100, cluster of differentiation 1 (CD-1), or monoclonal antibody OKT6 and electron microscopy.⁷

The treatment of EG is equally controversial with different therapeutic approaches claiming effectiveness. Symptomatic surgically accessible solitary EG are managed by biopsy, curettage and bone grafting if needed.⁷ Local injection of corticosteroids was described by Scaglietti et al, with immediate pain relief and healing response within 2 months after injection.⁸

CASE REPORT

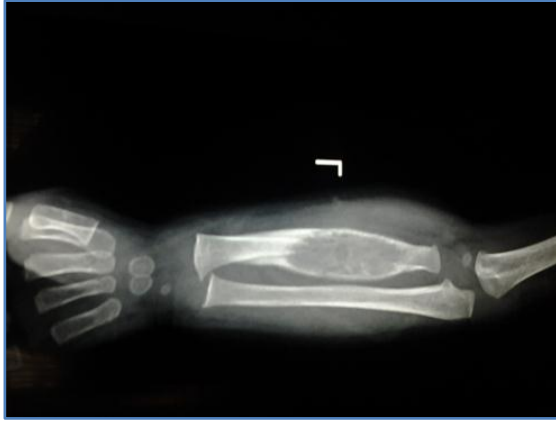


Fig. 1: Plain radiograph of the left forearm revealing a lytic lesion with periosteal reaction in the radius

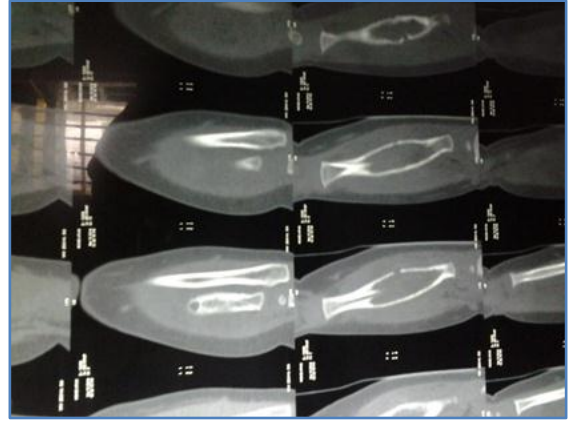


Fig. 2: CT scan of the forearm revealed destruction of the cortex of the diaphyseal region of the radius with an associated periosteal reaction

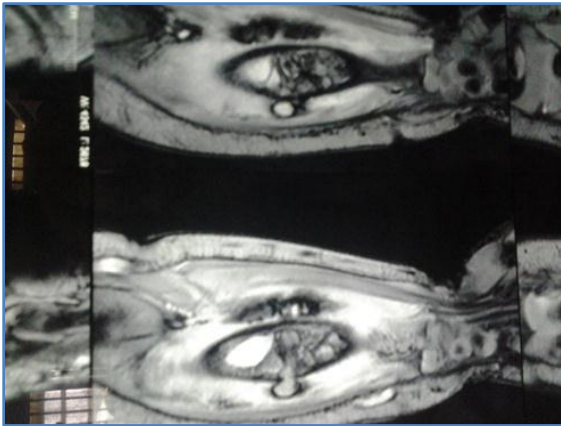


Fig. 3: A MRI showed normal soft tissues with oedema and cystic lesion

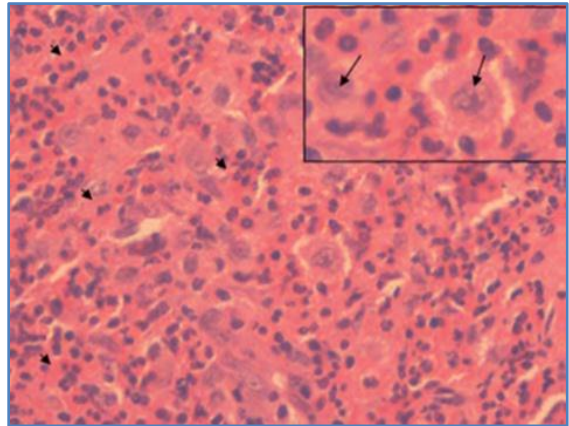


Fig. 4: Photomicrograph (haematoxylin and eosin)

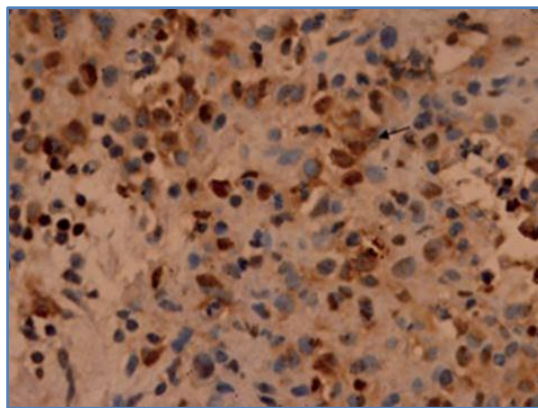


Fig. 5: Nuclear positivity of S100 protein in Langerhans' cells (arrow)

CASE REPORT

The use of chemotherapy and oral corticosteroids alone or combined is indicated in systemic disease but rarely in a solitary lesion due to unpredictable results obtain⁹. Other favourable prognostic factors are age greater than 2 years, absence of pulmonary, hepatic, haemopoietic lesions or multiple bony involvement.²

CONCLUSION: Here we present you a rare case of histiocytosis. We conclude with a single message. Suspect it, lest you will miss it.

REFERENCES:

1. Azouz EM, Saigal G, Rodriguez MM, Podda A. Langerhans' cell histiocytosis: pathology, imaging and treatment of skeletal involvement. *Pediatr Radiol* 2005; 35: 103-115.
2. Bollini G, Joure JL, Gentet JC, Jacquemier M et al. Bone lesions in histiocytosis X. *J Pediatr Orthop* 1991; 11: 469-477.
3. McCullough CJ. Eosinophilic granuloma of bone. *Acta Orthop Scand* 1980; 51: 389-398.
4. Egeler RM, Neglia JP, Puccetti DM, Brennan CA et al. Association of Langerhans cell histiocytosis with malignant neoplasm. *Cancer* 1993; 71: 865-873.
5. Muscolo DL, Scullitel G, Ranalletta M et al. Spontaneous remission of massive solitary eosinophilic granuloma of the femur. *J Pediatr Orthop* 2003; 23: 763-765.
6. Parker BR, Pinckney L, Etcubanas E. Relative efficacy of radiographic and radionuclide bone surveys in the detection of skeletal lesions of histiocytosis X. *Radiology*, 1980; 134: 377-380.
7. Sessa S, Sommelet D, Lascombes P et al. Treatment of Langerhans - cell histiocytosis in children. *J Bone Joint Surg* 1994; 76-A: 1513-1525.
8. Scaglietti O, Marchetti PG, Bartolozzi P. Final results obtained in the treatment of bone cysts with methylprednisolone acetate (Depo-Medrol) and a discussion of results achieved in other bone lesions. *Clin Orthop* 1982; 165:33-42.
9. De Camargo OP, De Oliveira NR, Andrade JS et al. Eosinophilic granuloma of the ischium: Long-term evaluation of a patient treated with steroids. *J Bone Joint Surg* 1992; 74-A: 445-447.

AUTHORS:

1. Mohammed Ibrahim
2. Sachin Shah
3. Meghanath Pawar
4. Kausar Nazneen

PARTICULARS OF CONTRIBUTORS:

1. Assistant Professor, Department of Orthopaedics, ESIC Medical College, Gulbarga.
2. Professor and HOD, Department of Orthopaedics, ESIC Medical College, Gulbarga.
3. Associate Professor, Department of Orthopaedics, ESIC Medical College, Gulbarga.
4. Senior Resident, Department of Orthopaedics, ESIC Medical College, Gulbarga.

NAME ADDRESS EMAIL ID OF THE CORRESPONDING AUTHOR:

Dr. Mohammed Ibrahim,
H. No. 7-1202/56D,
Near Al Farooq Masjid,
Islamabad Colony,
Gulbarga.
Email: dribrahimparvez@gmail.com

Date of Submission: 23/04/2014.

Date of Peer Review: 24/04/2014.

Date of Acceptance: 08/05/2014.

Date of Publishing: 19/05/2014.