

## CASE REPORT

---

### CUTANEOUS TUBERCULOSIS: A DIFFERENTIAL FOR CHRONIC NON-HEALING ULCER

Chandrashekar<sup>1</sup>, Anikethana G. V<sup>2</sup>, Kalinga B. E<sup>3</sup>, Ishwar S. Hasabi<sup>4</sup>

#### HOW TO CITE THIS ARTICLE:

Chandrashekar, Anikethana G. V, Kalinga B. E, Ishwar S. Hasabi. "Cutaneous Tuberculosis: A Differential for Chronic Non- Healing Ulcer". Journal of Evolution of Medical and Dental Sciences 2014; Vol. 3, Issue 53, October 16; Page: 12366-12370, DOI: 10.14260/jemds/2014/3634

**ABSTRACT:** Cutaneous tuberculosis is a rare manifestation of tuberculosis and accounts to less than 2% of cases of tuberculosis. It can have varied manifestation. An accurate diagnosis can be achieved by clinical examination of lesion and relevant investigation including skin biopsy. The cutaneous tuberculosis responds excellently to anti-tubercular drugs. Here we describe a case of young adult female, with chronic non-healing leg ulcer. A diagnosis of cutaneous tuberculosis was established based on skin biopsy findings and her response to treatment with anti-tubercular drugs.

**KEYWORDS:** Cutaneous tuberculosis, non-healing ulcer, lupus vulgaris.

**INTRODUCTION:** Cutaneous tuberculosis accounts to less than 2% of all cases of tuberculosis. The cutaneous tuberculosis accounts for 0.15-0.26% of the patients attending the skin outpatient department.<sup>1,2</sup> Cutaneous tuberculosis can have varied manifestation depending on the mode of spread of infection, hosts immune status, previous sensitization to the organism and virulence of the organism.<sup>3</sup> Here we describe a case of young adult female presenting with chronic non-healing ulcer over the leg secondary to tuberculosis, which successfully responded to the treatment.

**CASE REPORT:** A 25 year old female presented with history of multiple ulcers over both her leg of 7 month duration. The ulcers were preceded by multiple painless, papules, which progressed to form small ulcers. Multiple such small ulcers coalesced to form a larger ulcer over the shin. These ulcers were non-healing despite of management with antibiotics and regular dressing. She was non-smoker, non-diabetic and non-hypertensive. She had no history of fever or respiratory symptoms or systemic manifestations.

On examination the patient was a well built and nourished. There were multiple ulcers over her both leg, with unhealthy granulation tissue, indurated margin and very scanty serous discharge (Fig 1). All the peripheral pulses were well appreciated and there was no sensory impairment. There was no lymphadenopathy and systemic examination was unremarkable.

Blood investigations showed an ESR of 74 mm/hr with normal total count and differential count. The RBS was 120 mg% and VDRL, HIV, HBsAg and Anti-HCV was negative. Venous and arterial study of the lower limb was unremarkable. A biopsy taken from the margin of the ulcer showed only chronic nonspecific inflammatory response. Patient underwent a repeat biopsy from a papule, which showed granulomatous inflammation with caseous necrosis, features suggestive of cutaneous tuberculosis (Fig 2).

The chest X-ray showed no evidence of current or past tuberculosis. The X-ray of leg showed no features suggestive of osteomyelitis. The Mantoux test showed an induration of 11mm.

The patient was started on anti-tubercular treatment with isoniazid, rifampicin, ethambutol and pyrazinamide for 2 months and isoniazid and rifampicin for 7 months.

## CASE REPORT

---

Beginning at 6 weeks of starting the treatment the ulcers began to regress and by the end of treatment they had completely healed with healthy scar.

**DISCUSSION:** Cutaneous tuberculosis can present with varied manifestation, including ulceration, papules, verrucous plaque, etc. Mycobacterium tuberculosis cause skin infection by direct inoculation into the skin, by haematogenous spread from an internal lesion (lung) or by direct contact with tuberculosis in an underlying deeper structure (lymph node).<sup>3</sup> The cutaneous tuberculosis is classified as below,<sup>3</sup>

- **Exogenous Infection:**
  - Tubercular chancre.
  - Tuberculosis verrucosa cutis.
  
- **Endogenous Infection:**
  - Lupus vulgaris.
  - Scrofuloderma.
  - Acute military tuberculosis.
  - Orofacial tuberculosis.
  - Tuberculousgumma.
  
- **BCG Vaccine Related:**
  - Perforating regional adenitis.
  - Post vaccination lupus vulgaris.
  
- **Tuberculids:**
  - Lichen scrofulosorum.
  - Papulonecrotictuberculid.
  - Erythema induratum.
  - Erythema nodosum.

The most common forms of cutaneous tuberculosis are lupus vulgaris and scrofuloderma.

Tuberculids are less common forms and are due to immunological reaction to haematogenous spread of antigenic components. Face and neck are the most common sites for cutaneous tuberculosis. Multiple sites were involved in 47% of the cases.<sup>4</sup> Active tuberculosis at other sites was seen in 22% of the cases.<sup>4</sup> The patients treated with standard anti-tubercular regimen responded well to treatment and had no recurrence on follow up of 1-3 years.<sup>5,6</sup>

**CONCLUSION:** Cutaneous tuberculosis should be kept as a differential diagnosis for chronic non-healing ulcer, even in the absence of evidence of pulmonary tuberculosis. Appropriate diagnosis may need a repeat skin biopsy. Cutaneous tuberculosis responds excellently to anti-tubercular treatment, hence the need for identifying the condition.

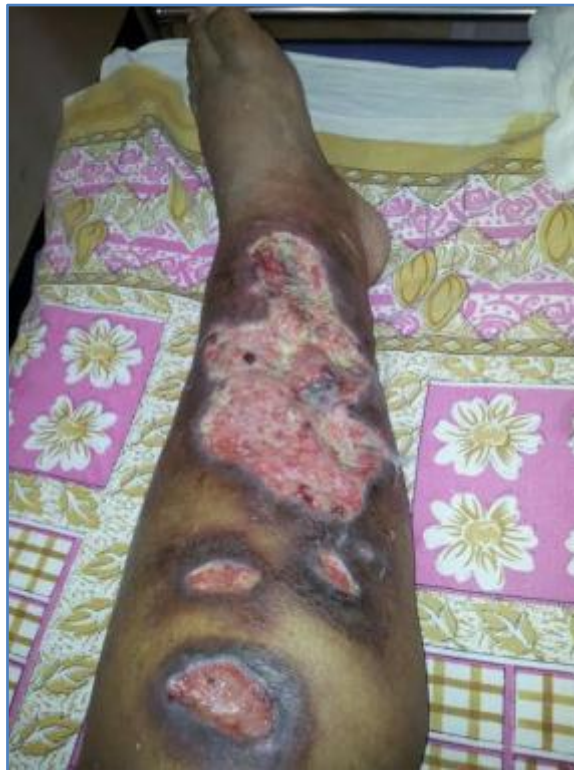## CASE REPORT

---

### REFERENCES:

1. Sehgal VN, Jain MK, Srivastava G. Changing pattern of cutaneous tuberculosis: A prospective study. *Int J Dermatol.* 1989 May; 28: 231-236.
2. Patra AC, Gharami RC, Banerjee PK. A profile of cutaneous tuberculosis. *Indian J Dermatol.* 2006; 51 (2): 105-107.
3. Freedberg, Irwin. *Fitzpatrick's Dermatology in General Medicine*, 6<sup>th</sup>ed, 2003, Freedberg, Mc Graw Hill, USA; 1933-46.
4. Tejinder K, Alpna T, Kritika P, et al. Cutaneous TB profile in North West Punjab, India: A retrospective analysis. *Our Dermatol Online.* 2013; 4 (4): 458-461.
5. Umapathy KC, Begum R, Ravichandran G, Rahman F, Paramasivan CN, Ramnathan VD. Comprehensive findings on clinical, bacteriological, histopathological and therapeutic aspects of cutaneous tuberculosis. *Trop Med Int Health.* 2006 Oct; 11(10): 1521-1528.
6. Dwari BC, Ghosh A, Paudel R, Kishore P. A clinicoepidemiological study of 50 cases of cutaneous tuberculosis in a tertiary care teaching hospital in Pokhara, Nepal. *Indian J Dermatol.* 2010; 55(3): 233-237.

Fig. 1a: Showing large ulcer over the shin of the left leg, with unhealthy granulation tissue, when the patient presented to us.



**Fig. 1a**

## CASE REPORT

---

Fig. 1b: Healing of the skin ulcer by scar formation seen at fourth month of treatment with anti-tubercular drugs and regular dressing.

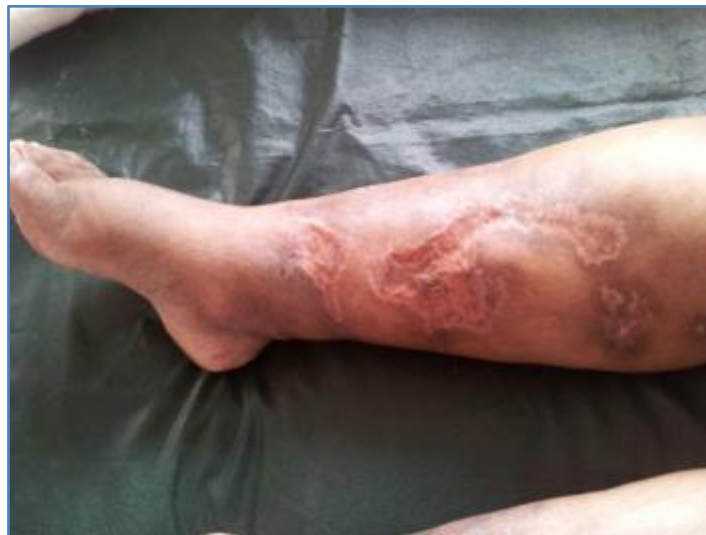

Fig. 1b

Fig. 2: H & E staining of the skin biopsy showing multinucleated giant cells and caseous necrosis surrounded by granuloma (indicated by the arrow).

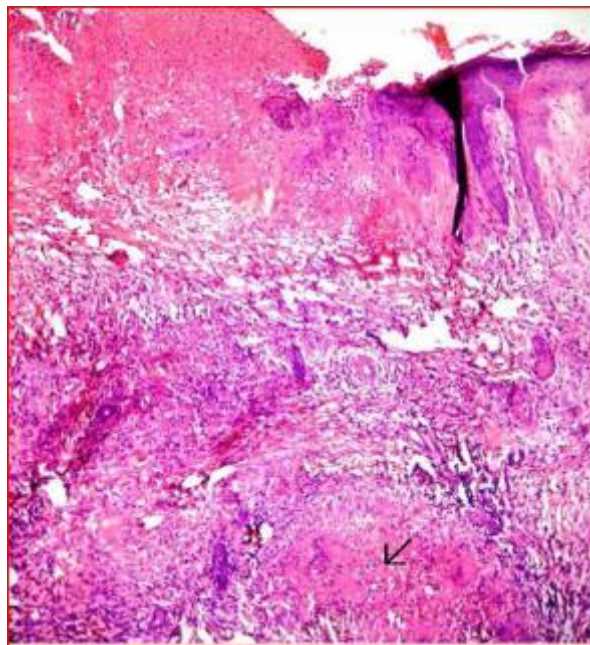


Fig. 2

## CASE REPORT

---

### **AUTHORS:**

1. Chandrashekar
2. Anikethana G. V.
3. Kalinga B. E.
4. Ishwar S. Hasabi.

### **PARTICULARS OF CONTRIBUTORS:**

1. Assistant Professor, Department of Medicine, KIMS, Hubli, Karnataka.
2. Post Graduate Student, Department of Medicine, KIMS, Hubli, Karnataka.
3. Assistant Professor, Department of Medicine, KIMS, Hubli, Karnataka.
4. Professor, Department of Medicine, KIMS, Hubli, Karnataka.

### **NAME ADDRESS EMAIL ID OF THE CORRESPONDING AUTHOR:**

Dr. Chandrashekar,  
Assistant Professor,  
Department of Medicine,  
KIMS, Hubli-580022,  
Karnataka.  
Email: chandru2323@yahoo.co.in

Date of Submission: 28/09/2014.

Date of Peer Review: 29/09/2014.

Date of Acceptance: 10/10/2014.

Date of Publishing: 16/10/2014.