

## GENERAL E.N.T. EVALUATION IN HEAD INJURY CASES WITH SPECIAL REFERENCE TO TEMPORAL BONE INJURY

Vikramjit Singh Parmar<sup>1</sup>, S. V. Golhar<sup>2</sup>, P. Deshmukh<sup>3</sup>, Poonam Pathania<sup>4</sup>

### HOW TO CITE THIS ARTICLE:

Vikramjit Singh Parmar, S. V. Golhar, P. Deshmukh, Poonam Pathania. "General E.N.T. Evaluation in Head Injury Cases with Special Reference to Temporal Bone Injury". Journal of Evolution of Medical and Dental Sciences 2015; Vol. 4, Issue 30, April 13; Page: 5218-5221, DOI: 10.14260/jemds/2015/762

**ABSTRACT:** Road side accidents was the most common cause (55percent) followed by assault (11percent) and agricultural (9percent), incidences. Audiological assessment showed 39 patients having hearing loss (28 conductive, 7mixed and 4 sensory neural). Temporal bone fractures were in 17 cases (14 longitudinal; 3 transverse). Laceration of pinna and external auditory canal was present in 13 patients. 2 cases were having pre-auricular and post –auricular abrasions. The rupture of tympanic membrane was found in 15 cases and csf otorrhea in 3cases. The facial nerve damage or injury was found in 6 patients (3 longitudinal fractures; 2 transverse fractures; one patient had partial paralysis due to fracture of lateral orbital wall with mandible) whereas two patients had mastoid tenderness. **MATERIALS AND METHODS:** The study was conducted at ENT department of AVBRH Sawangi (Meghe), Wardha about 100 cases of head injuries admitted in surgical ward of AVBRH Sawangi (meghe), Wardha. Detailed clinical history would be taken and E.N.T examination was done and recorded on a performa (Annexure1). A detailed neurological examination in each case including the cranial nerve functions, gait tests and appropriate cerebeller function tests were taken. All the conscious patients was subjected to Tuning fork tests and pure tone auditory and impedance auditory whether indicated. Radiological investigation of each patient were reviewed and finally the findings obtained was compiled.

**KEYWORDS:** Temporal bone fracture with hearing loss, CSF otorrhea, Facial palsy.

**INTRODUCTION: CONCLUSION AND INTERPRETATION:** Majority of patients fall in 21-30 years; less in young as well as older groups. So children should be discourage from driving and specially the fast driving:

1. Roadside injuries were the most common cause of head injuries. Another factor is that non-compliance of putting head gears and to tie belts during the driving lead to these deadful injuries.
2. Dizziness and headache were the major symptoms. Proper rest, restrictions of movements by these patients does help them and they should also avoid unnecessary medication which help them and they should also avoid unnecessary medication which will hinder with the central compensation of these patients. Usually the compensation occurs in 6-8 weeks-time. Head ache present in most of the patients was releaved with passage of time.
3. Bleeding from nose along with CSF rhinorrhoea was also one of the signs. It stopped after few days; these patients should not be given local medications. Antibiotics may be given to avoid infection.
4. Bleeding from nose along the CSF rhinorrhea was also one of the signs. It usually stops. The patients are given bed rest with head rest. Valsalva's manoeure is avoided. CSF Fistulae usually closes by 10 days. Surgical correction should only be undertaken if it persist after 10 days. All

## ORIGINAL ARTICLE

---

Mid face fractures should be corrected before three weeks as after that permanent disunion occur and it may not be possible to correct them properly.

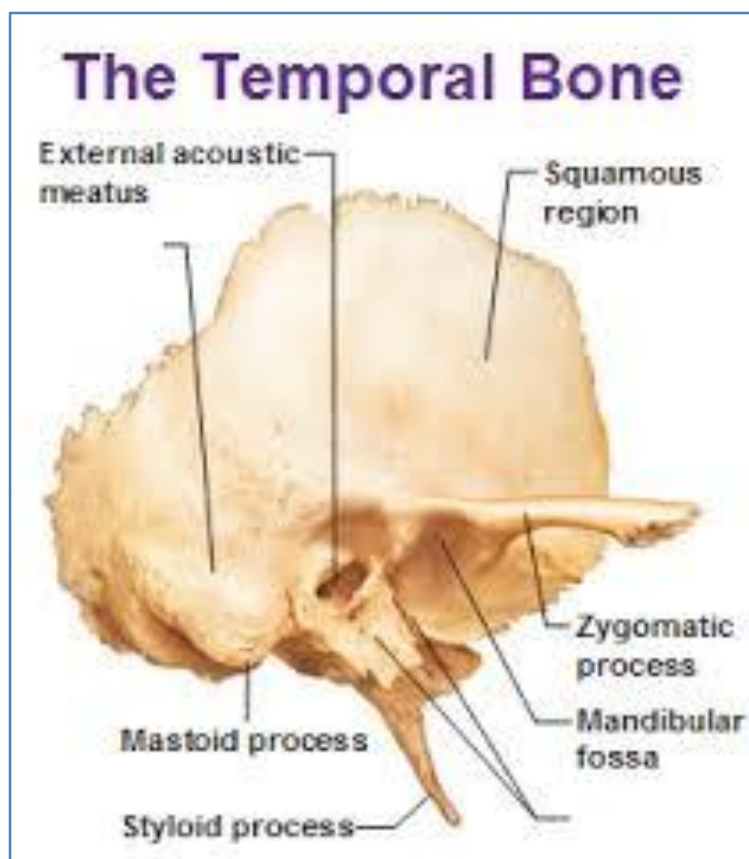
5. Facial paralysis was also notable sign.
6. Facial paralysis in cases where the onset is early, the prognosis is usually better with or without Surgery. If transverse temporal bone fractures with complete facial paralysis and total hearing loss then facial should be decompressed by translabyrinthine approach. If hearing is good and lesion is in pregeniculate region then transmastoid along with middle cranial fossa approach should be preferred. Facial paralysis with delayed onset has poor prognosis. Similarly the facial paralysis associated with transverse fracture has got poor prognosis. Surgical decompression should be taken in these patients within 3 to 6 days or if Electrodiagnostic tests shows 90 percent degeneration of the nerve.
7. Patients with longitudinal fractures showed mostly conductive type of hearing loss while mixed hearing loss was also reported in few cases. All transverse fracture cases showed sensory neural hearing loss. Conductive deafness due to blood in middle ear and patients gets improvement in hearing. So is true of tympanic membrane perforation which also gets healed in 10 to 15 days.
8. CSF otorrhea subsided after 10 days of medication and hospitalization. CSF otorrhea usually associated with bleeding from ears sometime it's masked by blood. These patients should be given antibiotics specially those which cross the blood brain barrier to avoid meningeal infection. Only if it persists upto two weeks then surgical intervention should be thought off. However CSF otorrhea signifies tear in dura and in turn fracture.
9. Bleeding from throat is usually due to nose bleed or blood from ears through Eustachian tube enter the nasopharynx
10. Role of CT scan is of immense value, particularly useful in CSF rhinorrhea and CSF otorrhea cases in finding out the exact site of bone injury and thus useful in their management.

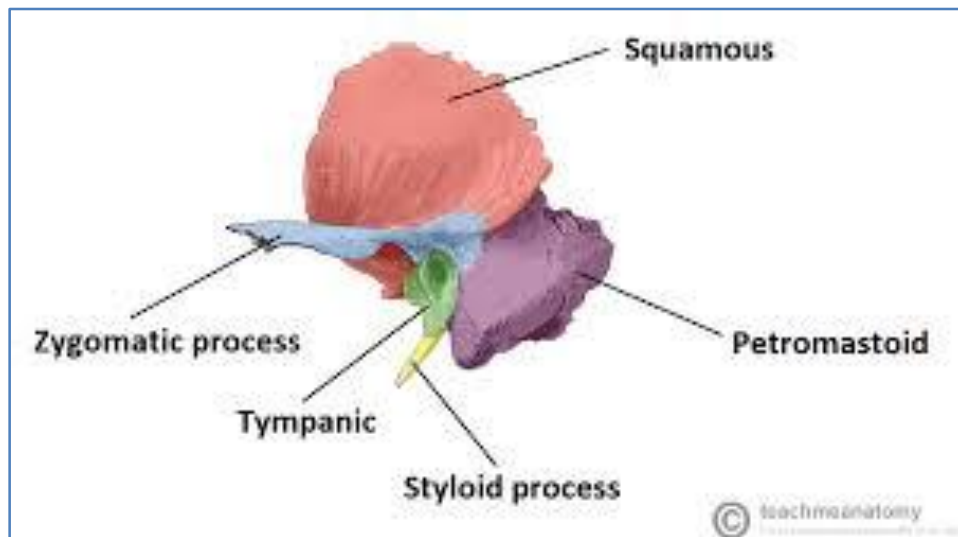
### **BIBLIOGRAPHY:**

1. Wills T. as quoted in 1983: Chahat NI, Mich D. Middle ear effects of head trauma. *Laryngoscope*, 1971; 81: 1286.
2. Brodie H A, Thompson T.C. Management of complications from 820 temporal bone fractures. *Am J Otol*. 1997; 18 (2): 188-97.
3. Cannon CR, Jahrs dofer RA. Temporal bone fracture: Review of 90 cases. *Arch Otol*. 1983; 109: 28-88.
4. Kelly KE, Tami TA. Temporal bone and skull trauma. Eds. Jackber RK, Brack Many DE. *Neurology, St. Louis*. 1994; Pp1127-47.
5. Chamyal PC, Ahluwalia LJ. Audiovestibular derangement in trauma trauma. *Indian J. Otolaryngol*. 1983; 35-60.
6. Kerr AG, Symth GDL. Ear trauma. From the text book of Scott Brown's *Otolaryngology*. 5<sup>th</sup> Edition, Vol.3, 1987; 172-84.
7. Kahn J B, Stewart M G, Diaz- Marchan PJ. Acute temporal bone trauma: utility of high – resolution computed tomography. *Am J Otol*. 2000; 21(5): 743-52.
8. Moore P L, Selby G, Irving R M. Gunshot injuries to the temporal bone. *J. Laryngol Otol*. 2003; 117(1): 71-4.

## ORIGINAL ARTICLE

9. Bento R F, de Brito R V. Gunshot wounds to the facial nerve. *Otol Neurotol.* 2004; 25(6): 1009-13.
10. Rafferty M A, Mc Conn Walsh M A. A comparison of temporal bone fracture classification systems. *Clin Otolaryngol.* 2006; 31(4): 287-91.
11. Conoyer J M, Kaylie D M, Jackson C G. Otolgic surgery following ear trauma. *Otolaryngol Head Neck Surg.* 2007; 137(5): 757-61.
12. Kummoona R. Post -traumatic missile injuries of the orofacial region. *J. Craniofac. Surg.* 2008; 19(2): 300-5.
13. Misaki K, Muramatsu N, Nitta H. Endovascular treatment for traumatic ear bleeding associated with acute epidural hematoma. *Neurol Med Chir (Tokyo).* 2008; 48(5): 208-10.
14. Johnson F, Semaan MT, Megerian C A. Temporal bone fracture: evaluation and management in the modern era. *Otol Neurotol.* 2008; 41(3): 597-618.
15. Grant J R, Arganbright J, Friedland D R. Outcomes for conservative management of traumatic traumatic conductive hearing loss. *Otol Neurotol.* 2008; 29(3): 344-9.





**AUTHORS:**

1. Vikramjit Singh Parmar
2. S. V. Golhar
3. P. Deshmukh
4. Poonam Pathania

**PARTICULARS OF CONTRIBUTORS:**

1. Assistant Professor, Department of ENT, MAMC, Agroha, Hisar.
2. Professor, Department of ENT, AVBRH, Sawangi, Wardha.

**FINANCIAL OR OTHER**

**COMPETING INTERESTS:** None

3. Professor, Department of ENT, AVBRH, Sawangi, Wardha.
4. Post Graduate Student, Department of Prosthodontics, Swami Devi Pyal Dental College.

**NAME ADDRESS EMAIL ID OF THE CORRESPONDING AUTHOR:**

Dr. Vikramjit Singh Parmar,  
# 1, Jagadish Ashram, Patiala, Punjab.  
E-mail: [nndy2@rediffmail.com](mailto:nndy2@rediffmail.com)

Date of Submission: 06/02/2015.  
Date of Peer Review: 07/02/2015.  
Date of Acceptance: 31/03/2015.  
Date of Publishing: 13/04/2015.