

STUDY OF ACCESSORY SOLEUS – AN ANATOMICAL AND CLINICAL INSIGHT

Sheetal B. Joshi¹, Pradnya V. Garude², Amit Kale³, B. H. Bahetee⁴, Nutan D. Mandke⁵, Ajay Chandanwale⁶

HOW TO CITE THIS ARTICLE:

Sheetal B. Joshi, Pradnya V. Garude, Amit Kale, B. H. Bahetee, Nutan D. Mandke, Ajay Chandanwale. "Study of Accessory Soleus – An Anatomical and Clinical Insight". Journal of Evolution of Medical and Dental Sciences 2014; Vol. 3, Issue 29, July 21; Page: 8059-8066, DOI: 10.14260/jemds/2014/3012

ABSTRACT: BACKGROUND: Accessory soleus muscle may give rise to symptoms such as pain with exertion, during running and jumping. The study of these types of variations with its frequencies is important in the planning of operative treatment. Recognition of an accessory soleus muscle is an issue that needs to be addressed for this reason, the present study was proposed. **AIMS AND OBJECTIVES:** Aim of the present study was to find out the presence of accessory soleus muscle and its frequency in cadaveric lower limbs and to note if there was any variation in its origin and insertion. **MATERIAL AND METHODS:-**All together 40 Lower limbs of 20 cadavers (16 males and 04 females) were dissected. Origin and insertion of soleus muscle was observed meticulously and presence of accessory soleus muscle was recorded and photographed. **RESULT:** Out of 20 cadavers two male cadavers (four lower limbs) that are 10% showed accessory soleus muscle bilaterally, with a rare and unique insertion. **CONCLUSION:** The present study highlights rare variation pertaining to the insertion of soleus muscle which should be kept in mind by the surgeons, orthopaedicians, radiologists and also by physiotherapists.

KEYWORDS: Accessory soleus, tendo achillis, calcaneus.

INTRODUCTION: The soleus muscle arises primarily by two heads, which are united by a tendinous arch. The fibular head of the soleus arises from the posterior surface of head of the fibula and about third of the shaft; the tibial head arises from the soleal line on the tibia. Muscular fibers of the soleus end in a broad aponeurosis and unite with aponeurosis of the gastrocnemius to form tendo calcaneus. It is supplied by lower muscular branches of popliteal artery, arising close to the knee joint and its innervation is derived from tibial nerve.¹

The gastrocnemius and soleus together form a muscular mass which is occasionally described as the Triceps surae; its tendon of insertion is the tendo calcaneus (Tendo Achillis), the common tendon of the gastrocnemius and soleus, is the thickest and strongest in the body. It is about 15cms. long, and begins near the middle of the leg, but receives fleshy fibers on its anterior surface, almost to its lower end.²

Like most of the anatomical variations of the human muscular system, the accessory soleus muscle was well known to early anatomists as well. It has been described at the end of the 19th century by Ledouble (1897).³

The occurrence of an accessory soleus muscle seems to be the most frequently described anatomical variation in the calf muscles.⁴

The present study explores the soleus in terms of variability of its proximal and distal attachments.

ORIGINAL ARTICLE

MATERIAL AND METHODS: The present study was carried out in the Department of Anatomy at B.J. Government Medical College, Pune. Lower limb of twenty cadavers (16 males and 04 females) were dissected. The specimens were labeled from 1 to 20 indicating the right and left side. In all forty lower limbs the origin and insertion of soleus muscle was observed meticulously and in addition either accessory soleus muscle was present or not was noted. The findings were recorded and photographed.

OBSERVATIONS AND RESULTS: Out of 40 specimens of inferior extremities the accessory soleus muscle was observed in 4 specimens. In 36 lower extremities the soleus muscle arose normally by two heads, which are united by a tendinous arch. These extremities also showed no variation in their distal attachment where in, Soleus muscle along with the medial and the lateral heads of gastrocnemius formed the tendo calcaneus which got inserted into the middle part of the posterior surface of the calcaneus bone. But in two adult male cadavers (specimen numbered 5 and 16) the soleus muscle had additional fibers arising from deep fascia. Careful observation of these specimens revealed that in the middle third of the leg, few of the soleal skeletal fibers traversing anterior to the tendon of gastrocnemius separated away from it. These fibers of soleus in the distal third of the leg became tendinous and finally inserted on the flexor retinaculum. (Refer figure 1, 2 and 3).

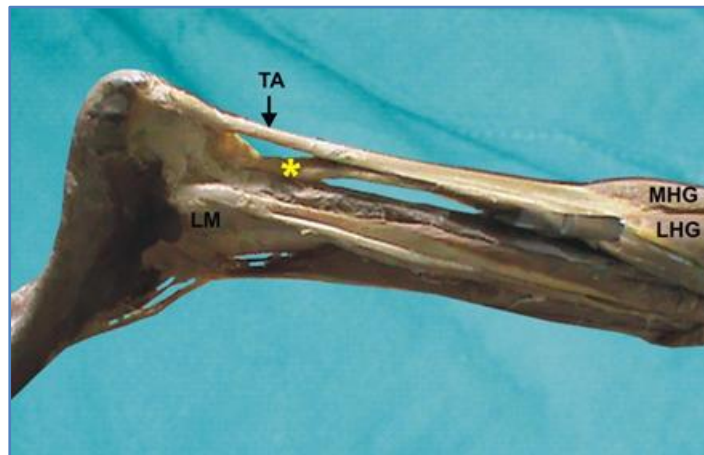


FIGURE 1

Figure 1: Showing in specimen no. 5 an accessory soleus muscle in right leg of adult male cadaver. (lateral view photograph)

TA –tendoachillis, LM – lateral malleolus, MHG – medial head of Gasterocnemius, LHG – lateral head of gastrocnemius, * - accessory insertion of soleus

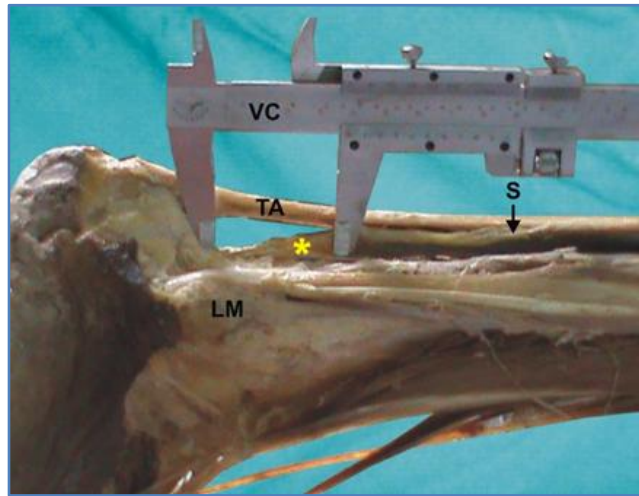


FIGURE 2

Figure 2: Showing in specimen no. 5 an accessory soleus in right leg of adult male cadaver. (lateral view photograph)

TA – tendoachillis, LM – lateral malleolus, S – soleus, VC – vernier calliper, * - accessory insertion of soleus.

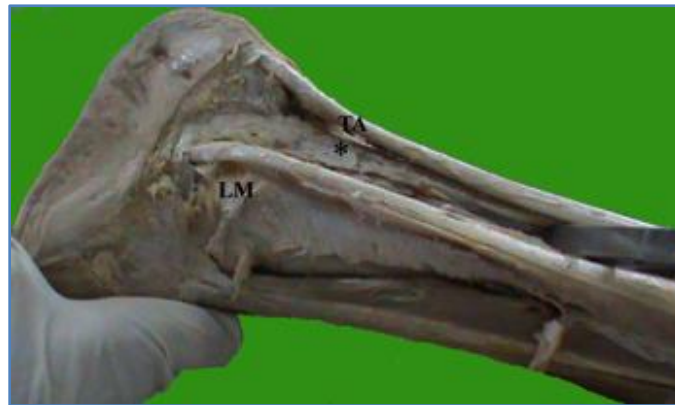

FIGURE 3

Figure 3: Showing in specimen no. 16 an accessory soleus in right leg of adult male cadaver. (lateral view photograph)

TA – tendoachillis, LM – lateral malleolus, * - accessory insertion of soleus

In 2 adult male cadaver specimens (four lower limbs) showing accessory soleus the length of tendoachillis and of the accessory tendon were recorded. (Refer table 1)

ORIGINAL ARTICLE

Specimen no.	Sex	Side	Length of tendoachillis	Length of accessory tendon of Soleus
5	Male	Right	4 cm	4.5 cm
		Left	4 cm	4.5 cm
16	Male	Right	5.5 cm	3.5 cm
		Left	5.5 cm	3.5 cm

Table 1: Showing observations of accessory soleus recorded in two adult male cadavers

DISCUSSION: The present study displays bilateral anomalous pattern of the soleus muscle in 2 cadavers (10%). Kouvalchouk et al estimated that accessory soleus was present in 10% of all individuals.⁵ The findings of present study are in its accordance.

Some authors, like Hansen LB, Broeng L, Del Sol M et al, Kendi et al and Christodoulou et al considered that the occurrence of an accessory soleus muscle was a rare anatomical variation.^{6,7,8,9}

Researchers have worked on accessory soleus in cadavers. But comparison of their work alarms a situation where though rare but a gradual rise in frequency of accessory soleus is observed. It also reflects limitation of present study in terms of its small sample size and demands for a large subset of population to be evaluated. (Refer table 2).

	Del Sol M ⁷	Downey and Siegerman ¹⁰	GOSAVI, S. R. ¹¹	Shaikh S.T ¹²	Present study
Sample size No. of lower limbs	254	689	60	100	40
No of accessory soleus	2	13	1	6	4
Percentage	0.8	1.9	1.7	6	10

Table 2: Comparison of findings of Authors who studied accessory soleus in cadavers

Del Sol M performed 254 dissections in young adults of both sexes and different ethnic origin. He found only 2 accessory soleus muscles, both in males. One originated from the soleus muscle and was inserted in the superior aspect of the "calcaneo", in front of the "tendon calcaneo". The other originated from the anterior fascia of the soleus muscle and was inserted on the medial aspect of the "calcaneo".⁷

The observations of present study are partially in correlation with second specimen recorded by Del Sol M⁷ in terms of its proximal attachment only. This gives an understanding that distal attachment put forth in present study is rare as well as unique. But both studies show male predominance

An accessory fasciculus is sometimes formed on the anterior surface of the soleus. Its fibers take origin from the fascial covering of soleus and run posteromedially to a bipenniform insertion into a thin lamina that joins with the tendo-Achilles.¹³

Supernumerary fascicles of muscle have also been described. These are usually reported as thin flat muscles originating from the fibula and soleal line of the tibia or from the deep fascia of the soleus and inserting via a tendon into the calcaneus medial to the tendo-Achilles.¹⁴

ORIGINAL ARTICLE

Thus in the present study fibers arising from fascia anterior to soleus can be referred to as accessory fasciculi or Supernumerary fascicle.

The distal insertion on the contrary is much more variable.^{15, 16, 17} Yu and Resnick defined five different types: along the Achilles tendon, on the superior aspect of the calcaneus via a separate tendon or directly via the muscle body and on the medial aspect of the calcaneus, here too, either via a separate tendon or via the muscle body.¹⁸

Lorentzon R Wirell S found accessory muscle in four cases showing four different varieties of insertion, i.e. along the tendon of Achilles, fleshy to the upper surface of the calcaneus, by a separate tendon to the upper surface of the calcaneus and fleshy to the medial surface of the calcaneus.¹⁷

Bonnel and Cruess observed a forked tendon inserted on the medial and lateral aspects of the calcaneum¹⁹ whereas Barberini et al, reported the tendon to be inserted on medial to the calcaneal tendon.²⁰

A cadaveric case reported by Sarabpreet Singh R. highlights a musculo-tendinous slip, originating from the inferolateral aspect of soleus, coursing on the lateral aspect of the tendoachilles and fusing distally with the achillis tendon.²¹

Accessory head to its lower and inner part of soleus usually ending in the tendocalcaneus, or the calcaneus, or the lacinate ligament has been documented by Hamilton WJ.²²

Grays²³ mentions accessory soleus is sometimes present distally and medially. It may insert into the calcaneal tendon, calcaneus or the flexor retinaculum.

Literature reflects that the distal attachment of soleus recorded in present study is rarely observed and documented. This contributes significant information to operating surgeons.

Authors like Danielsson LG, EL-Haddad I, Sabri T,²⁴ Chotigavanichaya et al,²⁵ Waleed E. Kishta, Emad H, Mansour, Mazen M., Ibrahim²⁶ they came across accessory soleus while dealing with clubfoot deformity. They observed that this muscle caused resistance to correction by standard method of posteromedial release.

CONCLUSION: Dunn is credited with the report of the first clinical case of accessory soleus in the English literature.²⁷ The commonest presentation of accessory soleus muscle is in the form of a swelling at the posteromedial aspect of the ankle in adolescents or young adults, which is often painful.^{8, 28, 29, 30}

Such cases are usually diagnosed by imaging studies, of which computed tomography (CT) and magnetic resonance imaging (MRI) are most useful.³¹

CT Scan supported evaluation of accessory soleus was carried out by Romanus B, Lindahl S, Stener B,²⁹ Lorentzon R, Wirell S, ¹⁶ Hansen LB1, Broeng L⁶ whereas, authors like Downey MS, Siegerman J.,¹⁰ Boisgard S, Peronne E, Kalfon P, Levai JP, Michel JL³² Brodie JT, Dormans JP, Gregg JR, Davidson RS.³³ preferred magnetic resonance imaging study for the evaluation of condition with accessory soleus.

Awareness of the clinical presentation and specific findings of computed tomography, magnetic resonance imaging, and electromyography help with diagnosis of variants of soleus muscle without surgical exploration.

It is well established that local muscle flaps are easier to perform than microsurgical flaps and the soleus muscle is a valuable tool for flap coverage of wounds of distal third of the leg.³⁴ Thus soleus muscle is commonly used to reconstruct soft tissue defects of the lower limb. The present study

highlights certain unique and rare variations of soleus which are significant to surgeons planning for reconstructive treatment.

REFERENCES:

1. Hollinshead WH. Anatomy for Surgeons. The Back and Limbs. 3rd ed, Vol 3. Philadelphia: Harper and Row Publisher Inc; 1982: 775-784.
2. Last RJ. Anatomy: Regional and Applied. 7th ed. Edinburgh: Churchill Livingstone; 1984: 89.
3. Bejjani FJ, Jahss MH. Le Double's study of muscle variations of the human body. Part I: Muscle variations of the leg. Foot Ankle. 1985; 6(part I): 111-134.
4. Motto S, Holloway G. The accessory soleus muscle. Br. J Sports Med. 1996; 30: 185.
5. Kouvalchouk JF, Lecocq J, Parier J, Fischer M. The accessory soleus muscle: a report of 21 cases and a review of the literature. (In French). Rev Chir Orthop Réparatrice Appar Mot. 2005; 91: 232-238.
6. Hansen LB, Broeng L. Accessory soleus muscle. (In Danish). Ugeskr Laeger. 1991 Oct 28; 153(44): 3090-1.
7. Del Sol M, Junge C, Binvignat O, Prates J, Ambrosio J. The accessory soleus muscle: 2 cases. (Article in Spanish) Rev Med Chil. 1989 Jun; 117(6): 677-81.
8. Kendi TK, Erakar A, Oktay O, Yildiz HY, Saglik Y. Accessory soleus muscle. J Am Podiatr Med Assoc. 2004; 94: 587-589.
9. Christodoulou A, Terzidis I, Natsis K, Gigis I, Pournaras J. Soleus accessorius, an anomalous muscle in a young athlete: case report and analysis of the literature. Br J Sports Med. 2004; 38(6): e38.
10. Downey MS, Siegeman J. Accessory soleus muscle: a review of the literature and case report. J Foot Ankle Surg 1996; 35: 537-543.
11. Gosavi SR, Gajbe UL, Andmeshram S. Accessory soleus muscle: A rare tissue variation with its clinical significance. Journal of Cell and Tissue Research. 2011; Vol. 11(1) 2541 – 2543.
12. Shaikh ST. A study of the accessory soleus muscle. Int j clin surg adv. 2013; 1(2): 51-55.
13. Anson B. Morris' Human Anatomy. 12th ed. New York: McGraw-Hill Co. 1966; 592.
14. Palaniappan M, Rajesh A, Rickett A, Kershaw CJ. Accessory soleus muscle: a case report and review of the literature. Pediatric Radiol. 1999; 29: 610–612.
15. Lozach P, Conrad JP, Delarue P, Le Saout J, Courtois B. A case of an accessory soleus muscle. (in French) Rev Chir Orthop Réparatrice Appar Mot. 1982; 68: 391-393.
16. Lorentzon R, Wirell S. Anatomic variations of the accessory soleus muscle. Acta Radiol. 1987; 28: 627- 629.
17. Motto S, Holloway G. the accessory soleus muscle. Br. J Sports Med. 1996; 30: 185.
18. Yu JS, Resnick D. Imaging of the accessory soleus muscle appearance in six patients and review of the literature. Skeletal Radiol. 1994; 23: 525-528.
19. Bonnel J, Cruess RL. Anomalous insertion of the soleus muscle as cause of the fixed equinus deformity: a case report. J Bone Joint Surg. 1969; 51-A: 999–1000.
20. Barberini F, Bucciarelli-Ducci C, Zani A, Cerasoli D. Unusual extended fibular origin of the human soleus muscle: possible morpho-physiologic significance based on comparative anatomy. Clin Anat. 2003; 16: 383–388.

ORIGINAL ARTICLE

21. Sarabpreet Singh, RK Suri, Vandana Mehta, Hitendra Loh, Jyoti Arora, Gayatri Rath. Bilateral additional bellies of the soleus muscle: anatomical and clinical insight. *International Journal of Anatomical Variations*. 2009; 2: 20–22.
22. Hamilton WJ. *Textbook of the Human Anatomy*. 2nd ed, London: Macmillan Press Ltd; 1976: 651.
23. Andrew Williams, Richard LM, Mark SD, Patricia C. *Gray's Anatomy*, 40th edn, New York: Elsevier Churchill Livingstone,; 2010; 1421
24. Danielsson LG, EL-Haddad I, Sabri T. Clubfoot with supernumerary soleus muscle. *Acta Orthop Scand*. 1990; 61: 371–373.
25. Chotigavanichaya C, Scaduto AA, Jadhav A, Otsuka NY. Accessory soleus muscle as a cause of resistance to correction in congenital clubfoot: a case report. *Foot Ankle Int*. 2000; 21: 948–950.
26. Waleed E. Kishita, Emad H. Mansour, Mazen M. Ibrahim. The accessory soleus muscle as a cause of persistent equinus in clubfeet treated by the Ponseti method: A report of 16 cases *Acta Orthop. Belg*.2010; 76: 658-662.
27. Dunn AW. Anomalous muscles simulating soft-tissue tumours in the lower extremity. *J Bone Joint Surg*. 1965; 47-A: 1397–1400.
28. Paul MA, Imanse J, Golding RP, Koomen AR, Meijer S. Accessory soleus muscle mimicking a soft tissue tumor. *Acta Orthop Scand*. 1991; 62: 609-611.
29. Romanus B, Lindahl S, Stener B. Accessory soleus muscle. A clinical and radiographic presentation of eleven cases. *J Bone Joint Surg Am*. 1986 Jun; 68(5): 731-4.
30. Rossi R, Bonasia DE, Tron A, Ferro A, Castoldi F. Accessory soleus in the athletes: literature review and case report of a massive muscle in a soccer player. *Knee Surg Sports Traumatol Arthrosc*. 2009 Aug; 17(8): 990-5.
31. Nicholas GW, Kalenak A. The accessory soleus muscle. *Acta Orthop Scand*. 1984; 190: 279-280.
32. Boisgard S1, Peronne E, Kalfon P, Levai JP, Michel JL. Accessory soleus muscle. Two case-reports, with a review of the literature. *Rev Rhum Engl Ed*. 1996 Dec; 63(11): 862-5.
33. Brodie JT1, Dormans JP, Gregg JR, Davidson RS. 33. Accessory soleus muscle. A report of 4 cases and review of literature. *Clin Orthop Relat Res*. 1997 Apr; (337): 180-6.
34. Beck JB, Stile F, Lineaweaver W. Reconsidering the soleus muscle flap for coverage of wounds of distal third of the leg. *Ann Plast Surg*. 2003; 50: 631–635.

AUTHORS:

1. Sheetal B. Joshi
2. Pradnya V. Garude
3. Amit Kale
4. B. H. Bahetee
5. Nutan D. Mandke
6. Ajay Chandanwale

PARTICULARS OF CONTRIBUTORS:

1. Assistant Professor, Department of Anatomy, B. J. Government Medical College, Pune.
2. Assistant Professor, Department of Anatomy, B. J. Government Medical College, Pune.
3. Assistant Professor, Department of Orthopaedics, B. J. Government Medical College, Pune.
4. Professor and Head, Department of Anatomy, B. J. Government Medical College, Pune.

5. Professor, Department of Anatomy, B. J. Government Medical College, Pune.
6. Dean, B. J. Government Medical College, Pune.

NAME ADDRESS EMAIL ID OF THE CORRESPONDING AUTHOR:

Dr. Sheetal Joshi,
Waterlily – B, Flat No. 1,
Sukhawani Campus,
Pimpri, Pune-18.
Email: drsheetalbjoshi@rediffmail.com

Date of Submission: 27/06/2014.
Date of Peer Review: 28/06/2014.
Date of Acceptance: 07/07/2014.
Date of Publishing: 17/07/2014.