

COMPARATIVE STUDY OF PROXIMAL FEMORAL NAILING AND DYNAMIC HIP SCREW FOR INTERTROCHANTERIC FRACTURES IN ADULTS

Satya Kumar Koduru¹, Siddharth Potluri², C. Hanumantha Rao³, Srinivas Raghav T⁴

¹Professor, Department of Orthopaedics, NRI Academy of Sciences.

²Junior Resident, Department of Orthopaedics, NRI Academy of Sciences.

³Professor & HOD, Department of Orthopaedics, NRI Academy of Sciences.

⁴Senior Resident, Department of Orthopaedics, NRI Academy of Sciences.

ABSTRACT

AIMS

To compare the clinical and radiological outcomes of Proximal femoral nail and Dynamic hip screw fixation.

SETTINGS AND DESIGN

Prospective study of forty patients with Intertrochanteric fracture of femur presenting to our hospital from the year 2013 to 2015, who were treated with either proximal femoral nail or dynamic hip screw.

METHODS AND MATERIALS

The study material includes data collection, clinical examination and investigations of 40 patients who underwent either Dynamic hip screw or Proximal femoral nail. Out of 40 patients, twenty patients had undergone Proximal femoral nailing and twenty patients had undergone Dynamic hip screw fixation. All surgeries done on traction table and are followed up at regular intervals of 4 weeks, 8 weeks, 12 weeks, 6 months and annually thereafter. The clinical and functional results were assessed at follow-up.

RESULTS

The overall functional outcome of patient treated PFN was significantly better compared to DHS. However, when we compared the stable and unstable fractures separately, we found that there was no significant difference in the outcomes of the stable fractures in the two groups. Patients with proximal femoral nailing had significantly lower pain score at the 6th month follow-up.

CONCLUSIONS

We conclude that in stable intertrochanteric fractures, both the PFN and DHS have similar outcomes. However, in unstable intertrochanteric fractures the PFN has significantly better outcomes in terms of earlier restoration of walking ability. In addition, as the PFN requires shorter operative time and a smaller incision, it has distinct advantages over DHS even in stable intertrochanteric fractures. Hence, in our opinion, PFN may be the better fixation device for most intertrochanteric fracture.

KEYWORDS

Intertrochanteric Fractures, DHS, PFN, Functional Outcome.

HOW TO CITE THIS ARTICLE: Koduru SK, Potluri S, Rao CH, et al. Comparative study of proximal femoral nailing and dynamic hip screw for intertrochanteric fractures in adults. J. Evolution Med. Dent. Sci. 2016;5(35):2018-2021,

DOI: 10.14260/jemds/2016/474

INTRODUCTION.^{1,2}

Trochanteric fractures are one of the most common injuries sustained predominantly in patients over sixty years of age. They are three to four times more common in women who are osteoporotic; trivial fall being the most common mechanism of injury.¹ The goal of treatment of an intertrochanteric fracture is the restoration of the patient to his or her pre-injury status as early as possible. This led to internal fixation of these fractures to increase patient comfort, facilitate nursing care, decrease hospitalization and reduce complications of prolonged recumbency.² The type of implant used has an important influence on complications of fixation.

Financial or Other, Competing Interest: None.

Submission 29-12-2015, Peer Review 08-04-2016,

Acceptance 13-04-2016, Published 30-04-2016.

Corresponding Author:

Dr. Satya Kumar Koduru,

Flat-101, Kanchukota N. K,

Habitat Gayatri Nagar,

Vijayawada-520008, Andhra Pradesh.

E-mail: kodurusk@gmail.com

DOI: 10.14260/jemds/2016/474

Sliding devices like the dynamic hip screw have been extensively used for fixation. However, if the patient bears weight early, especially in comminuted fractures, these devices can penetrate the head or neck, bend, break or separate from the shaft. Intramedullary devices like the proximal femoral nail have been reported to have an advantage in such fractures as their placement allowed the implant to lie closer to the mechanical axis of the extremity, thereby decrease the lever arm and bending moment on the implant. They can also be inserted faster with less operative blood loss and allow early weight bearing with less resultant shortening on long-term follow-up. The purpose of the present study is to verify the theoretical advantages of the proximal femoral nail over the dynamic hip screw device and also whether it actually alters the eventual functional outcome of the patient.

MATERIALS AND METHODS

The present study was conducted on 40 cases of intertrochanteric fractures femur above the age of 18 years. Patients were divided into two groups of 20 patients each. The first group was managed with Dynamic hip screw, while

second group was treated with proximal femoral nail.

Patients were given first aid in the form of skin traction, analgesics if any and appropriate antibiotics. Radiographic examination was done to assess the type, pattern, extent and displacement of fracture.

Inclusion Criteria

1. Patients above 18 yrs.
2. All types of intertrochanteric fractures.
3. Fractures <3 weeks old.
4. Patients who gave consent for study.

Exclusion Criteria

1. Patients below 18 yrs.
2. Bilateral fractures.
3. Pathological fractures.
4. Fractures associated with polytrauma.
5. Pre-existing femoral deformity,^{1,3} preventing hip screw osteosynthesis or intra-medullary nailing and Subtrochanteric fractures,^{1,4,5} extending 5 cm distal to the inferior border of the lesser trochanter were excluded from study group.

The decision for the type of the operation was based on surgeon's preference and availability of the implant. Prior to hip surgery, each patient was evaluated by the same trauma team. The overall time from injury to surgery averaged 4 days (Range: 1–6 days). The clinical outcome for each group was analysed, intraoperative, early and late complications were recorded. Patients followed up at regular intervals of 4 weeks, 8 weeks, 12 weeks, 6 months and annually thereafter and their functional outcome assessed.

RESULTS

The mean age was 62.6 yrs. with range of 32 to 80 years with female-to-male ratio of 5:3 and trivial fall being the most common mode of injury. The mean length of incision for DHS group was 16.15 cm and for the PFN group was 8.1 cm ($p=0.0001$). The mean duration of surgery for the DHS group was 87.25 min and the PFN group was 69.5 min ($p=0.0001$). The mean fluoroscopy time for the DHS group was 57.5 sec and for the PFN group was 73.75 sec ($p=0.0001$). The mean blood loss for the DHS group was 375 mL and the mean blood loss for the PFN group was 140 mL ($p=0.0001$). Malunion was seen in 5 cases of DHS fixation and in 1 case of PFN fixation. Wound infection was seen in 2 cases of DHS fixation and one case of PFN fixation; 1 case of screw blackout was seen in DHS group and no such complication was seen in the PFN group. No complication of Z effect or reverse Z effect was seen in the PFN group.

1.25 cm of mean shortening was seen with the DHS group and 0.575 cm of shortening was seen with PFN group ($p=0.003$). The post-operative range of movements were also significantly higher for the PFN group ($p=0.07$); 14 patients regained their pre-injury walking ability at the third month of follow-up as compared to the five patients in the DHS group.

Fracture union was achieved at 12 weeks in the DHS group as compared to 12.15 weeks for the PFN group with no statistical difference between the two groups ($P=0.765$).

50% of the patients in the DHS group had good-to-excellent functional outcome, whereas 95% of the patients in the PFN group had good-to-excellent functional outcome. Also 90% of the patients with stable fractures had excellent outcome in the DHS group, whereas 40% of the unstable

fractures had poor functional outcome with DHS fixation.

All the patients with stable fracture patterns had good-to-excellent functional outcome with PFN fixation, whereas 87.5% of unstable fractures had good-to-excellent functional outcome with PFN fixation.

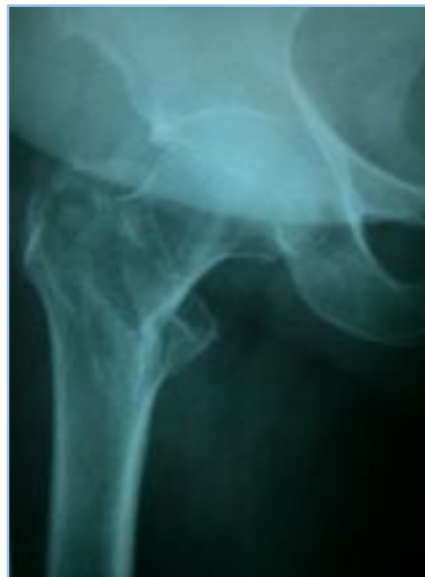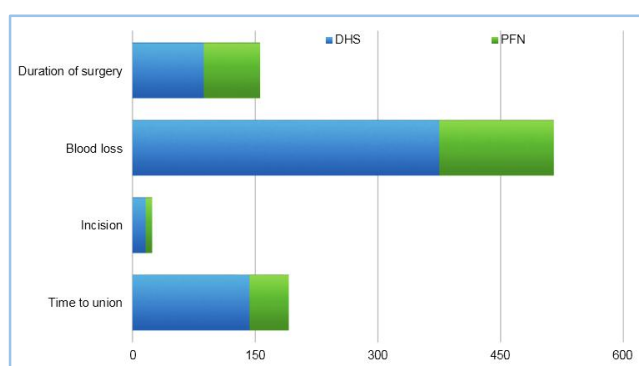


Fig. 1: Pre-operative

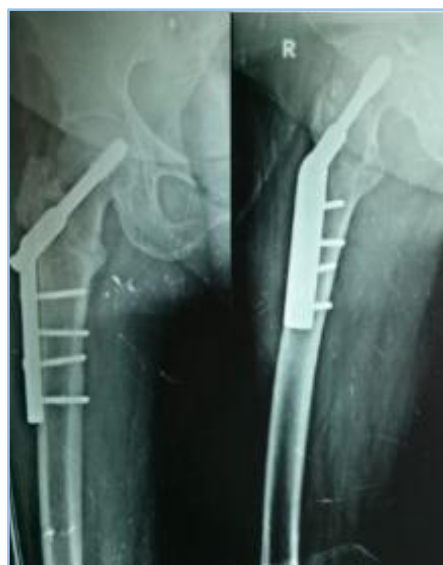

Fig. 2: Post-operative

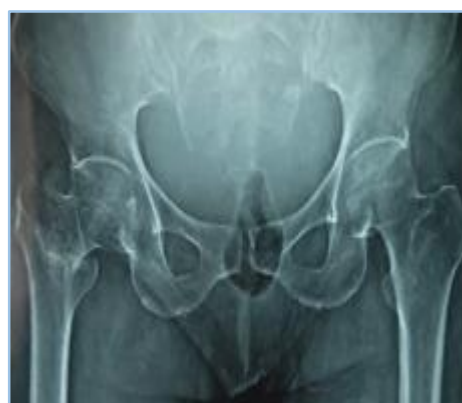
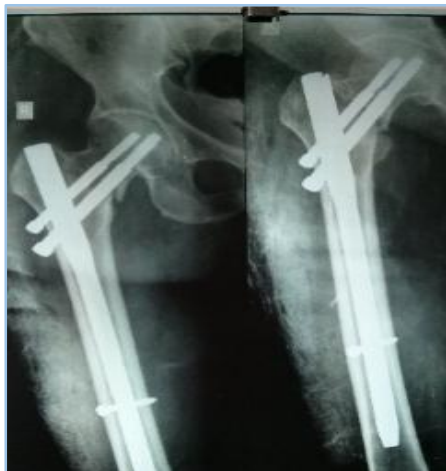
Fig. 3: Pre-operative**Fig. 4: Post-operative****Graph 1**

DISCUSSION

The goal of the study was to compare the functional outcome of patient with intertrochanteric fractures treated by two different fixation devices, the extramedullary dynamic hip screw fixation and the intramedullary proximal femoral nail. Our study consists of 40 patients with 40 intertrochanteric fractures, out of which 20 was treated with DHS and 20 with PFN. Majority of the patients with intertrochanteric fracture were elderly females with history of simple fall.

Majority of the patients with intertrochanteric fractures were elderly females with a history of trivial fall. The PFN group consistently required shorter incisions ($p=0.0001$), had less blood loss and shorter operative times ($p=0.0001$) when compared to the DHS group. Baumgaertner et al⁶ had comparable results regarding length of incision and blood loss similar to Pajarinen et al⁷ and Ishrat A Khan et al.⁸

The operative times on the other hand were reported to be comparable in the studies of Ishrat A Khan et al.⁸ and Saudan et al⁹ Pan et al¹⁰ and Giraud et al¹¹ reported significantly less surgery times for the PFN group compared to the DHS group. Papisimos et al¹² had reported shorter surgery times for the DHS group compared to the PFN group.

The occurrence of femoral shaft fractures does not seem to be a major problem with the PFN due to a narrower distal diameter as compared to other intramedullary nails.¹³ We did not encounter any intraoperative complication in this study. Other studies have also reported femoral shaft fracture rates of 0-2.1 percent.^{14,15} The only complications we encountered in this series were malunion, screw back out and wound

infection.

There was no significant difference between the two groups with regards to time of fracture union as all fracture united at 12 weeks in case of DHS and 12.15 weeks in case of PFN ($p=0.765$); 5 patients (25 percent) in the DHS group had malunion, whereas 1 patient (5%) in the PFN group had malunion. In this study, the average limb length shortening of patient in DHS group was 1.25 cm as compared to 0.575 cm in PFN group, which was significant ($p=0.003$). This could be due to sliding of the lag screw in the DHS group, allowing greater fracture impaction as compared to the PFN.⁷ Four of the ten patients in DHS with fair or poor results had 2 cm or more shortening, while 1 patient in PFN with fair result had 2 cm or more shortening.

One patient (5 percent) in our study had a hip screw back out. This was seen in the DHS group involving an unstable intertrochanteric fracture. However, these patients were relatively mobile and hence re-operation was not necessary. There was no implant cut out in the PFN group, which was similar to the series by Menezes and coworkers.¹³

The average range of motion of the hip joint was 84.25 degrees in the DHS group and 98.75 degrees in the PFN group at 6 months of follow-up. In our study, the patients in the PFN group regained a significantly better range of motion as compared to those in the DHS group. This is comparable to the results put forth by Saudan and Colleagues.⁹

The overall functional outcome of patient treated PFN was significantly better compared to DHS ($P=0.082$). However, when we compared the stable and unstable fractures separately, we found that there was no significant difference in the outcomes of the stable fractures in the two groups ($P=0.152$). While comparing the unstable fractures in the two groups, we found that the functional outcome of the patients in the PFN group was significantly better than the outcome of the patients in the DHS group with good results for 87.5% of the unstable fractures treated with PFN compared to only fair and poor results for 90% of the unstable fractures treated with DHS ($p=0.04$). Similar findings were seen in the series by Pajarinen and Group.⁷

The smaller incisions, shorter operative times, relatively less blood loss and less postoperative pain with the PFN indicate that the PFN has an advantage over the DHS even in the treatment of stable intertrochanteric fractures, where the functional outcomes are similar. In addition, with unstable intertrochanteric, the PFN has a definite advantage over the DHS in terms of less limb length shortening, earlier restoration of pre-injury walking ability and a better overall functional outcome.

CONCLUSION

We conclude that in stable intertrochanteric fractures, both the PFN and DHS have similar outcomes. However, in unstable intertrochanteric fractures, the PFN has significantly better outcomes in terms of earlier restoration of walking ability. In addition, as the PFN requires shorter operative time and a smaller incision, it has slight advantage over DHS even in stable intertrochanteric fractures. Hence, in our opinion, PFN may be the better fixation device for most intertrochanteric fractures.

REFERENCES

1. Kaufer H. Mechanics of the treatment of hip injuries. *Clin Orthop* 1980;146:53-61. Kaufer H, Mathews LS, Sonstegard D. Stable fixation of intertrochanteric fractures. *J Bone Joint Surg* 1974;56(5):899-907.
2. Larsson S, Elloy M, Hansson LI. Stability of osteosynthesis in trochanteric fractures. Comparison of three fixation devices in cadavers. *Acta Orthop Scand* 1988;59(4):386-90.
3. Steinberg GG, Desai SS, Kornwitt NA, et al. The intertrochanteric hip fracture. A retrospective analysis. *Orthopedics* 1988;11(2):265-73.
4. Sarmiento A, Williams EM. The unstable intertrochanteric fracture: treatment with a valgus osteotomy and I-beam nail-plate. A preliminary report of one hundred cases. *J Bone Joint Surg* 1970;52(7):1309-18.
5. Baumgaertner MR, Curtin SL, Lindskog DM. Intramedullary versus extramedullary fixation for the treatment of intertrochanteric hip fractures. *Clin Orthop* 1998;348:87-94.
6. Pajarinen J, Lindahl J, Michelsson O, et al. Peritrochanteric femoral fractures treated with a dynamic hip screw or a proximal femoral nail. A randomized study comparing post-operative rehabilitation. *J Bone Joint Surg* 2005;87(1):76-81.
7. Ishrat A Khan. O1013 To Nail or to Screw? *J of Bone and Joint* 2004;86-B(Supp III):225-6.
8. Saudan M, Lubbeke A, Sadowski C, et al. Peritrochanteric fractures: is there an advantage to an intramedullary nail? A randomized, prospective study of 206 patients comparing the dynamic hip screw and proximal femoral nail. *J Orthop Trauma* 2002;16(6):386-93.
9. Pan X, Xiao D, Lin B, et al. Dynamic hip screws (DHS) and proximal femoral nails (PFN) in treatment of intertrochanteric fractures of femur in elderly patients. *Chinese Journal of Orthopaedic Trauma* 2004;6(7):785-9.
10. Giraud B, Dehoux E, Jovenin N, et al. Peritrochanteric fractures: a randomized prospective study comparing dynamic screw plate and intramedullary fixation. *Revue de Chirurgie Orthopedique et Reparatrice de l'Appareil Moteur* 2005;91(8):732-6.
11. Papisimos S, Koutsojannis CM, Panagopoulos A, et al. A randomised comparison of AMBI, TGN and PFN for treatment of unstable trochanteric fractures. *Archives of Orthopaedic and Trauma Surgery* 2005;125(7):462-8.
12. Menezes DF, Gamulin A, Noesberger B. Is the proximal femoral nail a suitable implant for treatment of all trochanteric fractures? *Clin Orthop* 2005;439:221-7.
13. Boldin C, Seibert FJ, Fankhauser F. The proximal femoral nail (PFN): a minimal invasive treatment of unstable proximal femoral fractures: a prospective study of 55 patients with a follow-up of 15 months. *Acta Orthop Scand* 2003;74(1):53-8.
14. Fogagnolo F, Kfuri M, Paccola CA. Intramedullary fixation of peritrochanteric hip fractures with the short AO-ASIF proximal femoral nail. *Arch Orthop Trauma Surg* 2004;124(1):31-7.