

**STUDY OF EOSINOPHIL INFILTRATION IN NASAL POLYP**

Ambalika Mondal<sup>1</sup>, Satadal Mandal<sup>2</sup>, Amit Bikram Maity<sup>3</sup>, Shoham Banerjee<sup>4</sup>, Indranil Sen<sup>5</sup>, Rupam Karmakar<sup>6</sup>

**HOW TO CITE THIS ARTICLE:**

Ambalika Mondal, Satadal Mandal, Amit Bikram Maity, Shoham Banerjee, Indranil Sen, Rupam Karmakar. "Study of Eosinophil Infiltration in Nasal Polyp". Journal of Evolution of Medical and Dental Sciences 2015; Vol. 4, Issue 09, January 29; Page: 1480-1487, DOI: 10.14260/jemds/2015/208

**ABSTRACT:** Polyps of the nasal cavity and paranasal sinuses are hypertrophied, oedematous mucosa. Nasal polyps can be broadly divided into two groups, bilateral nasal polyposis & Choanal polyp (ACP). They are infiltrated with cells including, eosinophils, mast cells, lymphocytes and plasma cells. The study was aimed to evaluate the varying degree of eosinophil infiltration and to determine the significance of the infiltration of eosinophils. Out of total 50 cases (30 male & 20 female) 36 cases (72%) had bilateral polyposis and 14 cases (28%) had antrochoanal polyps. Infiltration of eosinophil in both types of polyp found to be statistically significant ( $p < 0.05$ ). Median value of number of eosinophil/HPF in B/L polyposis was 40 and in ACP it was 11. Difference in number of eosinophil/HPF among B/L polyposis and ACP found to be statistically significant ( $p = < 0.05$ ). From the above context we can say eosinophil infiltration in local tissue may play an important role in the pathogenesis of bilateral nasal polyposis. So the use of anti-inflammatory agents should logically form the mainstay of treatment in bilateral nasal polyposis.

**KEYWORDS:** Bilateral nasal polyposis, antrochoanal polyp, eosinophil.

**INTRODUCTION:** Polyps of the nasal cavity and paranasal sinuses are hypertrophied, oedematous mucosa. The overall prevalence of nasal polyposis is about 2%.<sup>1</sup> But the aetiology of the disease is still unknown. Although all nasal and paranasal polyps share morphologic similarities, but clinically and microscopically distinctive subtypes are noted. Nasal polyps can be broadly divided into two groups: (1) Bilateral nasal polyposis- grows from the ethmoid cells (Larsen and Tos, 1991),<sup>2</sup> and (2) Choanal polyp (ACP)- arises from one of the paranasal sinuses. According to its specific location they can be subdivided into antrochoanal polyp, sphenchoanal polyp and ethmoidchoanal polyp.<sup>3</sup>

Microscopically polyps are characterized by loose oedematous stroma, mucous gland, covered by respiratory epithelium which may exhibit squamous metaplasia. They are infiltrated with cells including, eosinophils, mast cells, lymphocytes and plasma cells. The amount and composition of the inflammatory components are highly variable. The present study was undertaken to determine the predominant cells involved in the pathogenesis of nasal polyps with special reference to eosinophils.

**AIMS & OBJECTIVES:** The study was aimed to evaluate the varying degree of eosinophil infiltration in the nasal polyp tissue and to determine the significance of the infiltration of eosinophils in different types of polyp. Specific objective was to count the mean number of eosinophils / HPF in polyp tissue, obtained from total number of eosinophils in 10 random high power fields.

**MATERIALS AND METHODS:** The study was conducted at the Department of Pathology, R.G. Kar Medical College and Hospital, Kolkata and Dept. of E.N.T. Midnapore Medical College & Hospital, West

## ORIGINAL ARTICLE

---

Bengal. After approval from institutional ethical committee and informed written consent from the patients, 50 cases including bilateral nasal polyposis and antrochoanal polyps of all age groups and both sexes were selected to this cross sectional study from April 2012 to March 2014.

**INCLUSION CRITERIA:** Bilateral nasal polyposis, antrochoanal polyp.

**EXCLUSION CRITERIA:** Neoplastic polypoidal mass, rhinosporidiosis, history of steroid intake during last one month before surgery.

**STUDY VARIABLES:** Outcome & dependent- magnitude of infiltration of eosinophils in nasal polyp. Independent – Age, sex.

**PARAMETERS ASSESSED:** Gross and microscopic examination of the specimens, history from the patients regarding any relevant information, evaluation of number of infiltrated eosinophils, and available data compiled by past-worker in this field.

**STUDY TOOLS:** Predesigned proforma (Case record form) (annexure – I), Consent form (annexure-II), Usual pathological instruments-scalpel, scalpel blades, forceps, knives, glass vials for collection of specimens, 10% formol saline, various grades of alcohol, xylene, paraffine, incubator, Leuckhart's L block, microtome, water bath, various stains, Koplins jar for staining, slides, cover slips, etc and Olympus CH20i binocular microscope.

**STUDYTECHNIQUE:** Specimens were examined thoroughly. Gross descriptions, size, shape, surface, dimension, cut surface etc were noted. Photographs of the specimens were taken. After gross examination, sections of tissue were taken. Routine paraffin embedded sections were prepared for microscopic examination by Haematoxylin and Eosin stain (H&E stain). The slides thus prepared then were examined to see the histology and to identify eosinophils in 10 different fields of each section at high magnification of 400X. Mean number of eosinophil per high power field obtained.

**STATISTICAL ANALYSIS:** Data were expressed as mean  $\pm$  standard deviation ( $\pm$ SD) and median. Comparisons between the groups were analyzed using the nonparametric Mann-Whitney U test. The Pearson correlation analysis was applied to evaluate the statistical significance between the two values. A p value less than 0.05 was considered to be statistically significant. For statistical analysis, SPSS software was used.

**RESULT AND ANALYSIS:** After the histological evaluation, 50 cases were selected from total 57 received tissue samples, which were diagnosed clinically as bilateral or unilateral nasal polyp. 7 cases were excluded from the study as histopathological examination of these polypoidal masses showed diagnosis other than nasal polyp. Out of total 50 cases (30 male & 20 female) 36 cases (72%) had bilateral polyposis and 14 cases (28%) had antrochoanal polyps. The age range of the patients was 7-71 years, with mean age 27.34. (SD  $\pm$  14.95). In case of B/L polyposis Median value of age was 28.5 and in case of ACP Median value of age were 12.5.

## ORIGINAL ARTICLE

The mean number of eosinophil per field at magnification of  $\times 400$  in absolute terms was counted and results were classified into 4 grades:

Grade 0:  $< 5$ /HPF; Grade 1: between 5-19/HPF; Grade 2: between 20-50/HPF; Grade 3:  $> 50$ /HPF.

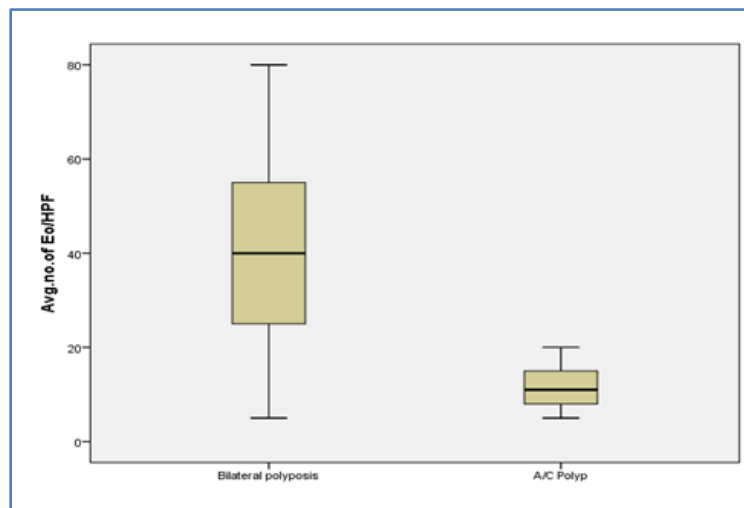
We observed no cases in Grade 0 ( $< 5$ /HPF) of eosinophilic infiltration. In case of B/L polyposis 4 cases (11.1%) were in Grade 1(5-19/HPF), 22 cases (61.1%) were in Grade 2 (20-50/HPF) and 10 cases (27.8%) were in Grade 3 ( $>50$ /HPF). In case of ACP 12 cases (85.7%) were in Grade 1(5-19/HPF), 2 cases (14.3%) in Grade 2 (20-50/HPF) and no cases were found to be in Grade 3.

| Mean no. of eosinophil / HPF $\times 400$ | No. of cases in B/L polyposis | Percentage (%) | No. of cases in ACP group | Percentage (%) |
|---|-------------------------------|----------------|---------------------------|----------------|
| $<5$                                      | 0                             | 0%             | 0                         | 0%             |
| 5-19                                      | 4                             | 11.1%          | 12                        | 85.7%          |
| 20-50                                     | 22                            | 61.1%          | 2                         | 14.3%          |
| $>50$                                     | 10                            | 27.8%          | 0                         | 0%             |

Mean no. of eosinophil per Field  $\times 400$  in Group with B/L Polyposis and in the Group with ACP

Infiltration of eosinophil in both types of polyp found to be statistically significant (Pearson Chi-Square test;  $df = 2$ ,  $p = < 0.05$ ). Median value of number of eosinophil/HPF in B/L polyposis was 40 and in ACP it was 11. Difference in number of eosinophil/HPF among B/L polyposis and ACP found to be statistically significant (Mann Whitney U tests showed  $p$  value =  $< 0.05$ ).

The Box-and-whisker plot showing range of distribution of eosinophil /HPF in B/L polyposis and ACP.



**DISCUSSION:** In this study, histopathological examination of nasal polyp tissue showed infiltration of inflammatory cells, such as lymphocytes, plasma cells, neutrophils, mast cells and eosinophils within

## ORIGINAL ARTICLE

the lamina propria. However antrochoanal polyps showed a lower inflammatory cell infiltrate and also a lower eosinophil infiltrate when compared to that of bilateral nasal polyposis.

In normal nasal mucosa, there are either no eosinophil or they are rare, but there is no consensus on when to consider that they constitute tissue eosinophilia.

GarínL et al.(2008)<sup>4</sup> described that the minimum figure to consider eosinophilia is 5 eosinophils/field  $\times 400$  in absolute quantification and 5% as a percentage by comparison with their control group, which presented on average fewer than 2 eosinophils/field.

This figure is supported by other previously published data byJankowski R et al.(2002)<sup>5</sup> and Prades JMet al. (2003).<sup>6</sup>

There is no unanimity among authors in the method of quantifying eosinophils, since some used the quantification of tissue eosinophilia in absolute values and others in relative values. In absolute terms, the results can be shown as the number of eosinophils per field or as the number of eosinophils per unit area. In relative terms, the results can be expressed as a percentage of eosinophils out of the total number of inflammatory cells as described by Jankowski R et al. in 2002<sup>5</sup> and Wei JL et al. in 2003.<sup>7</sup>

In present study we preferred Quantitative method for estimation of eosinophil because identification of eosinophil was easier due to orange- stained granular cytoplasm, while identification of some inflammatory cells required immunohistochemical methods.

| Number of eosinophils /HPF in Mag. x400 | Present study | Garín L et al. (2008) <sup>4</sup> |
|---|---------------|------------------------------------|
| <5                                      | 0%            | 10%                                |
| 5-19                                    | 11.1%         | 32.5%                              |
| 20-50                                   | 61.1%         | 35%                                |
| >50                                     | 27.8%         | 22.5%                              |

**Comparative study of eosinophil per field  $\times 400$  in B/L polyposis, between present study and a previous major study**

Our data confirm that tissue eosinophilia is a constant feature in B/L nasal polyposis, as 100% of our B/L nasal polyposis cases had eosinophilia in tissue. On the quantitative side, the majority (61.1%) had number of eosinophils between 20 and 50 per field  $\times 400$ . These results are comparable with study published by GarínL et al.<sup>4</sup> as they also found that 90% of their patients had eosinophilia in polyp tissue and the majority (35%) had number of eosinophil between 20 and 50 per field  $\times 400$ . These findings are also supported by previous studies by Seiberling KA et al. (2005),<sup>8</sup> Jankowski R et al. (2002)<sup>5</sup> and also Prades JM et al.(2003).<sup>6</sup>

In present study though all cases of ACP showed tissue eosinophilia, a lower infiltration of eosinophil was seen when compared to B/L polyposis. On the quantitative side, the majority (85.7%) had number of eosinophil between 5 and 19 per field  $\times 400$ . and no cases had number of eosinophil  $>50$  per field  $\times 400$ .

This finding is supported by the previously published study by Min et al. in 1995.<sup>9</sup> They described that antrochoanal polyps show clear histologic differences when compared to bilateral polyps, consisting of a lower inflammatory infiltrate and a significantly lower eosinophil infiltrate.

## ORIGINAL ARTICLE

---

Inflammatory processes within the mucosa of the upper respiratory tract are believed to play an important role in the development of nasal polyposis.

Eosinophil infiltration and accumulation is highly characteristic of nasal polyp tissue. Eosinophils are known to be attracted from the peripheral blood circulation towards inflamed tissues where they become activated and modulate the inflammatory process by releasing the cytotoxic proteins including major basic protein (MBP), eosinophil cationic protein (ECP), eosinophil-derived neurotoxin (EDN) and eosinophil peroxidase (EPO). These facts are described by Mygind N in 1982<sup>10</sup> and Stoop AE. et al. (1993).<sup>11</sup>

Bernstein JM (2005)<sup>12</sup> reported that MBP secreted by eosinophils are implicated in altering the electrophysiology of the nasal polyp by altering the absorption of chloride and more importantly sodium into polyp.

Activated eosinophil also secretes IL5. Interleukin 5 (IL-5) is the key cytokine in an eosinophil's life span. Simon HU et al. (1997)<sup>13</sup> showed that IL5 supports eosinophilopoiesis and eosinophil differentiation, contributes to eosinophil migration, tissue localisation and function, and prevents eosinophil apoptosis. Denburg J<sup>14</sup> in 1997, also have described that the activated eosinophils secrete IL-5, which promote further eosinophil accumulation and activation.

A study regarding cytokine in nasal polyps, conducted by Bachert C. et al. (2000),<sup>15</sup> revealed that there were high amounts of IL-5 in the majority of nasal polyp specimen. This study indicated that IL-5 plays a key role in the pathophysiology of eosinophil dominated polyps.

Rudack et al. (1998)<sup>16</sup> and Bachert and Van Cawenberger<sup>17</sup> (1977) described that IL-5 has a chemotactic effect for eosinophils, and its synthesis is increased in nasal polyposis when compared to healthy mucosa or antrochoanal polyp.

Miguel Maldonado<sup>18</sup> in 2004 described that ACPs show an enhanced expression of IL-6 in comparison to controls, and more clearly resemble an acute infection than bilateral polyposis.

In the present study we have found that eosinophil infiltration was most constant finding in bilateral nasal polyposis when compared to antrochoanal polyp. Since activated eosinophils can release a variety of cytotoxic proteins and growth factors, eosinophil infiltration of local tissue is suspected of contributing significantly to the pathogenesis of bilateral nasal polyposis and to the persistence of the eosinophilic inflammatory process.

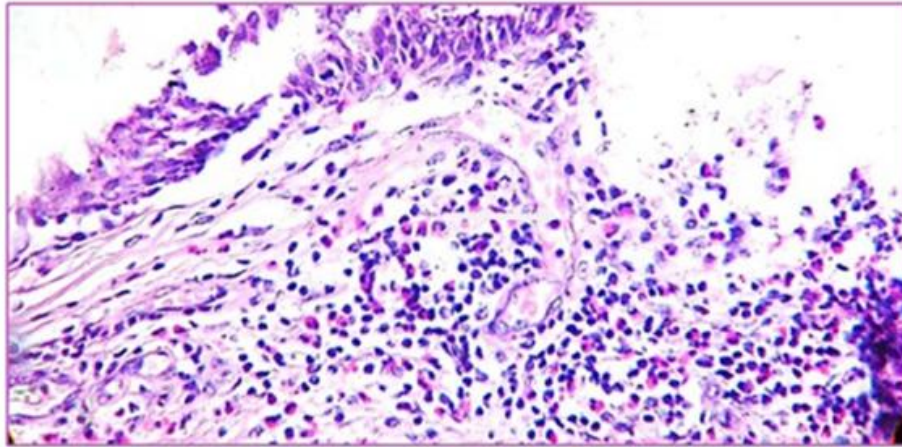
**CONCLUSION:** So in present study we found that infiltration of eosinophils and mast cells was a significant histological feature in the bilateral nasal polyposis. This pattern is similar to the ones found in the major studies.

In the present study we have found that eosinophil infiltration and accumulation is highly characteristic of bilateral nasal polyposis when compared to antrochoanal polyp. Since activated eosinophils can release a variety of cytotoxic proteins and growth factors, eosinophil infiltration of local tissue may cause local oedema and persistence of the eosinophil inflammatory process. Thus it may contribute significantly to the pathogenesis of bilateral nasal polyposis. But exact initiating or triggering event at the cellular level has not yet been identified.

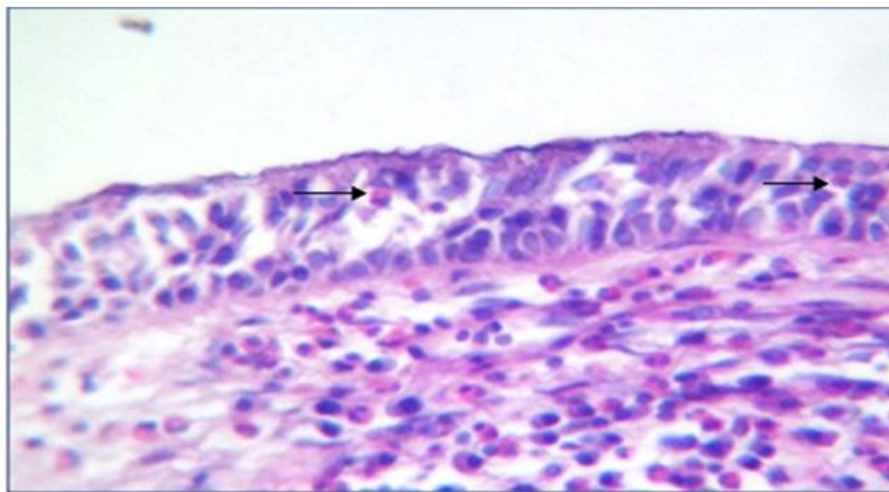
From the above context we can say eosinophil infiltration in local tissue may play an important role in the pathogenesis of bilateral nasal polyposis. So the use of anti-inflammatory agents should logically forms the mainstay of treatment in bilateral nasal polyposis.

## ORIGINAL ARTICLE

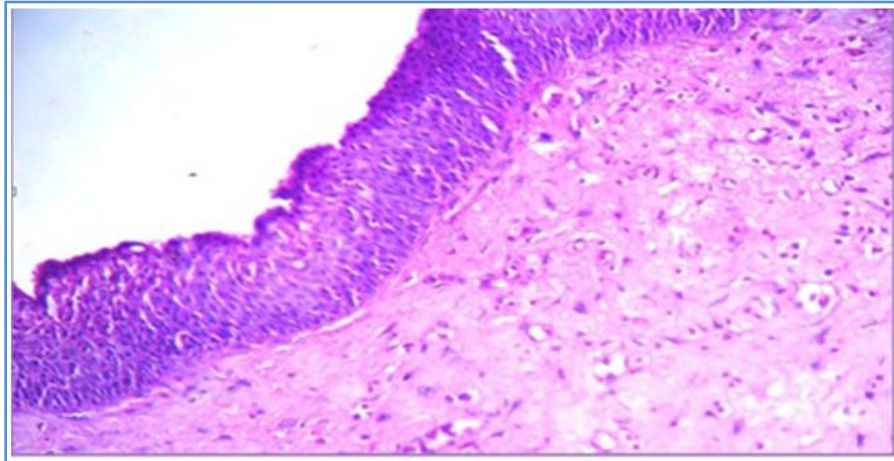
Antrochoanal polyps showed overall lower cellular infiltrate, including mast cells and a significantly lower eosinophilic infiltration. In antrochoanal polyps surgery is the only feasible treatment. There is a lack of research regarding exact pathophysiological mechanisms of antrochoanal polyps, which has to become the main aims for future investigations of this disease.



**Fig. 1: Photomicrograph of bilateral nasal polyposis showing dense inflammatory infiltrate with predominance of eosinophils. (H&E x 100)**



**Fig. 2: Photomicrograph of bilateral nasal polyposis showing eosinophils within epithelium (arrows) also in underlying stroma. (H&E, x 400)**



**Fig. 3: Photomicrograph of antrochoanal polyp showing lower inflammatory cells & significantly lower eosinophil infiltrate and oedema is also less. (H&E, x 100)**

#### REFERENCES:

1. Bernstein JM. Update on molecular biology of nasal polyposis. *Otolaryngol Clin N Am* 2005; 38: 1243-55.
2. Larsen PL, Tos M. Origin of nasal polyposis. *Laryngoscope* 1991; 101: 305-12.
3. Batsakis JG, Sneige N. Choanal and angiomatus polyps of the sinonasal tract. *Ann Otol Rhinol Laryngol* 1992; 101: 623-625.
4. Garín L, Miguel Armengot, José Ramón Alba, and Carmen Cardab. Correlations between Clinical and Histological Aspects in Nasal Polyposis. *Acta Otorrinolaringol Esp.* 2008; 59(7): 315-20.
5. Jankowski R, Bouchoua L, Coffinet L, Vignaud JM. Clinical factors influencing the eosinophil infiltration polyps. *Rhinology.* 2002; 40: 173-8.
6. Prades JM, Chelikh L, Dumollard JM, Merzougui N, Timoshenko A, Marti C. Nasal polyposis: Quantification of the eosinophil and granulocyte infiltrates Anatomical-clinical correlations. *Ann Otolaryngol Chir Cervicofac.* 2003; 120: 279-85.
7. Wei JL, Kita H, Sherris A, et al. The chemotactic behaviour of eosinophils in patients with chronic rhinosinusitis. *Laryngoscope* 2003; 113: 303-6.
8. Seiberling KA, Conley DB, Tripathi A, Grammer LC, Shuh L, Haines GK 3rd, et al. Superantigens and chronic rhinosinusitis: detection of staphylococcal exotoxins in nasal polyps. *Laryngoscope.* 2005; 115: 1580-5.
9. Min YG, Chung JW, Shin JS, Chi JG. Histologic structure of antrochoanal polyps. *Acta Otolaryngol* 1995; 115: 543-547.
10. Mygind N. Nasal polyposis. Editorial. *Journal of Allergy and Clinical Immunology.* 1982; 86: 827-9.
11. Stoop AE, van der Heijden HA, Biewenga J, van der BS. Eosinophils in nasal polyps and nasal mucosa: an immunohistochemical study. *J Allergy Clin Immunol* 1993; 91(2): 616-622.
12. Bernstein JM, Kansal R. Superantigen hypothesis for the early development of chronic hyperplastic sinusitis with massive nasal polyposis. *Curr Opin Otolaryngol Head Neck Surg* 2005; 13: 39-44.

## ORIGINAL ARTICLE

13. Simon HU, Yousefi S, Schranz C, et al. Direct demonstration of delayed eosinophil apoptosis as a mechanism causing tissue eosinophilia. *J Immunol* 1997; 158: 3902–3908.
14. Denburg J. Nasal Polyposis: Cytokines and inflammatory cells. In: Mygind N, Lildholdt T (eds). *Nasal polyposis: An inflammatory disease and its treatment*. Copenhagen: Munksgaard, 1997; 78-87.
15. Bachert C, Gevaert P, Holtappels G, Cuvelier C, van Cauwenberge P. Nasal polyps, from cytokines to growth. *American Journal of Rhinology*.2000; 14: 279-90.
16. Rudack C, Stoll W, Bachert C .Cytokines in nasal polyposis, acute and chronic sinusitis. *Am J Rhinol* 1998; 12: 383-388.
17. Bachert C, Van Cauwenberge PB. Inflammatory mechanisms in chronic sinusitis. *Acta Otorhinolaryngol Belg*1977; 51: 209-17.
18. Maldonado Miguel, Asunción Martínez, Isam Alobid, Joaquim Mullol. The antrochoanal polyp. *Rhinology* 2004; 43: 178-182.

### AUTHORS:

1. Ambalika Mondal
2. Satadal Mandal
3. Amit Bikram Maity
4. Shoham Banerjee
5. Indranil Sen
6. Rupam Karmakar

### PARTICULARS OF CONTRIBUTORS:

1. Post Graduate Trainee, Department of Pathology, RG Kar Medical College & Hospital.
2. Assistant Professor, Department of ENT, Midnapore Medical College & Hospital.
3. RMO cum Clinical Tutor, Department of ENT, Midnapore Medical College & Hospital.
4. Senior Resident, Department of ENT, Midnapore Medical College & Hospital.

5. Professor and HOD, Department of ENT, Midnapore Medical College & Hospital.
6. Associate Professor, Department of Pathology, RG Kar Medical College & Hospital.

### NAME ADDRESS EMAIL ID OF THE CORRESPONDING AUTHOR:

Satadal Mandal,  
8/1, Baishnabghata Lane,  
P. O. Naktala,  
Kolkata – 700047.  
E-mail: mandalsatadal@gmail.com

Date of Submission: 17/01/2015.  
Date of Peer Review: 19/01/2015.  
Date of Acceptance: 21/01/2015.  
Date of Publishing: 28/01/2015.