

EPIDEMIOLOGY OF OCULAR INJURY IN PAEDIATRIC POPULATION PRESENTING TO A TERTIARY HEALTH CENTRE

Somnath Das¹, Sandip Samaddar², Parinita Singh³

¹Associate Professor, Department of Ophthalmology, RIO, Medical College, Kolkata.

²Assistant Professor, Department of Ophthalmology, RIO, Medical College, Kolkata.

³Postgraduate Trainee, Department of Ophthalmology, RIO, Medical College, Kolkata.

ABSTRACT

BACKGROUND

Ocular trauma is a worldwide cause of visual morbidity. It includes a spectrum of simple ocular surface foreign bodies, minute corneal abrasions to devastating perforating injuries causing blindness. Children are particularly susceptible to eye trauma. Identification of the cause of injuries among children may help in determining the most effective measures to prevent visual loss. The purpose of this study was to analyse the age and sex distribution, the type of ocular injury, causative agents, and visual status at the time of presentation.

MATERIALS AND METHODS

A total of 100 children (age 0-14 yrs.) who attended Outpatient Department and Emergency of Regional Institute of Ophthalmology, and got admitted were included in the study. Detailed history regarding mode and type of injury, time of injury and time elapsed to attend the hospital from the onset of injury noted. Visual status recorded. Detailed clinical examination done. Appropriate medical and surgical treatment given after assessing the type of injury according to the standard protocol.

RESULTS

Our study showed that male children (Male: Female 2.2:1) in the age group of 6 to 10 years (48%) were affected most. Open globe injury was the commonest type (71 %). 44% of children attended hospital 25 to 48 hours after the injury. Domestic injury with the wood stick was the commonest type. Majority of the children had visual acuity between 2/60 and PL+. 95 children required surgical intervention.

CONCLUSION

We have seen in our study that close supervision at home, school and play ground, public awareness and education regarding the hazardous nature of firecrackers, and road safety measures are critical to prevent the traumatic visual loss in children. Delay in presentation of children to the hospital may lead to substantial damage to the ocular structures during these initial crucial hours.

KEYWORDS

Paediatric Ocular Trauma, Type of Injury, Mode of Injury, Visual Acuity at Presentation, Traumatic Visual Loss.

HOW TO CITE THIS ARTICLE: Das S, Samaddar S, Singh P. Epidemiology of ocular injury in paediatric population presenting to a tertiary health centre. J. Evolution Med. Dent. Sci. 2017;6(55):4133-4137, DOI: 10.14260/Jemds/2017/895

BACKGROUND

Ocular trauma is a worldwide cause of visual morbidity. It includes a spectrum of simple ocular surface foreign bodies, minute corneal abrasions to devastating perforating injuries causing blindness.^{1,2} Children are particularly susceptible to eye trauma; 52% of all eye trauma affects paediatric patients and trauma is the leading cause of monocular blindness in children.³ Children younger than 5 years seem to be more affected, although other series indicate ages 11–15 years are at higher risk due to sport-related trauma particularly in economically developed countries with a male preponderance. In developing countries like India, domestic activities have a more significant role in injury occurrence.^{4,5}

Injuries with sticks, stones, cricket ball, and metallic objects are the most common.^{6,7} Ocular injury occurs in three forms: open globe, closed globe, and adnexal injuries. Open globe injuries are one of the most common emergencies in Ophthalmology clinics and require immediate operation.⁶ Identification of the cause of injuries among children may help in determining the most effective measures to prevent visual loss. Work-related accidents are fairly common in developing countries where children work at a younger age or are bystanders.⁸ Paediatric ocular trauma has a significant impact on the future quality of life as children are exposed to a major risk of amblyopia.⁷

The Ocular Trauma Classification Group has developed a classification system⁹ based on BETT¹⁰ and features of globe injury at initial examination (Birmingham Eye Trauma Terminology System). For evaluation, one has to ascertain quickly the extent of the injury, without risking further damage to the eye, and the need for further sub-specialist consultation.

A visual acuity should be attempted and documented if the child is verbal and conscious. Presence/absence of a relative APD is a very important neuro-ophthalmological sign.^{11,12} If the globe or eyelid are suspected to be lacerated, a shield should be placed on the eye, the patient should be kept

Financial or Other, Competing Interest: None.

Submission 04-05-2017, Peer Review 27-06-2017,

Acceptance 03-07-2017, Published 10-07-2017.

Corresponding Author:

Dr. Sandip Samaddar,

#25, Sarat Chandra Road,

East Barisha,

Kolkata-700008.

E-mail: drsandipsamaddar@gmail.com

DOI: 10.14260/Jemds/2017/895



nil per mouth. With any penetrating or lacerating injury to the eye or adnexa, tetanus immunisation status should be established and revaccination given if indicated. Appropriate radiologic studies should be obtained if orbital fracture, intraocular or intraorbital foreign body, or other intracranial injury is suspected. Chang and Rubin^{13,14} present a very thorough review of eyelid laceration injury and the proper approach to repair. Orbital bony fractures are one of the more commonly encountered findings in children who suffer head and face trauma.¹⁵⁻¹⁸ Grant et al¹⁶ and Egbert et al¹⁷ demonstrate that most of the orbital floor fractures in children are of the trapdoor type. Studies¹⁴⁻¹⁹ in the review period recommend surgical intervention within 5-7 days after the injury in children, versus 2 weeks or longer in adults.

Among paediatric ocular perforation, the most common manifestation was corneal tear.²⁰ C G Thompson Kumar, F A Billson and F Martin showed that the commonest causes of perforating ocular injury were sharp tools (knives/scissors) poked by the child into his/her own eye.²¹ Fireworks are responsible for 4.4% of all injuries and 80% of these are caused by bottle rockets.²² Studies¹⁴⁻¹⁹ in the review period recommend surgical intervention within 5-7 days after the injury in children, versus 2 weeks or longer in adults. Cranial nerve palsies, including third, fourth, and sixth nerves, often are found in conjunction with ocular and head trauma in children.²³ The purpose of this study was to analyse the age and sex distribution, the type of ocular injury, causative agents, visual status at the time of presentation in paediatric ocular trauma at Regional Institute of Ophthalmology, Kolkata, West Bengal.

MATERIALS AND METHODS

A total of 100 children (Age 0-14 yrs.) who attended Outpatient Department and Emergency of Regional Institute of Ophthalmology, and got admitted were included in the study. Detailed history regarding mode and type of injury (Open or Closed type), time of injury and time elapsed to attend the hospital from the onset of injury noted. Visual status recoded with a Snellen acuity chart or a Rosenbaum near card. Detailed clinical examination using standard clinical and investigational procedure done. Closed globe injuries are zoned. Zone I injuries include superficial injuries of the bulbar conjunctiva, sclera, or cornea. Zone II injuries encompass damage to the lens apparatus or structures of the anterior segment. Zone III injuries include damage to the retina, vitreous, posterior uvea (e.g., ciliary body, choroid), and optic nerve. Pupillary reaction noted. Injuries due to chemical, electrical, or thermal agents were not included in this protocol.

This is an institution-based cross-sectional study. Statistical Analysis was performed with help of Epi Info (TM) 3.5.3 which is a trademark of the Centres for Disease Control and Prevention (CDC). Using this software, basic cross-tabulation and frequency distributions were prepared.

Chi-square test was used to test the association between different study variables under study.

Corrected Chi-square test was used in case of any one of cell frequency was found less than 5 in the bivariate frequency distribution.

RESULTS

A total of 100 children (age 0-14 yrs.) who attended Outpatient Department and Emergency of Regional Institute of Ophthalmology, and got admitted were included in the study. The results of the study and the analysis are given below.

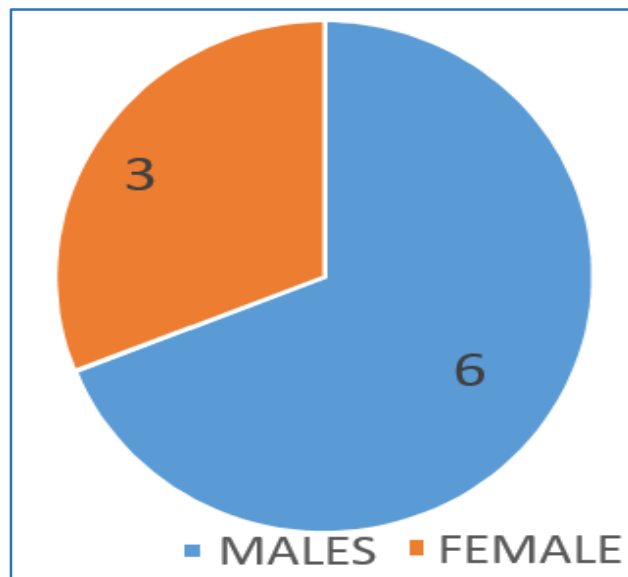


Figure 1. Sex Distribution

Out of 100 children there were 69% males and 31% females. The male: female ratio was 2.2:1.

Age	Number of patients
0-5 Yrs.	33
6-10 Yrs.	48
11-14 Yrs.	19

Table 1. Age Distribution

Majority of the children who suffered injury were of age group between 6-10 yrs., constituting 48% of the injuries. This was followed by age between 0-5 yrs. which was 33%. The age group between 11-14 yrs. had the least number of children amounting to 19%.

Type of Injury	Number of Patients
Open Globe Injury	71
Closed Globe Injury	13
Adnexal Injury	13
Chemical Injury	03

Table 2. Type of Injury

The injuries were classified as open globe, closed globe, adnexal and chemical injuries. 71% of the injuries were open globe followed by closed globe (13%). Adnexal injuries constituted 13% of the injuries and 3% chemical injuries.

Causative Agents	Number of Patients
Stick	12
Brick/Stone	06
Scissors/Knife	12
Glass Piece	06
Firecracker	05
Finger nail	05
Needle/Pin	05
Ball	05
Toy	05
Scale	04
Caterpillar Hair	04
Pencil	04
Lime Injury	03
Bird Beak	03
Iron Nail	05
Others	17

Table 3. Causative Agents of Injury

The most common mode of injury in these children was by stick, wooden stick was most commonly implicated followed by bamboo stick and jute stick. Out of the 12 injuries caused by stick, 10 were open globe type and 2 were closed globe type. 12 out of 100 injuries were due to scissors and knife. 10 of these were open globe injuries whereas 2 were adnexal injuries. 6 out of 100 injuries were caused by brick and stone; 3 of these injuries were open globe type, 2 were superficial foreign body and 1 was adnexal injury.

Another common mode of injury was by glass piece. 4 of these injuries were open globe type and 2 were adnexal injuries. Firecrackers caused 5 out of 100 injuries and all were open globe type. 5 injuries were due to ball and 4 out of these injuries were closed globe injuries. 4 of the children presented with closed globe injury due to caterpillar hair. Other modes of injury were needle, pin, scale, toys, bird beak, pencil, iron nail, goat or cow horn, hammer, blouse hook.

Visual Acuity	Number of patients
6/6-6/12	07
6/18-6/36	07
6/60-3/60	17
2/60-PL+	37
NO PL	05
Couldn't be assessed	27

Table 4. Visual Acuity at Presentation

37% of the children who presented to us had visual acuity between 2/60 and PL (Perception of light) +. In 27% of the children, the visual acuity couldn't be assessed as many a times younger children don't cooperate. 17% had visual acuity between 6/60-3/60. 7% of the patients had vision between 6/18-6/36. Another 7% had vision between 6/6-6/12. PL was denied in 5% patients.

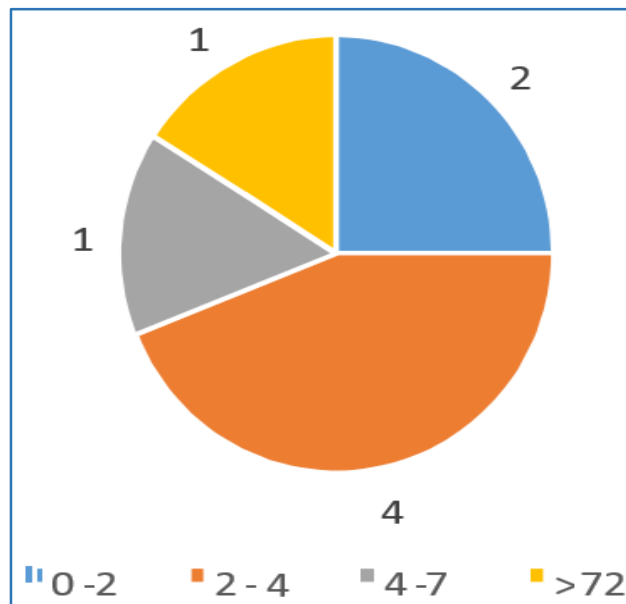


Figure 2. Time Interval between the Time of Injury to Hospitalisation

Majority (44%) of the children who suffered ocular trauma presented to our hospital between 25-48 hrs. of injury, 15% presented between 49-72 hrs. and 16% presented after 72 hrs. Only 25% of the patients presented within the first 24 hrs. I also noted that majority of the injuries occurred during the day while playing unsupervised. Most of the injuries occurred at or near home.

Time	Number of Patients
0-24 hrs.	88
>24 hrs.	7

Table 5. Time Interval between Hospitalisation and Surgery

Conservative Management 5

88 out 100 patients who were hospitalised were operated within the first 24 hours. 7 patients were operated after 24 hours and 5 did not require surgery. Out of the 5 patients who were conservatively managed, 3 were chemical injury patients and 2 were closed globe injuries presenting with hyphaema.

DISCUSSION

Children with immature motor skill and their tendency to imitate adult behaviour without evaluating risks is an important mode of injury (Thordarson pelting, civilian unrest 2010, U, Ragnasson AT et al).⁷ Serious ocular trauma gives rise to irrevocable structural damage or functional loss which imposes an enduring burden throughout the most productive years of life (Robert JC).⁸

In our study, out of 100 children, there were 69% males and 31% females. The male: female ratio was 2.2:1. Our results were consistent with a study conducted in Rajendra Prasad Centre for Ophthalmic Sciences by Saxena R et al.²⁴ Out of 204 children aged fourteen years or less, there were 133 (65.1%) boys and 71 (34.9%) girls.

Another study, Pattern of Paediatric Ocular Trauma in Hayatabad Medical Complex, Peshawar by Tariq Farooq Babar et al²⁵ found male to female ratio as 3.3:1. In our study, we have found that majority of the children who suffered injury were of age group between 6-10 yrs. (48%). This was followed by age between 0-5 yrs. (33%). The age group between 11-14 yrs. had the least number of children (19%). This result was consistent with the study of Pattern of Paediatric Ocular Trauma in Hayatabad Medical Complex, Peshawar by Tariq Farooq Babar et al. In our study, 71% of the injuries were open globe followed by closed globe (13%). Adnexal injuries constituted 13% of the injuries and 3% chemical injuries. In a study conducted in Rajendra Prasad Centre for Ophthalmic Sciences, by Saxena R et al 214 children aged 14 years or less presenting to the emergency with ocular injury were included. Majority of injuries occurred in children of 5 years and older (87.7%). Closed globe injuries being 42.2%, open globe injuries 53.9% and 3.9% were chemical injuries. In our study, we only included the children who required hospitalisation; therefore, the number of open globe injuries was much more as compared to other injuries.

The most common mode of injury in these children was by stick (12%), injury by household items like scissors and knife (12%). Others were glass piece (6%), firecracker (5%), finger nail (5%), needle/pin (5%), ball (5%), toy (5%), scale (4%), caterpillar hair (4%), pencil (4%), bird beak (3%), iron nail (5%), all the chemical injuries were due to lime (3%). Few other modes of injuries were due to goat or cow horn, hammer, blouse hook, etc. Sports related objects like bat, ball, hockey result in injuries in 10 patients (6.53%), firecrackers result in 2 patients (1.30%). Majority (75%) of the children who suffered ocular trauma presented to our hospital after 24 hrs. of injury. Only 25% of the patients presented within the first 24 hrs. In a study conducted in Rajendra Prasad Centre for Ophthalmic Sciences, by Saxena R et al, 49 (24%) cases presented within 6 hours of injury while 70 (34.3%) presented after more than 24 hours after trauma. Major reasons for delayed presentation to our hospital were poor communication and lack of awareness amongst parents about the seriousness of ocular injuries. We noted that 3% of the patients who presented with endophthalmitis had presented after 72 hrs. of injury. 88 out of 100 patients who were hospitalised were operated within the first 24 hours. There was a delay of more than 24 hrs. in 7 out of 100 cases, the delays occurred due to unavailability of anaesthetist which was the another limiting factor.

CONCLUSION

The most common aspect of paediatric ocular trauma is prevention. Our study points to male children of school going age as the high-risk group and the outdoor activities as the high-risk sites for ocular injuries.

We have seen in our study that close supervision at home, school and play ground, public awareness and education regarding the hazardous nature of firecrackers, and road safety measures are critical to prevent the traumatic visual loss in children. Legislation to ban the use of firecrackers by children would help in saving many eyes. Delay in presentation of children to the hospital may lead to substantial damage to the ocular structures during these initial crucial hours. Improvement of rural health services is

very much needed and it is important to provide them with facilities and equipment necessary for urgent management of ocular trauma.

REFERENCES

- [1] Desai P, MacEwen CJ, Baines P, et al. Incidence of cases of ocular trauma admitted to hospital and incidence of blinding outcome. *Br J Ophthalmol* 1996;80(7):592-6.
- [2] Ngo CS, Leo SW. Industrial accident-related ocular emergencies in a tertiary hospital in Singapore. *Singapore Med J* 2008;49(4):280-5.
- [3] Jandeck C, Kellner U, Bornfeld N, et al. Open globe injuries in children. *Graefes Arch Clin Exp Ophthalmol* 2000;238(5):420-6.
- [4] Oiticica-Barbosa MM, Kasahara N. Eye trauma in children and adolescents: perspectives from a developing country and validation of the ocular trauma score. *J Trop Pediatr* 2015;61(4):238-43.
- [5] Chakraborti C, Giri D, Choudhury KP, et al. Paediatric ocular trauma in a tertiary eye care center in Eastern India. *Indian J Public Health* 2014;58(4):278-80.
- [6] MacEwen CJ. Ocular injuries. *J R Coll Surg Edinb* 1999;44(5):317-23.
- [7] Ervin-Mulvey LD, Nelson LB, Freeley DA. Pediatric eye trauma. *Pediatr Clin North Am* 1983;30(6):1167-83.
- [8] Umeh RE, Umeh OC. Causes and visual outcome of childhood eye injuries in Nigeria. *Eye (Lond)* 1997;11(Pt 4):489-95.
- [9] Pieramici DJ, Sternberg P, Aaberg TM, et al. A system for classifying mechanical injuries of the eye (globe). The ocular trauma classification group. *Am J Ophthalmol* 1997;123(6):820-31.
- [10] Kuhn F, Morris R, Witherspoon CD, et al. A standardized classification of ocular trauma. *Ophthalmology* 1996;103(2):240-3.
- [11] De Juan E, Sternberg P, Michels RG. Penetrating ocular injuries. Types of injuries and visual results. *Ophthalmology* 1983;90(11):1318-22.
- [12] Joseph E, Zak R, Smith S, et al. Predictors of blinding or serious eye injury in blunt trauma. *J Trauma* 1992;33(1):19-24.
- [13] Chang EL, Rubin PA. Management of complex eyelid lacerations. *Int Ophthalmol Clin* 2002;42(3):187-201.
- [14] Hogg NJ, Horswell BB. Soft tissue pediatric facial trauma: a review. *J Can Dent Assoc* 2006;72(6):549-52.
- [15] Kwon JH, Moon JH, Kwon MS, et al. The differences of blowout fractures of the inferior orbital wall between children and adults. *Arch Otolaryngol Head Neck Surg* 2005;131(8):723-7.
- [16] Grant JH 3rd, Patrinely JR, Weiss AH, et al. Trapdoor fracture of the orbit in a pediatric population. *Plast Reconstr Surg* 2002;109(2):482-9.
- [17] Egbert JE, May K, Kersten RC, et al. Pediatric orbital floor fracture: direct extraocular muscle involvement. *Ophthalmology* 2000;107(10):1875-9.
- [18] Bansagi ZC, Meyer DR. Internal orbital fractures in the pediatric age group: characterization and management. *Ophthalmology* 2000;107(5):829-36.
- [19] Burnstine MA. Clinical recommendations for repair of isolated orbital floor fractures: an evidence-based analysis. *Ophthalmology* 2002;109(7):1207-10.

- [20] Krishnan M, Sreenivasan R. Ocular injuries in union territory of Pondicherry-clinical presentation. *Indian J Ophthalmol* 1988;36(2):82-5.
- [21] Brophy M, Sinclair SA, Hostetler SG, et al. Pediatric eye injury- related hospitalizations in the United States. *Pediatrics* 2006;117(6):e1263-71.
- [22] Kuhn FC, Morris RC, Witherspoon CD, et al. Serious fireworks- related eye injuries. *Ophthalmic Epidemiol* 2000;7(2):139-48.
- [23] Holmes JM, Mutyala S, Maus TL, et al. Pediatric third, fourth, and sixth nerve palsies: a population-based study. *Am J Ophthalmol* 1999;127(4):388-92.
- [24] Saxena R, Sinha R, Purohit A, et al. Rajendra Prasad centre for ophthalmic sciences, all India institute of medical sciences, New Delhi, India. *Indian J Pediatrics* 2002;69(10):863-7.
- [25] Babar TF, Jan S, Gul L, et al. Pattern of paediatric ocular trauma in Hayatabad medical complex, Peshawar. *Pak J Med Res* 2006;45:6-9.