

CASE REPORT

GIANT FIBROADENOMA MIMICKING PHYLLOIDES TUMOR: A RARE OCCURRENCE IN A POSTMENOPAUSAL FEMALE

Monika Bansal¹, Anureet Kaur², Jasbir Singh³, Puneet Kaur⁴

HOW TO CITE THIS ARTICLE:

Monika Bansal, Anureet Kaur, Jasbir Singh, Puneet Kaur. "Giant Fibroadenoma Mimicking Phylloides Tumor: A Rare Occurrence in a Postmenopausal Female". Journal of Evolution of Medical and Dental Sciences 2015; Vol. 4, Issue 35, April 30; Page: 6148-6152, DOI: 10.14260/jemds/2015/895

ABSTRACT: OBJECTIVE: Fibroadenomas are the most common solid lesions of the breast. They typically present as firm, mobile, painless, easily palpable breast nodules. Fibroadenomas measuring 5 cm or more in diameter are considered as giant fibroadenomas which can grow to huge proportions and compress the surrounding normal breast tissue. They can occur in any part of reproductive life of female but are more common before the age of 30 years. **CASE REPORT:** we report a rare case of Giant fibroadenoma in a postmenopausal female of 52 yr of age. The diagnosis was made on fine needle aspiration cytology and was subsequently confirmed on histopathology. **CONCLUSION:** Fibroadenoma is an estrogen induced benign tumor common in young female, but in our case it occurred in postmenopausal female, even without any documented estrogen therapy.

KEYWORDS: Giant fibroadenoma, Phylloides tumour, Benign.

INTRODUCTION: Giant fibroadenoma is defined as tumour measuring 5 cm or more in diameter or disproportionately large compared to the rest of the breast.^[1,2] They may be either adult type or juvenile type.^[3] The terms 'Juvenile fibroadenoma' and 'Giant fibroadenoma' have been used by different authors to describe separate lesions. However, it must be noted that the distinction between the two entities is extremely difficult as juvenile fibroadenomas may attain great size, while some authors consider them to be a variant of giant fibroadenoma. Juvenile giant fibroadenoma constitute 0.5-4 % of all fibroadenomas.^[4] It is more frequently seen in young and black females and is an oestrogen induced benign tumour, which develops during adolescence. Pregnancy and lactation are growth stimulants, whereas regression is seen after menopause. These tumours may occur in postmenopausal women receiving oestrogen replacement therapy.^[5]

There have not been many studies evaluating risk factors for development of fibroadenomas. Rarely, racial^[6] or familial predisposition may play a role.^[7] Use of oral contraceptives,^[8,9] high Quetelet index and high number of full-term pregnancies^[10] have been shown to reduce fibroadenoma risk, but exogenous oestrogen replacement therapy may increase risk^[8] although not all studies agree on this.^[10]

CASE REPORT: A 52 years old lady presented with lump in right breast. The lump was noticed around 6 years back in the form of small nodule, which increased progressively in size with a rapid enlargement in last 6 months before presentation to the outpatient department. There was no history of trauma, nipple discharge, fever, anorexia or weight loss. There was no significant family history. On clinical examination, huge enlargement of right breast was found, with presence of a lump measuring about 15x10 cm, while other breast was normal. The overlying skin showed distended veins. It was a firm to hard mass, not fixed to underlying structures and nipple and areola. A clinical diagnosis of Cystosarcoma Phylloides was made. There was no axillary lymph node enlargement. Routine

CASE REPORT

haematological and biochemical examination were within normal limits. Ultrasonography of the mass showed heterogenous parenchymal pattern, suggestive of fibroadenoma.

The patient was subjected to fine-needle aspiration cytology (FNAC). The cytology smears showed monolayered sheets of benign ductal epithelial cells with few myoepithelial cells in a background of bare nuclei and blood (Figure 1). Only few stromal fragments were seen and hence, a diagnosis of giant fibroadenoma was given. The patient underwent total excision of right breast lump along with nipple and areola. The excised lump was encapsulated, measured 15 cm x13 cm and weighed 600 gms. Cut surface showed multiple gray white nodules (Figure 2). Histopathological examination showed proliferation of benign glandular and stromal tissue, forming intracanalicular and pericanalicular pattern of growth (Figure 3). Hence a diagnosis of giant fibroadenoma was made. Positive nuclear staining for estrogen and progesterone receptor antibodies was demonstrated by immunohistochemical study. Postoperative recovery was uneventful and the patient is on regular follow up since last 6 months.

DISCUSSION: The nomenclature of fibroadenoma is confusing and a plethora of names exists to designate the lesion such as age related term juvenile fibroadenoma and size related term giant or massive fibroadenoma.^[4] According to Stanford School of Medicine, juvenile fibroadenomas of the breast may be multiple and is defined as a circumscribed, often large, breast mass occurring in adolescent females with stromal and epithelial hypercellularity, but lacking leaf like growth pattern of Phylloides tumours. The age distribution ranges from the early teens to over 70 years, with a mean age of about 30 years.^[11] Less than 5% of women with a fibroadenoma are post-menopausal.

Giant fibroadenomas comprise approximately 4% of all fibroadenomas and present as rapidly growing unilateral macromastia without definable borders or texture differences. It is more frequently seen in young and black female.^[4] In our case the patient was postmenopausal and 52 years old. The tumour measured 15x13 cms in this patient.

These are benign tumors, but their rapid growth and large size together with their rarity may lead to difficulties in the clinical approach. In our case the patient had a history of rapid enlargement of the mass in 6 months.

Increased oestrogen stimulus and receptor sensitivity and a decrease in oestrogen antagonist levels during puberty are thought to be responsible for the etiology.^[12] However, in our case the patient was not receiving hormone replacement therapy or exogenous oestrogen in any form.

Other than Giant fibroadenomas, a wide variety of breast conditions can result in solitary or multiple giant masses such as phylloides tumour, virginal hypertrophy, lipoma, hamartoma, cyst, abscess and carcinoma.^[13] Clinical examination is essential in evaluating the location, size and number of palpable lesions. It is also important to distinguish these pathological entities preoperatively as the treatment modalities and the prognosis differ quite significantly in these conditions.

One of the most important differential diagnoses in this case was cystosarcoma phylloides, especially because of its age incidence. It forms large, lobulated, homogeneous solid tumour mass with well defined margins. These are mostly benign (95%) tumours, which are seen in the 4th decade.^[12] Although these tumours are morphologically similar to fibroadenomas, phylloides tumours are not really encapsulated. Compared to fibroadenoma, phylloides tumours show overgrowth of the stromal compartment which shows increased cellularity, especially in the

CASE REPORT

periductal stromal areas. Mitotic activity is also substantial and epithelial clefts are more elongated in phyllodes tumours. It is treated by wide excision with a margin of normal tissue or mastectomy.

An unusual example of fibrous tumour of the breast has been reported in a 62 year old postmenopausal female with history of progressive enlargement in one year.^[14] The patient had history of exogenous estrogen intake for 10 years which was associated with accelerated growth of the tumour and showed positive nuclear staining for estrogen receptor antibodies in stromal cells. Fibrous tumour of the breast is a rare, benign stromal proliferation with atrophy of the epithelial component.

Breast carcinomas are typically large masses with irregular borders, associated with features like dimpling or thickening of skin, inverted nipple and discharge from nipple. None of these features was seen in this case.

CONCLUSION: Fibroadenoma 5 cm or more in diameter is considered as giant fibroadenoma and is a common cause of asymmetrical breast enlargement in adolescent and young adult females. However, its incidence in postmenopausal female is not documented. The only known cause is oestrogen replacement therapy which causes breast to enlarge. In our case, no such evidence of exogenous oestrogen was present.

REFERENCES:

1. Ragannoonan C, Fairbain JK, Williams S et al. Giant breast tumours of adolescence. *Aust NZ J Surg* 1987; 57: 243-247.
2. Bauer BS, Jones KM, Talbot CW. Mammary mass in the adolescent female. *Surg Gynecol Obstet* 1987; 165: 63-65.
3. Nikumbh DB, Desai SR, Madan PS et al. Bilateral giant fibroadenomas of breast: A case report. *Patholog Res Int* 2011: 482046.
4. Rattan K, Kumar S, Dhull AK et al. Giant Fibroadenoma mimicking Phyllodes Tumor in a Young Female: A Cytological Dilemma. *The Internet Journal of Third World Medicine* 2008; 6: 2.
5. Smal J. Large fibroadenoma mimicking malignancy. *Sa J Radiology* 2004: 44.
6. Oberman HA. Hormonal contraceptives and fibroadenomas of the breast. *N Engl J Med* 1971; 284: 984.
7. Morris JA, Kelly JF. Multiple bilateral breast adenomata in identical adolescent negro twins. *Histopathology* 1982; 6: 539-547.
8. Canny PF, Berkowitz GS, Kelsey JL. Fibroadenoma and the use of exogenous hormones. *Am J Epidemiol* 1988; 127: 454-461.
9. Li Volsi V, Stadel BV, Kelsey JL. Fibroadenoma in oral contraceptive users. A histopathologic evaluation of epithelial atypia. *Cancer* 1979; 44: 1778-1781.
10. Yu H, Rohan TE, Cook MG. Risk factors for fibroadenoma: a case-control study in Australia. *Am J Epidemiol* 1992; 135: 247-258.
11. Foster ME, Garrahan N, Williams S. Fibroadenoma of the breast: a clinical and pathological study. *J R Coll Surg Edinb* 1988; 33: 16-19.
12. Marchant DJ. Benign breast disease. *Obstet Gynecol Clin North Am* 2002; 29: 19-34.
13. Muttarak M, Chaiwun B. Imaging of giant breast masses with pathological correlation. *Singapore Med J*. 2004; 45(3): 132-139.

CASE REPORT

14. Miyagawa A, Yuba Y, Haga H et al. Fibrous tumor of the breast in a postmenopausal woman receiving estrogen. *Pathol International* 2001; 51: 123–126.

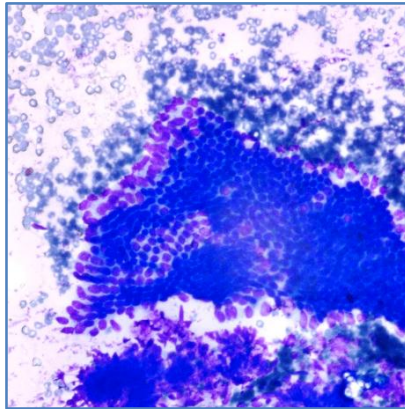


Fig. 1: Cytological smears showing monolayered sheets of benign ductal epithelial cells along with myoepithelial cells in the background of blood. (MGG, 40x)

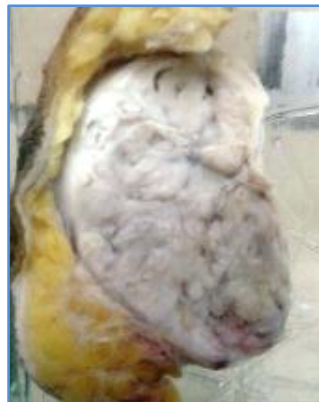

Fig. 2: Specimen of Encapsulated breast lump showing multiple grey white nodules

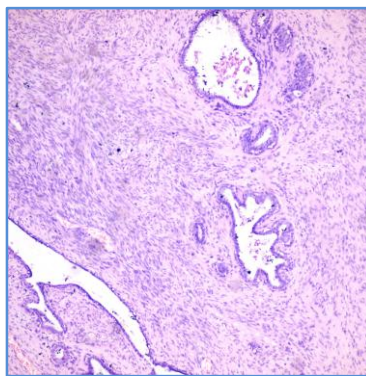


Fig. 3: Histopathology sections showing proliferation of glandular and stromal cells forming mainly paracanalicular pattern. (H & E, 10x)

CASE REPORT

AUTHORS:

1. Monika Bansal
2. Anureet Kaur
3. Jasbir Singh
4. Puneet Kaur

PARTICULARS OF CONTRIBUTORS:

1. Assistant Professor, Department of Pathology, Gian Sagar Medical College & Hospital, Banur.
2. Professor, Department of Pathology, Gian Sagar Medical College & Hospital, Banur.
3. Professor, Department of Pathology, Gian Sagar Medical College & Hospital, Banur.

FINANCIAL OR OTHER

COMPETING INTERESTS: None

4. Assistant Professor, Department of Pathology, Gian Sagar Medical College & Hospital, Banur.

NAME ADDRESS EMAIL ID OF THE CORRESPONDING AUTHOR:

Dr. Monika Bansal,
302, Marigold Tower,
Mayfair Apartments,
Sector 70, Mohali, Punjab.
E-mail: monika_bansal78@yahoo.com

Date of Submission: 08/04/2015.
Date of Peer Review: 09/04/2015.
Date of Acceptance: 22/04/2015.
Date of Publishing: 30/04/2015.