

ASSESSMENT AND COMPARISON OF ABDOMINAL MASSES BY SONOGRAPHY AND COMPUTED TOMOGRAPHY

Suman Bhagat¹, Neelam Gauba², Sohan Singh³, Arvinder Singh⁴, G.B.S. Mahal⁵

HOW TO CITE THIS ARTICLE:

Suman Bhagat, Neelam Gauba, Sohan Singh, Arvinder Singh, G.B.S. Mahal. "Assessment and Comparison of Abdominal Masses by Sonography and Computed Tomography". Journal of Evolution of Medical and Dental Sciences 2014; Vol. 3, Issue 01, January 06; Page: 84-94.

ABSTRACT: OBJECTIVES: To study the role of ultrasonography and computed tomography in the evaluation of abdominal masses, to compare their diagnostic accuracies, to evaluate the imaging features of lesions and to know the exact site of origin and extension into surrounding structures. **MATERIALS AND METHODS:** A prospective study of 104 patients with abdominal masses. USG was done with Toshiba SSA and Philips Envisor C machine and CT-Scan examination was performed in all patients on Philips brilliance 6-slice whole body CT scanner. **RESULTS:** There were 35(30.62%) cases of hepatobiliary masses, renal 15(14.40%) cases, pancreatic 7(6.72%) cases, 5(4.80%) cases of splenic masses and 30(28.82%) cases of pelvic masses. 8 cases with other abdominal masses. Hepatic SOL were detected in 6(5.76%) and 8(7.69%), 5(4.80%) cases of gall bladder masses and 4(3.85%), Omental caking was seen in 2(1.92%) cases and 4(3.85%), calcification was seen in 2(1.92%) cases and 4(3.85%) cases, renal calculi were seen in 4(3.84%) cases and 6(5.77%) cases, on sonography and CT examination. Peritoneal deposits were seen in 3(2.88%) cases of ovarian carcinoma and unknown malignancy on US and in 5(4.88%) cases on CT. Ascites and lymphadenopathy was more accurately detected on CT as compared to US. CT detected splenic infarcts which were missed on ultrasonography. **CONCLUSION:** CT is more sensitive in evaluation of site and size of lesion, detection of calcification, adjacent organ infiltration and regional lymphadenopathy. The limitations of CT are ionizing radiation, high cost and contrast administration. Hence ultrasound should be the primary screening modality and CT should be used for further characterizing the masses.

KEYWORDS: Abdominal Masses, Sonography, Computed Tomography.

INTRODUCTION: An abdominal mass is any localized enlargement or swelling in the human anatomy. Depending on its location, the abdominal mass may be caused by an hepatomegaly, splenomegaly, a pancreatic mass, a retro peritoneum, an abdominal aortic aneurysm or various tumors, such as those caused by abdominal carcinomatosis and omental metastasis.¹

Ultrasonography is still the baseline investigation of choice in the initial diagnosis of the abdominal masses. Computed Tomography improves the accuracy of the primary findings of sonography with exact localization and origin of site of abdominal mass.² It also helps in determining the nature of lesion whether solid or cystic.³

Various signs and symptoms encountered with abdominal masses are pain in abdomen, awareness of mass, fever, dysuria, hematuria, jaundice, weight loss, bowel disturbance & menstrual irregularities etc. Modalities used for the investigation of abdominal masses are Plain X-Ray Abdomen which identifies only soft tissue shadow or any calcification if present; IVP used for evaluating renal masses, Barium studies for gastrointestinal masses, Ultrasonography, Computed Tomography and MRI.

ORIGINAL ARTICLE

Sonography is a unique real time imaging which is multiplanar, operator dependent, without radiation exposure and is a low cost modality. The limitation of sonography is the presence of bowel gas and excessive obesity. Ultrasounds do not accurately reflect the full extent of disease and is also limited in diagnosis of metastasis to peritoneum and lymph nodes.^{3,4,5} Transvaginal sonography is very useful in uterine and adnexal masses. Transrectal sonography is helpful in rectal and prostatic masses.

CT scanner became a clinical reality in the early 1970's. In 1979, Cormack shared the Nobel Prize in Medicine and Physiology with Hounsfield for the development of computed tomographic scanning as the clinical realization of projection imaging.⁴

Computed tomography is superior to sonography in diagnosis and management of abdominal masses. The exact origin of mass, size, shape and localization can be done with CT. Contrast enhanced CT scan helps in better localization, determining exact size of mass and degree of vascularity of the mass. Abdominal lymphadenopathy can also be better assessed.⁶ Presence of bowel gas and obesity does not have any hindrance in detection of the abdominal lesions in comparison to sonography. The disadvantages of computed tomography are high cost, ionization radiation and motion artifacts.⁷

Threasa et al reviewed 13 children with Wilm's tumor with ultrasound and CT to determine the ability of each imaging test to characterize the tumor and determine its extent. US study was less accurate than CT scanning in its ability to detect perinephric extension, lymph node involvement, and bilateral tumor. US was recommended as the initial screening test in the evaluation of an abdominal mass and CT for better determination of the extension of suspected tumor, enabling correct diagnosis in 77% while US was correct in only 23%.²

Raskin MM showed that pelvic US can distinguish cystic from solid masses but is poor in defining tissue plane. CT easily detects calcifications, is rarely affected by overlying bowel gas and usually demonstrates the mass with good definition tissue plane.³

Hatimota P et al performed a study on 50 patients with renal masses and evaluated them on US and CT to stage these tumors and correlate the imaging findings with operative and histopathological findings. US had an advantage over CT in detection of nature of lesion (solid/cystic) and evaluation of renal vein invasion.⁵

Tevfik et al reported a case with incidental left retroperitoneal mass discovered on ultrasound. CT revealed the extent of tumor, organ of origin, regional invasion, vascular encasement, adenopathy and calcification.⁶

Pablo R Ras et al reviewed acute pancreatitis on US, CT, MRI abdomen with or without contrast. US was found to be effective to detect GB stones in patients with acute pancreatitis, but less successful in diagnosing choledocholithiasis. CT is superb in delineating the pancreas and acute pancreatitis associated abnormalities.⁷

Elshazly et al reported 4 cases who were suffering from abdominal pain and GIT manifestations. A provisional diagnosis of hydatid disease was made based on clinical manifestation, hematological, biochemical parameter and serological test. US showed well circumscribed cystic masses in liver and diagnosis of hydatid cysts was confirmed by CT.⁸

Lt Col George RA et al did a study on 50 cases of GB carcinoma on abdominal helical computed tomography scan. The presence of focal or diffuse mass lesions in the gall bladder fossa, infiltration of liver and second part duodenum was the most reliable diagnostic features in

ORIGINAL ARTICLE

carcinoma gallbladder. Regional spread was better delineated on CT and was an effective method for evaluating, characterizing and detecting the spread of GB carcinomas.⁹

Sayed et al reviewed the case record of 120 patients who underwent CT scan for 2 years. US was used as a screening test for suspicious hepatic tumors. CT was found to be the mainstay imaging modality of first choice in diagnosis of hepatic malignancies.¹⁰

Ariadne et al did a study on 26 patients with masses in GB or GB fossa and emphasizes the limitations of ultrasonography. Sonography is reliable in the detection of a primary gall bladder mass. However, sonographic findings do not accurately reflect the full extent of disease, particularly in the diagnoses of metastases to the peritoneum and lymph nodes.¹¹

Sandhu MS et al undertook this study in 21 patients with clinical suspicion of ovarian neoplasm, all of them were evaluated by US and CT. CT proved to be superior for evaluating extra pelvic disease primarily because of its ability to detect omental/ peritoneal deposits.¹²

Jean Noel et al studied 130 patients with epithelial ovarian tumors prospectively on CT and US. The overall accuracy of characterization of benign vs. malignant tumors was 94% with CT and 80% with sonography.¹³ Mathis et al studied 11 patients with various extra hepatic right upper quadrant lesions had findings on CT that strongly suggested intrahepatic location.¹⁴ Herbert L. et al studied the accuracy of CT and US in 112 patients with suspected adrenal disease and strongly supported the diagnostic superiority of CT.¹⁵

Samuel J et al did a prospective study to assess the relative efficacy of CT and US in detecting and identifying pancreatic lesions. They concluded that CT is the method of choice for detecting a pancreatic lesion, assessing its extent and defining its etiology.¹⁶

AIMS AND OBJECTIVES: To evaluate the role of Ultrasound and CT in abdominal masses, characterize the morphology of lesion, solid versus cystic and to know the exact site of origin and extension into surrounding structures.

MATERIAL AND METHODS: This study on the role of Ultrasonography and Computed tomography in evaluation of abdominal masses was conducted on 104 consecutive patients presenting with abdominal masses. Case selection was done from patients referred to department of radiodiagnosis from indoor and outdoor departments of Guru Nanak Dev Hospital & Shri Guru Teg Bahadur Hospital of Government Medical College, Amritsar.

The sonographic evaluation and CT examination was carried out using a real time scanner (Philips Envisor-C) and Philips brilliance 6-slice whole body CT scanner.

Ultrasonic evaluation was done in detail for site of origin of mass, its nature whether solid or cystic, echo texture and echogenicity. Associated findings in the abdomen were also recorded.

CT-Scan examination was performed in all patients on Philips brilliance 19T 6-slice whole body scanner after giving oral and intravenous contrast as and when required. The Scan was done with 10mm thick slices with 10mm intervals. The axial scans with coronal and sagittal reformatting were done as and when required.

RESULTS: A prospective study of 104 patients was conducted to study and evaluate radiologically by ultrasonography and computed tomography in patients with abdominal masses. Role of ultrasound and CT was studied in defining nature and extent of lesions. The main observations of this study were as follows.

ORIGINAL ARTICLE

There were 35(30.62%) cases of hepatobiliary masses, renal 15 (14.40%) cases, pancreatic 7(6.72%) cases, 5(4.80%) cases of splenic masses and 30(28.82%) cases of pelvic masses. 8 cases with other abdominal masses. Hepatic SOL were detected in 6(5.76%) and 8(7.69%), 5(4.80%) cases of gall bladder masses and 4(3.85%), Omental caking was seen in 2(1.92%) cases and 4(3.85%), calcification was seen in 2(1.92%) cases and 4(3.85%) cases, renal calculi were seen in 4(3.84%) cases and 6(5.77%) cases, on sonography and CT examination. Peritoneal deposits were seen in 3(2.88%) cases of ovarian carcinoma and unknown malignancy on US and in 5(4.88%) cases on CT. Ascites and lymphadenopathy was more accurately detected on CT as compared to US. CT detected splenic infarct which were missed on ultrasonography.

DISCUSSION: Out of 104 patients, Maximum no. of patients was in age group of 51-60 years (25.96%) and the minimum number was in the age group of 0-10 years (3.84%). The oldest patient was 86 years old female. Male and female populations contributed 50.96% & 49.03% respectively.

The most of the patients (64.42%) presented with history of pain abdomen. Abdominal mass was seen in 9.60% of cases. Distension of abdomen was seen in 14.42% of cases. Bowel symptoms were seen in 5.70% of cases and urinary symptoms were seen in 7.69% of cases.

Masses of hepatobiliary origin were maximum in number 35(30.62%) patients. 15(14.40%) cases of renal masses, 7(6.72%) cases of pancreatic masses, 5(4.80%) case of splenic masses and 30(28.82%) cases of pelvic masses. Twelve were the other masses which included gut masses, adrenal mass and lymph node masses. Out of 104 cases, 70(67.3%) of cases had solid masses, 23(22.11%) cases had cystic masses, out of which 9 masses were predominantly cystic and 2 masses were predominantly solid on ultrasonography. Cystic masses on US were smoothly marginated, had well defined margins, echo free, without septations and gave distal acoustic shadowing. Whereas cystic masses which had thick septations, coarse echoes and solid components but had good through transmission confirming their cystic nature were predominantly solid masses. On CT, 70(67.30%) of cases had solid masses and showed contrast enhancement. 24(23.08%) of cystic masses were hypodense with 4-18HU showing no contrast enhancement. Out of 104 masses, 65(62.05%) were showing homogenous pattern and 39(37.05%) showed heterogeneous pattern. Splenic infarct and contusion in two cases was diagnosed on CT whereas these lesions were missed on ultrasonography.

Hydatid disease was detected in 4 cases in liver and in one case in kidney. On ultrasound, lesions were seen as well marginated, multiloculated with interspersed solid hypoechoic masses in two cases and multiseptated in 2 cases out of which one case showed marginal calcification. On CT, the cysts appeared as sharply marginated, round or oval masses of fluid density, well demarcated from adjacent liver parenchyma. CT helped in one case to show the rupture of hydatid cyst and its extension into the right pleural cavity and dissemination into peritoneal cavity. Dissecting aneurysm was detected in a case on US; it was seen as hypoechoic lesion adjacent to aorta with intimal flap separating aneurysm. CT was superior in this case to demonstrate the site of dissection and extent of dissection up to iliac vessels.

REFERENCES:

1. Das S. Examination of abdominal lump. A manual on clinical surgery; 6th ed. 2007; p 387-97.
2. Threasa AHR, Marilyn JS, Gary DS. Wilms Tumor in children: Abdominal CT and US Evaluation. Radiology 1986; 160: 501-5.

3. Raskin MM. Combination of CT and US in the retro peritoneum and pelvic examination; Crit Rev Diagn. Imaging, 1980, 13(3): 173-228.
4. Hendee WR. Cross Sectional Medical Imaging: A History. Radiographics 1989; 9: 1155-80.
5. Hatimota P, Vashisht S, Aggarwal K, Kapoor V, Gupta NP. Spectrum of US and CT findings in Renal neoplasm with pathological correlation. Ind J Radiol Imag 2005; 15(1): 117-25.
6. Tevfik A, Mustafa K, Ufuk U, İrfan HA, Osman İ. Retroperitoneal ganglioneuroma. Fak Derg 2009; 26(2): 163-65.
7. Pablo RR, Robert LB, Dennis F, Spencer BG, Seth NG, Jay PH. ACR appropriate criteria-Acute Pancreatitis-2006: 1-5.
8. Elshazly A, Manar SA, Samar NE, Elsheikha MH. Hepatic disease-case reports. Cases J2009; 2: 58.
9. George RA, Godara SC, Dhagat P, Som PP. CT findings in 50 cases of GB CA; MJAFI 2007; 63: 215-19.
10. Sayed M Raza R, M Azhar N, Nasir I, Asif R. Evaluation of Liver masses on CT scan. Professional Med J Sept 2006; 13(3): 431-34.
11. Ariadne MB, Lisa AL, Lucy EH, Fernando FI. GB CA, Can US Evaluate Extent of Disease. Ultrasound Med 1998; 17: 303-9.
12. Sandhu MS, Gupta AK, Haq SM. Primary Ovarian Tumor –Correlation between US, CT and surgery; Indian Journal of Medical and Pediatric oncology.1995 Dec; 16(4): 225-35.
13. Jean NB, Michel AG, Ghossain S, Catherin S, Marc B, Claude G. Epithelial Tumors of the ovary: CT Findings and correlation with US. Radiology 1991; 178: 811-18.
14. Mathis PF, Samuel BF. Deceptions in localizing extrahepatic rt. Upper quadrant Abdominal Masses by CT.AJR 1982; 139: 501-4.
15. Herbert LA, Stanley SS, Douglass FA, Roger S, Harris JF. CT verses US of Adrenal Gland-A prospective study. Radiology 1982; 143: 121-28.
16. Samuel JH, Stanley SS, Barbara JM, Roger S, Douglass FA, Philip OA. A prospective evaluation of CT and US of pancreas. Radiology 1982; 143: 129-33.

HYDATID CYST LIVER

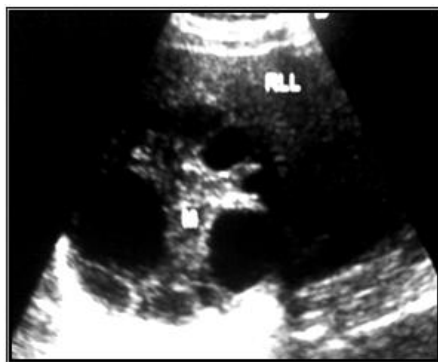

Fig. 1(a)

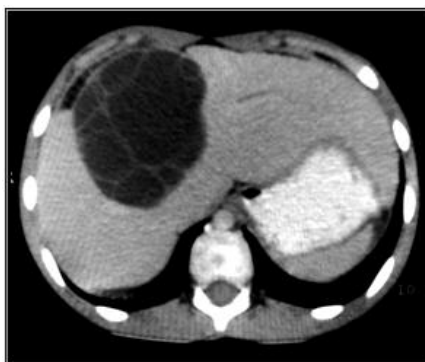

Fig. 1(b)

Figure 1(a)Ultrasound livershowing awell-defined cystic mass with thick septa and central hyperechogenic area giving “spoke wheel” appearance.(b)Computed Tomography showing well defined mass with septation.

HEMANGIOMA LIVER

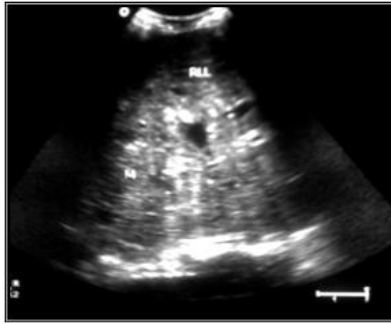


Fig. 2(a)

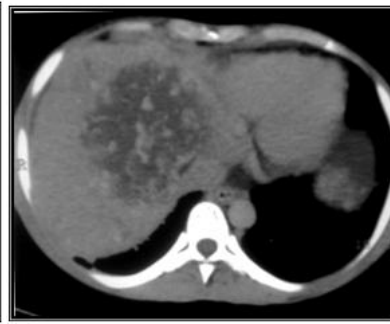

Fig. 2(b)

Figure 2(a)Ultrasound of Liver mass showing an isoechoic mass with small cystic spaces.(b)Computed tomography of same patient showing a well-defined hypodense mass with centripetal type of enhancement- better visualization and localization of mass than sonography.

HEPATIC INJURY (CONTUSION)

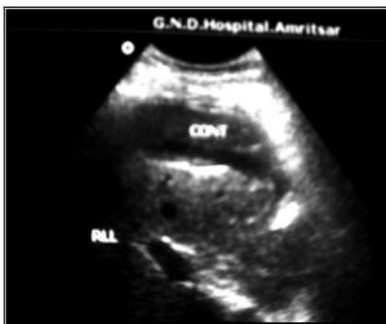

Fig. 3(a)

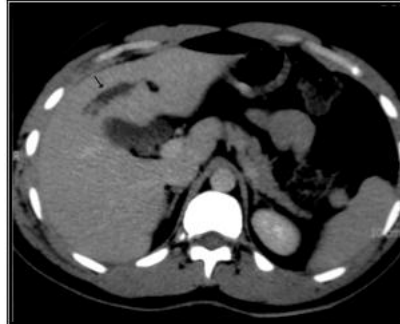


Fig. 3(b)

Figure3(a)Ultrasound liver showing a hypoechoic lesion in right lobe with poor localization of the hepatic segment. (b)Computed tomography shows a well-defined lesion in the antero-inferior segment of right lobe of liver- better visualized on CT than Sonography

EXTRAHEPATIC CHOALGIOCARCINOMA

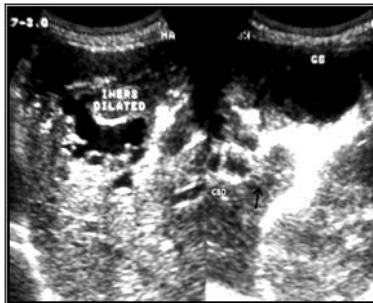

Fig. 4(a)

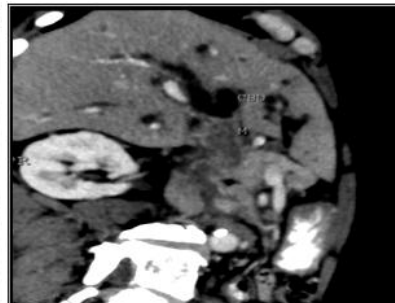


Fig. 4(b)

Figure4(a)Ultrasound showing dilated intrahepatic and extrahepatic biliary radicles with isoechoic mass CBD (black arrow) - poorly distinguished. (b) Computed tomography showing well defined hypodense mass completely filling the lumen of CBD with Obstructive Biliopathy.

SPLENIC INFARCT

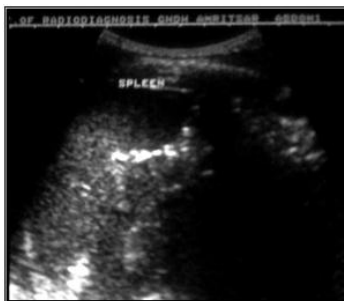


Fig. 5(a)

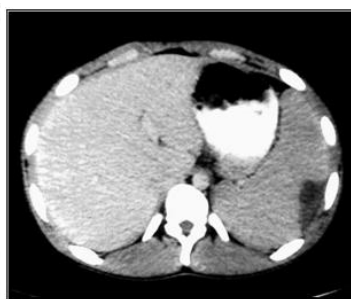

Fig. 5(b)

Figure5(a)Ultrasound spleen of patient with pain left hypochondrium showing no focal or diffuse pathology. (b)CECT Upper abdomen shows a wedge shaped hypodense area in subcapsularregion in relation to the splenic convexity visualized on CT only- Splenic Infarct

GALL BLADDER MASS

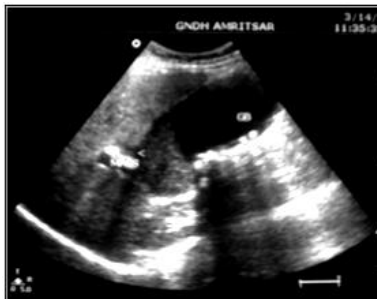

Fig. 6(a)

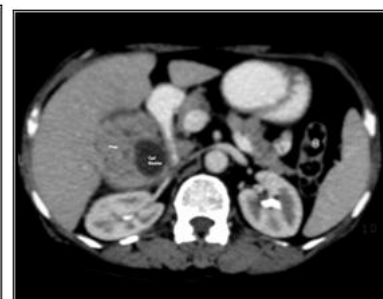

Fig. 6(b)

Figure6(a)Ultrasound gall bladder showing a hypoechoic mass near neck region with associated findings of gall bladder calculi. (b)Computed tomography showing well defined gall bladder mass the calculi could not be visualized on CT (Sonography is better for non-calcified GB calculi)

NECROTISING PANCREATITIS

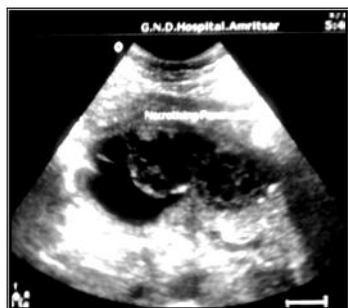

Fig. 7(a)

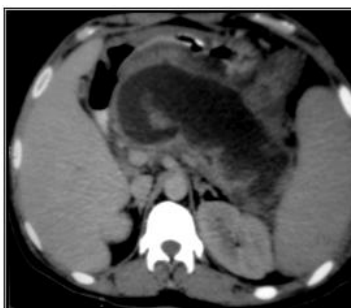

Fig. 7(b)

Figure7(a)Ultrasoundshowingmarked enlargementofpancreasand pancreatic tissue replaced by the gangrenous tissue “phlegmon formation.”(b)Computed tomography shows enlarged pancreas with pancreatic tissue replaced by a large hypodense area.

PANCREATIC PSEUDOCYST

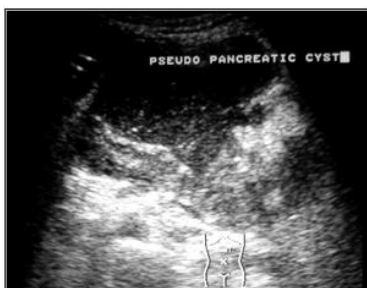


Fig.8(a)

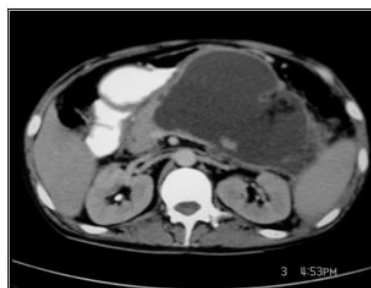

Fig.8(b)

Figure8(a)Ultrasound pancreas showing large intrapancreatic cyst with coarse level internalechoes. (b)Computed tomography shows large well defined high attenuation intrapancreatic hypodense collection, head of the pancreas is spared.

BENIGN CYSTIC NEPHROMA

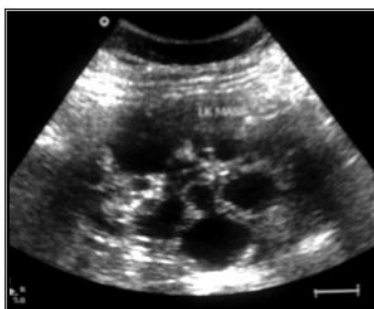


Fig. 9(a)

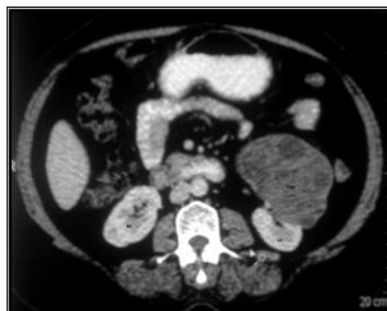

Fig. 9(b)

Figure9(a)Ultrasound Left kidney shows mutiseptated cystic mass which is poorly localized. (b)Computed tomography shows a well-defined mass in relation to anterior cortex of left kidney, cystic component is poorly visualized as compared to US.

EMPHYSEMATOUS PYELONEPHRITIS

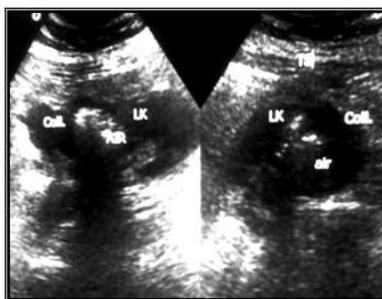


Fig. 10(a)

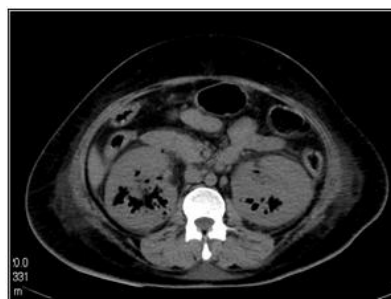

Fig. 10(b)

Figure 10(a)Ultrasound both kidneys showing small echogenic areas in sinus and cortical regions suggestive of air pockets. (b)Computed tomography of both kidneys showing air pockets in both sinus and cortical regions

RENAL INJURY (SHATTERED KIDNEY)

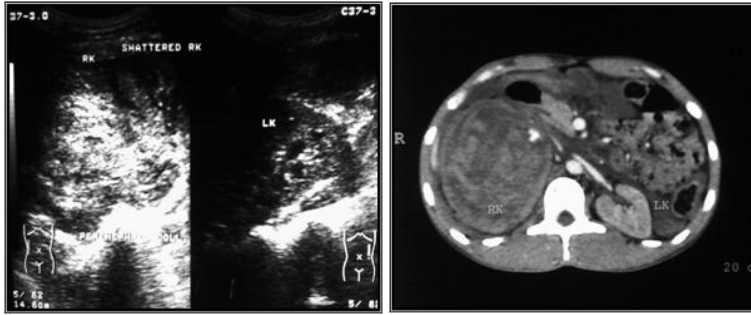


Fig. 11(a)

Fig. 11(b)

Figure 11(a) Ultrasound right kidney of patient with trauma shows ill-defined heterogeneous mass replacing renal tissue. (b) Computed tomography of same patient shows whole of renal parenchyma replaced by the heterogeneous mass with intrarenal hematoma and perinephric collection suggestive of shattered kidney.

RENAL CELL CARCINOMA

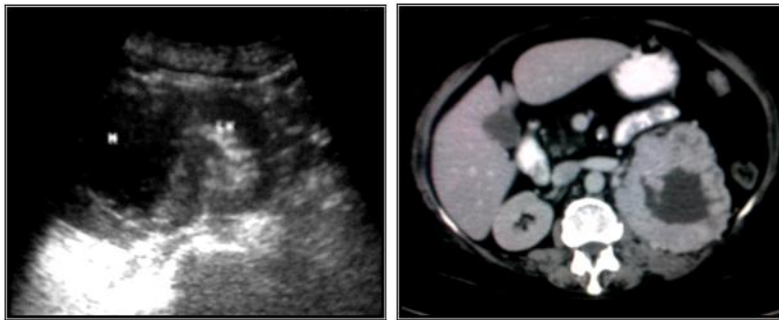


Fig. 12(a)

Fig. 12(b)

Figure 12(a) Ultrasound left kidney shows a hypoechoic mass with central necrosis in upper pole. (b) Computed tomography shows well defined lobulated left renal mass with central necrosis

GASTRIC ANTRAL GROWTH

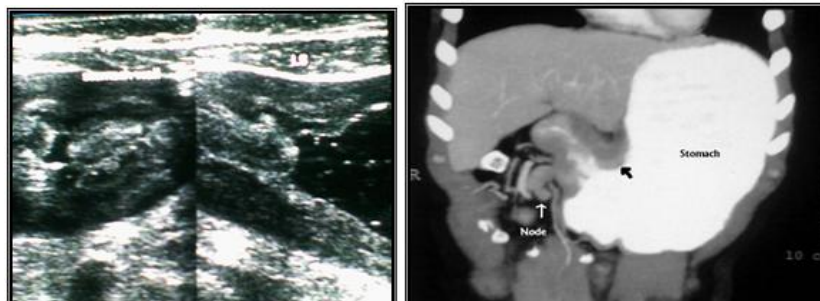


Fig. 13(a)

Fig. 13(b)

Figure 13(a) High resolution Ultrasound showing thickening of walls of the gastric antrum. (b) CECT Upper abdomen shows thickening of wall of the antrum (black arrow) with narrowing pyloric canal and gastric dilatation. Enlarged periantral lymph nodes are seen (white arrow).

ECTOPIC TUBAL PREGNANCY

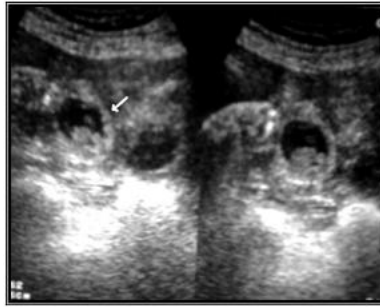


Fig. 14(a)

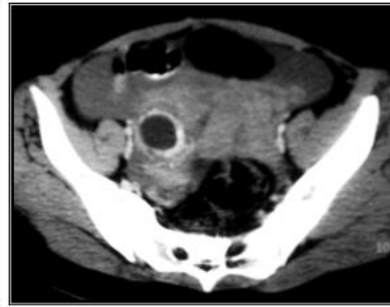

Fig. 14(b)

Figure 14(a) Pelvic Ultrasound showing cystic mass with peripheral echogenic rim in right adnexal region – a small fetal node visualized in it. (b) CECT Pelvis showing a well-defined cystic area in right adnexal region with peripheral ring-like enhancement. No fetal node visualized as seen in sonography. Collection with hematoma formation seen in pelvis

LARGE MULTISEPTATED CYSTIC OVARIAN MASS

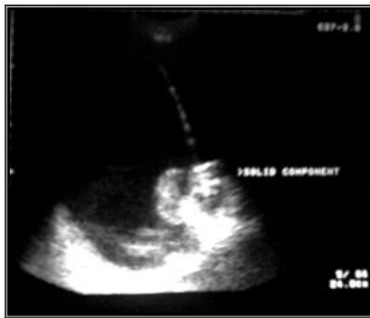

Fig. 15(a)

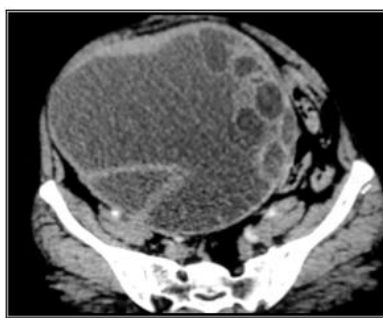

Fig. 15(b)

Figure 15(a) Ultrasound of pelvis showing a large cystic mass with septa and an ill-defined solid component. (b) Computed tomography shows a large multiseptated mass with a solid component along the left lateral wall

OMENTAL DEPOSITS (OMENTAL CAKE)

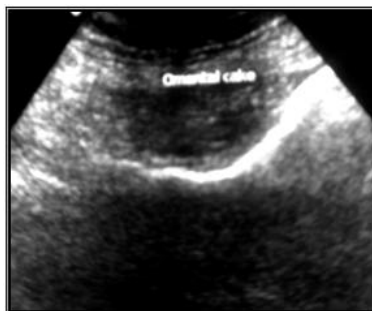

Fig. 16(a)

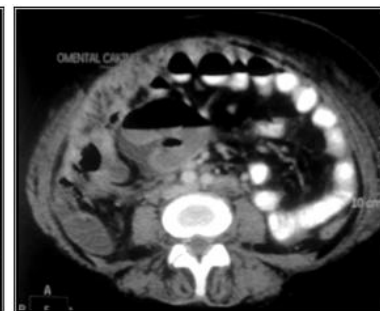

Fig. 16(b)

Figure 16(a) Ultrasound abdomen showing a hypoechoic mass in relation to the omentum – omental cake. (b) CECT Abdomen showing thickening of the omentum with formation of an omental cake in a case of ovarian carcinoma, better visualized on CT scan.

DISSECTING ABDOMINAL AORTIC ANEURYSM

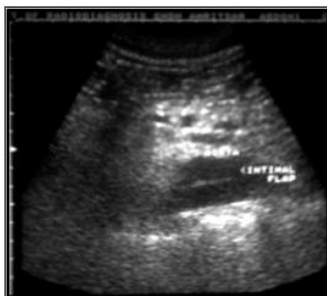

Fig. 17(a)

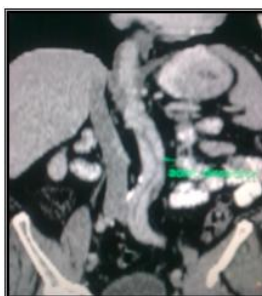

Fig. 17(b)

Figure 17(a) Ultrasound abdominal showing dilated aorta with an echogenic flap in its lumen. (b) CECT Abdomen showing dilated abdominal aorta with an intimal flap. Contrast is seen in true and false lumen suggestive of dissecting type of aortic aneurysm

GROWTH URINARY BLADDER

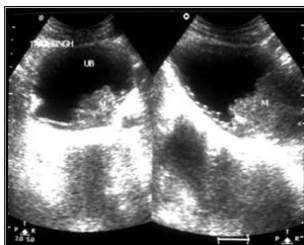


Fig. 18(a)

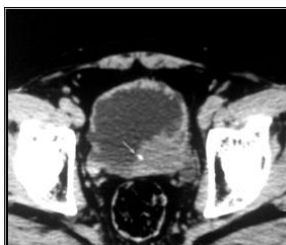

Fig. 18(b)

Figure 18(a) Ultrasound urinary bladder shows a sessile type of intraluminal mass along left lateral wall. (b) CECT Pelvis shows intraluminal mass with a small calcified speck. Perivesical stranding seen which helps in staging of the carcinoma.

AUTHORS:

1. Suman Bhagat
2. Neelam Gauba
3. Sohan Singh
4. Arvinder Singh
5. G.B.S. Mahal

PARTICULARS OF CONTRIBUTORS:

1. Senior Resident, Department of Radiodiagnosis, Government Medical College, Amritsar.
2. Professor, Department of Radiodiagnosis, Government Medical College, Amritsar.
3. Professor, Department of Radiodiagnosis, Government Medical College, Amritsar.

4. Associate Professor, Department of Radiodiagnosis, Government Medical College, Amritsar.

5. Associate Professor, Department of Radiodiagnosis, Government Medical College, Amritsar.

NAME ADDRESS EMAIL ID OF THE CORRESPONDING AUTHOR:

Dr. Arvinder Singh,
316-A, Moon Avenue, Street No. 1,
Majitha Road, Amritsar, Punjab, India.
Email-arvinderdr@rediffmail.com

Date of Submission: 10/12/2013.
Date of Peer Review: 11/12/2013.
Date of Acceptance: 17/12/2013.
Date of Publishing: 02/01/2014