

CASE REPORT

ISOLATED LARGE RENAL HYDATID CYST PRESENTING WITH HYDATIDURIA: A CASE REPORT

Siddalingeshwar V. Mathapati¹, Mohammad Fazelul Rahman Shoeb²

HOW TO CITE THIS ARTICLE:

Siddalingeshwar V. Mathapati, Mohammad Fazelul Rahman Shoeb. "Isolated Large Renal Hydatid Cyst Presenting with Hydatiduria: A Case Report". Journal of Evolution of Medical and Dental Sciences 2015; Vol. 4, Issue 14, February 16; Page: 2393-2397, DOI: 10.14260/jemds/2015/348

ABSTRACT: Renal hydatidosis represents only 2-3% of hydatid disease. Hydatid disease is a cyclozoonotic parasitic infestation caused by the cestode *Echinococcus granulosus*. Isolated renal involvement is extremely rare. We report a rare case of isolated left renal hydatid cyst in a 55-year-old female working as a farmer, who presented with vague abdominal pain and hydatiduria. Exploratory laparotomy was done, total excision of the cyst and pericystectomy was done. Diagnosis was confirmed by histopathology. Postoperative follow-up of the patient for six months showed the patient to be disease free.

KEYWORDS: Hydatid cyst, Echinococcosis, Renal cyst, Hydatiduria.

INTRODUCTION: Cystic echinococcosis (hydatidosis) is a parasitic disease caused by the larval form of *Echinococcus granulosus*. It is a common disease in specific regions. It is endemic in most sheep-raising countries in Asia, Europe, South America, New Zealand and Australia where sheep, dogs and humans live in close contact.^[1,2] The guts of dogs and other carnivorous animals represent a definitive host for the adult worm. Humans become an accidental intermediate host by ingesting *Echinococcus* eggs. The liver is the most commonly involved organ, followed by the lungs. Renal involvement is very rare affecting up to 1.9% of patients.^[3] However, a preoperative accurate diagnosis is important to provide appropriate antihelminthic treatment, take intraoperative precautions preventing parasite dissemination and possibly avoid unnecessary nephrectomy.^[4]

CASE REPORT: A 55-year-old female patient presented with vague abdominal pain of two year duration, insidious in onset, slowly progressive and dull aching in type. She had a history of intermittent passage of small, white, grape-sized, balloon-like structures in the urine (hydatiduria) for last two months. There were no other symptoms associated with the pain. General physical examination revealed no abnormality and systemic examination revealed a large ballotable mass in the left hypochondrium and lumbar region.

Routine blood examinations were normal. The X-ray of the chest was normal. Ultrasonography of the abdomen picked up a cyst in the upper pole of the right kidney, measuring 25 cm in the largest dimension. Rest of the urinary system was normal. A computed tomography (CT) scan of the abdomen was done and displayed a large multiloculated cystic lesion at the upper pole of the left kidney (Figure 1). There were no other lesions in abdominal. A diagnosis of isolated left renal echinococcosis was made.

The patient was started with albendazole. After four weeks, the patient underwent exploratory laparotomy under general anesthesia through midline incision, a large cyst involving the upper pole of the left kidney was noted (Figure 2), and fluid was aspirated and sent for analysis. Peritoneal cavity packed with hypertonic saline soaked mops. The hydatid cyst was laid open after

CASE REPORT

instillation of the cetrimide solution, fluid aspirated, and the endocyst were removed (Figure 3). Approximately 120 small and large daughter cysts were taken out of the cavity (Figure 4). Total excision of the cyst with pericystectomy was done. The patient was discharged after 8 days and was advised oral albendazole therapy, given at a dose of 10 mg/kg for 21 days for three cycles with an intervening period of two weeks between the cycles. Histopathology confirmed the diagnosis of hydatid cyst. Postoperative follow-up of the patient for six months by ultrasonography of the abdomen showed the patient to be disease free.

DISCUSSION: Renal echinococcosis, also called hydatid cyst of the kidney, is an acquired disease of the kidney, caused by the parasite *Echinococcus*. Renal echinococcosis comprises about 2% of all hydatid diseases in man.^[5]

Although hydatid cysts can occur in any location, echinococcosis is usually found in the liver and the lung.^[6] Extrahepatic hydatidosis has been described in the peritoneal cavity, retroperitoneum, spleen, kidney, and adrenal glands and even in the spine, myocardium, and abdominal wall.^[6] Kidney involvement in echinococcosis is extremely rare. It is involved only in 2–3% of all cases, even in areas where hydatid disease is endemic, usually as a part of disseminated disease.^[7] Thus, isolated renal echinococcosis is very rare and only few cases were reported in the literature.^[3]

Renal hydatid cysts usually remain asymptomatic for years. However, the patient may present with renal pain, hematuria, pyuria, and intermittent fever.^[8] Some may present with a mass palpable in the loin. Rupture of the cyst into the renal collecting system causing hydatiduria i.e. passing whitish material also called as the “grape skin,” the scolices, in the urine is pathognomonic and is seen in only 10-20% of the renal hydatidosis.^[9] It is usually microscopic. Macroscopic hydatiduria is very rare.^[8]

Laboratory tests may suggest the diagnosis, which is confirmed by radiologic examination such as ultrasonography, computed tomography, and/or MRI.^[10]

Ultrasonography is the most appropriate method for the differential diagnosis of renal cystic cancer, with a sensitivity of 95%.^[10]

CT scan usually demonstrates an expansible, hypo-attenuating mass with a well-defined wall and daughter cysts within the parent cyst.^[10]

MRI is considered an acceptable alternative to the CT scan in the diagnosis. Hydatid fluid is hypointense on T1-weighted and hyperintense on T2-weighted images.^[11]

IV pyelography can show distortions of the upper urinary tract, with sign of compression or a nonfunctioning kidney, but this imaging technique is reserved only for selected cases.^[8]

Management is mainly surgical, in view of the catastrophic complications that a cyst rupture can cause. Conservative medical management with oral albendazole is unreliable, being successful in only 40% of cases. Radiological intervention in the form of Percutaneous Aspiration Injection Re-aspiration followed by Percutaneous drainage (PAIR-PD) has been described, but is again is successful in only 70% of cases of unilocular cysts.^[12, 13] Hence, surgery is the main form of treatment, especially so for the multilocular variant of the disease for which surgery is the only form of treatment. Surgical management consists of various options. Total excision consists of either wedge resection or partial nephrectomy and partial excision includes partial pericystectomy followed by capitonnage, re-approximation of the pericyst or marsupialization. Renal sparing surgery by way of partial excision is possible in 75% case and is the most adapted treatment whenever possible.^[5, 14]

CASE REPORT

Partial excision should be preceded by the injection of scolicial agents into the cyst which include 20% hypertonic saline, chlorhexidine, 80% ethanol, 0.5% cetrimide, 3% H₂O₂ and 0.5% silver nitrate.^[14]

Laparoscopic removal of renal hydatid cyst can have some clinical advantages over traditional surgery, but risks of cyst rupture and dissemination during dissection, entrapment, and removal of the hydatid cyst during laparoscopy have been reported.^[10]

Patient has to be operated under the cover of antihistaminics and steroids for the fear of anaphylaxis if cyst rupture occurs during surgery. No intervention is needed when the cyst walls are calcified.^[3] Conventionally, it is recommended to start the patient on a course of oral albendazole after surgery.

CONCLUSION: Isolated primary hydatidosis of the kidney should always be considered in the differential diagnosis of any cystic renal mass, even in the absence of accompanying involvement of liver or other visceral organs.

REFERENCES:

1. Karavias D, Vagianos C, Kakkos S, et al. Peritoneal echinococcosis. *World J Surg.* 1996; 20: 337–4.
2. Horchani A, Nouira Y, Kbaier I, et al. Hydatid cyst of the kidney. A report of 147 controlled cases. *Eur Urol.* 2000; 38: 461–7.
3. Zayed AM, Abdel-Rahman AH. Isolated hydatid cyst of the kidney. *Diagn Surg Treat AJU.* 2005; 3: 6–12.
4. Angulo JC, Sanchez-Chapado M, Diego A, et al. Renal echinococcosis: clinical study of 34 cases. *J Urol.* 1997; 157: 787–94.
5. Ameer A, Lezrek M, Boumdin H, et al. Hydatid cyst of the kidney based on the series of 34 cases. *Prog Urol* 2002; 12: 409-14.
6. Tepetes K, Christodoulidis G, Spyridakis M, Hatzitheofilou K. Large solitary retroperitoneal echinococcal cyst: a rare case report. *World Journal of Gastroenterology.* 2007; 13(45): 6101–6103.
7. Sarah JM, Cristopher WJ, Waren DJ, Jr. Parasitic diseases of the genitourinary system. In: Wein AJ, Kavoussi LR, Novick AC, Partin AW, Peters CA, editors. *Campbell-Walsh. Urology.* 9th edition. Saunders; 2007. pp. 458–459.
8. Mongha R, Narayan S, Kundu AK. Primary hydatid cyst of kidney and ureter with gross hydatiduria: A case report and evaluation of radiological features. *Indian J Urol.* 2008; 24: 116–7.
9. Gogus C, Safak M, Baltasi S, Turkolmez K. Isolated Renal Hydatidosis: Experience with 20 cases. *J Urol.* 2003; 169: 186–9.
10. Turgut AT, Odev K, Kabaalioglu A, Bhatt S, Dogra VS. Multitechnique evaluation of renal hydatid disease. *American Journal of Roentgenology.* 2009; 192(2): 462–467.
11. Sayek I, Tirnaksiz MB, Dogan R. Cystic hydatid disease: current trends in diagnosis and management. *Surgery Today.* 2004; 34(12): 987–996.
12. Cushieri SA, Steele RJ, Moosa AR. *Treatment of Hydatid Cyst, Essential Surgical Practice*, 4th ed. Arnold Publishers, Oxford. Butterworth-Heineann; 2000; 350.

CASE REPORT

13. Akhan O, Ustunsoz B, Somuncu I, et al. Percutaneous renal hydatid cyst treatment: Long-term results. *Abdom Imaging* 1998; 23: 209-13.
14. Zmerli S, Ayed M, Horchani A, Chami I, El Ouakdi M, Ben Slama MR. Hydatid cyst of the kidney: diagnosis and treatment *World J Surg* 2001; 25: 68-74.

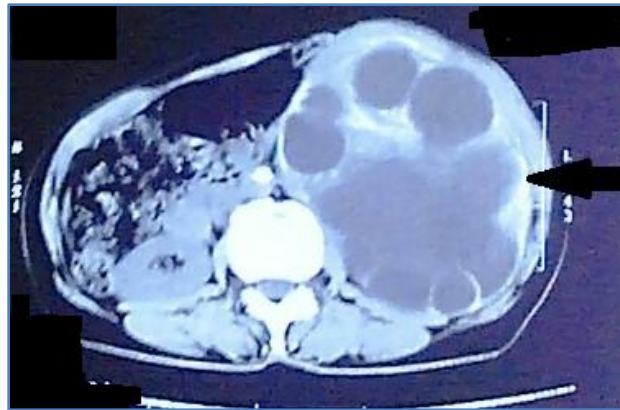

Figure 1

Figure 1: CT scan showing large multiloculated cystic lesion arising from upper pole of left kidney.

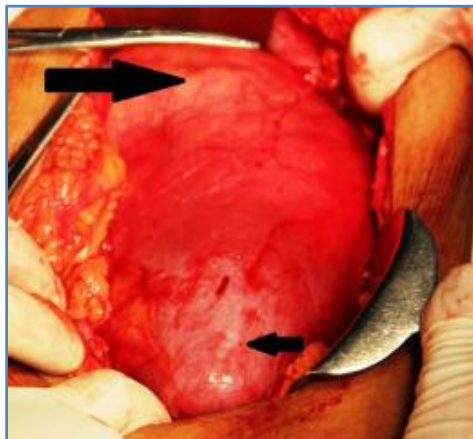


Figure 2

Figure 2: Laparotomy revealed large cystic lesion from upper pole of left kidney (shown by large arrow), normal lower pole (shown by smaller arrow).

CASE REPORT

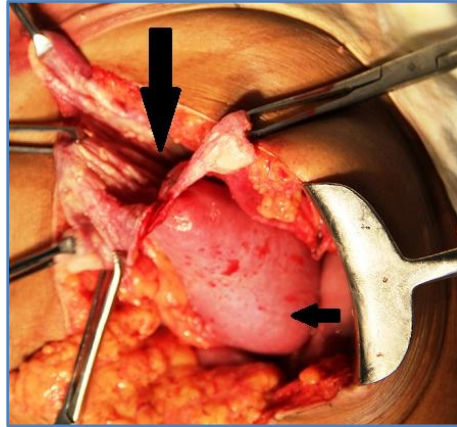


Figure 3

Figure 3: Hydatid cyst laid open (shown by larger arrow), lower pole (shown by smaller arrow).



Figure 4

Figure 4: Surgical specimen exhibited multiple daughter cysts.

AUTHORS:

1. Siddalingeshwar V. Mathapati
2. Mohammad Fazelul Rahman Shoeb

PARTICULARS OF CONTRIBUTORS:

1. Senior Resident, Department of General Surgery, Gulbarga Institute of Medical Sciences, Gulbarga.
2. Senior Resident, Department of General Surgery, Gulbarga Institute of Medical Sciences, Gulbarga.

FINANCIAL OR OTHER

COMPETING INTERESTS: None

NAME ADDRESS EMAIL ID OF THE CORRESPONDING AUTHOR:

Siddalingeshwar V. Mathapati,
Plat No. 15,
Sangameshwar Nilaya,
Behind Vaatsalya Hospital,
Sedam Road, Gulbarga – 585105.
E-mail: siddu.swamy.99@gmail.com

Date of Submission: 25/01/2015.

Date of Peer Review: 26/01/2015.

Date of Acceptance: 07/02/2015.

Date of Publishing: 16/02/2015.