

STUDY OF BRAIN TUMOURS BY NOVEL MAGNETIC RESONANCE TECHNIQUEMohammad Shamim Ahmad¹, Reyaz Anjum², Anju Singh³, Dinesh Kumar Singh⁴, D. G. Paricharak⁵**HOW TO CITE THIS ARTICLE:**

Mohammad Shamim Ahmad, Reyaz Anjum, Anju Singh, Dinesh Kumar Singh, D. G. Paricharak. "Study of Brain Tumours by Novel Magnetic Resonance Technique". Journal of Evolution of Medical and Dental Sciences 2015; Vol.4, Issue 03 January 08; Page: 416-432, DOI: 10.14260/jemds/2015/63

ABSTRACT: In the present study, thirty patients in the age range of 22 to 63 years of age were included after being diagnosed to be having brain tumour on CT scan or conventional MRI. In addition DWI, MRS, and PWI were carried out in these patients. All the patients with suspicious malignant lesions were then subjected to FDG-PET examination. Histopathological correlation was obtained in all the patients to serve as gold standard against which other modalities will be assessed for their sensitivity, specificity, positive predictive value, negative predictive value and diagnostic accuracy. Out of thirty patients selected for this study, twenty cases were found to be malignant and ten cases were benign on Histopathological evaluation. Majority of malignant lesions were glioblastoma multiforme. Amongst benign cases, majorities were meningioma, one was a Granulomatous lesion and one was a benign cystic lesion. MRI including the novel techniques showed high sensitivity and specificity in identifying malignant brain lesions and has a future role in better characterization of brain tumours. Wherever available, it should be integrated in routine workup of patients presenting with brain tumours or for follow up of patients undergone surgery / adjuvant chemotherapy.

KEYWORDS: Brain tumour, Histopathological evaluation, Magnetic resonance technique.

INTRODUCTION: Novel MRI techniques evaluate changes at the microvascular, haemodynamic & cellular levels of brain tumours. In addition to structural changes they also evaluate changes at the metabolic and biochemical levels. Incorporation of new diagnostic techniques, such as diffusion-weighted imaging (DWI), perfusion-weighted imaging (PWI) and magnetic resonance spectroscopy (MRS) into the diagnostic protocol allows us to obtain detailed information about tumours. This presents the best possibility of accurate grading of brain tumours in the preoperative time, allowing us to select the most appropriate therapeutic management for the patients.

DWI is echo-planar imaging that measures brownian motion of water molecules (i.e. diffusion in biological tissue). Biological tissues in which diffusion is the same in all directions is isotropic; if diffusion is restricted in one direction, tissues are anisotropic. The most common barrier to diffusion is the cell wall. CSF is isotropic; diffusion in gray matter in all directions compared to the CSF is limited but also isotropic. Diffusion in white matter is anisotropic.^[1]

The diffusion capacity of water protons is tissue specific and creates a specific contrast on DWI. On DWI, the motion of water protons in biological tissue causes changes in the signal which are quantified by calculating the apparent diffusion coefficient map (ADC map).^[2] DWI has a fundamental role in the evaluation of the age of brain ischemia, in imaging of traumatic changes, and in evaluation activities of demyelinating lesions.^[3]

The rapid growth of cells in a tumour causes increased metabolic demands. Cellular hypoglycaemia and hypoxia result in the production VEGF leading to tumour neovascularization and

ORIGINAL ARTICLE

higher volume of blood flow through tumour tissue. Tumour neovascularization and haemodynamic changes are the basic principles of perfusion MRI, which evaluate the blood supply to brain tissue by four parameters: CBV (the quantity of blood in a given volume in mL/100mg), CBF (the blood flow in brain tissue in mL/100g/min), MTT (the average time for arteriovenous passage of blood in a given volume in seconds), and TTP (the average time to maximum density in the scanning area in seconds).[4,5]

MRS is a non-invasive method and currently is part of the advanced diagnostic protocol in neuroradiology. MRS can determine pathological changes in brain tissue long before conventional techniques.[6] MRS provides biochemical and metabolic information about brain tumours and their surrounding tissues. Thus MRS, contributes significantly to the distinguishing of tumour from non-tumour lesions, the type of diagnosis and tumour grading in preoperative time, edema from infiltrative growing tumours, the monitoring of tumour response to treatment and distinguishing post irradiation necrosis from tumour recurrence.[7] 18 FDG PET is used to diagnose, stage, and monitor brain tumours. It has the capability to depict abnormal metabolic activity before any anatomical change occurs. Tumour imaging with FDG PET is based on the fact that malignant tumours with high metabolic rates take up more glucose and FDG than do surrounding tissues. After FDG is administered intravenously, it is transported into the cells by glucose transporter proteins. However, because malignant tumour cells express more-specific transporter proteins with a greater affinity for glucose than those expressed by normal cells, there is increased glucose flow into the cancerous cells.

AIMS AND OBJECTIVES:

- To define predictors of malignancy using newer magnetic resonance techniques.
- To define parameters useful for differentiating benign and malignant brain tumours using newer magnetic resonance techniques.
- To assess the sensitivity, specificity, positive predictive value, negative predictive value and diagnostic accuracy of these different techniques as compared to the histopathological diagnosis.

MATERIAL AND METHODS: The present study was conducted in the Department of Radiological Imaging & Department of PET Imaging of Institute of Nuclear Medicine and Allied Sciences (INMAS), Brig S K Mazumdar Marg, Timarpur, Delhi-110054 after taking necessary approval from the Institutional Ethics Committee.

PATIENTS: A total of 30 patients were included in the study after taking written informed consent. Patients taken up for study were cases of brain tumours diagnosed on conventional MRI or CT scan. Patient selection was done from the patients coming for MRI in the Department of Radiological Imaging. A thorough clinical history was taken and relevant physical examinations were done. All the routine blood investigations were carried out including renal function tests.

All patients of brain tumours diagnosed on CT scan / Conventional MRI coming in our department were chosen for the study. Patients were explained about the procedures to be carried. Detailed MRI examination including conventional MRI sequences and novel MRI techniques (DWI,

ORIGINAL ARTICLE

PWI & MRS) were performed on these patients. PET correlation was obtained in patients suspected to have malignancy on MRI evaluation.

Patients were then followed during their management by the referring surgeons and results of histopathology of tumour tissues were collected. The histopathological diagnosis was considered as the 'gold standard' in this study.

STUDY DESIGN: Diagnostic accuracy study.

FOLLOWING ELIGIBILITY CRITERIA WERE FOLLOWED:

AGES: All age group

GENDERS: Both sexes.

INCLUSION CRITERIA:

1. Patients provisionally diagnosed with brain tumour by CT/MRI.
2. Tumour size at least 1.5 cm in greatest axial dimension on CT/MRI.

EXCLUSION CRITERIA:

1. All patients of known renal pathology.
2. Life expectancy of < 3 months
3. Absolute or Relative contraindication to MRI and PET-CT.
4. Pregnant or lactating patients.

The imaging protocol and parameters were as follows:

NOVEL MR PROTOCOL:

DWI Protocol: DWI with single-shot echo-planar imaging (EPI) was performed in axial plane with the diffusion gradients applied along each of the 3 principal directions (x, y, z) with a diffusion sensitivity (b-values) of 0,500 and 1000 s/mm² respectively. Three sets of axial diffusion-weighted images were generated, and an apparent diffusion coefficient (ADC) map was calculated by placing the ROI well within the confines of the lesion. Necrotic or hemorrhagic portions of the lesion were excluded from the ADC measurement.

Perfusion Imaging (PWI) Protocol: Perfusion imaging (T2*-weighted, gradient-echo single-shot EPI sequence) was performed during a single bolus contrast infusion. A gadolinium-based MR contrast agent, at a dose of 0.1 mmol per kg of body weight, was infused with a power injector at a rate of 5 ml/second, followed by a 40 ml normal saline flush at the same infusion rate. Scan parameters were as follows: TR/TE 2 410/49 ms; flip angle 90 degrees; field of view 220 x 220 mm; and acquisition time 120 seconds. Twenty-two slices were obtained with slice thickness of 5 mm, with 1.5 mm intersection gap, and the matrix was 128 x 128mm. The passage of the contrast agent through vascularized parts of the tumour leads to a reduction in signal intensity. Converting the values of individual parameters by post processing to the colour range creates maps with different blood flows. Regional cerebral, and tumour vascularity is correlated with the cerebral blood volume (CBV).

ORIGINAL ARTICLE

Perfusion analysis was performed at Siemen's workstation using the 'Perfusion MR' application software.

MR Spectroscopy: Single-voxel¹H MR spectroscopy was performed in the solid and enhancing part of lesions by using a point-resolved spectroscopic sequence (PRESS) with TR = 1500 msec, TE = 100 msec, acquisition time of approx 6.3 min and 128 acquisitions. Generally a voxel size of 1 cm x 1 cm x 1 cm was used for adequate signal to noise ratio. Localised shimming and high quality spatial saturation pulses and water suppression was used to improve the quality of the spectra. Both internal and external references were generated. The normalized integral values were automatically generated by the available software.

With single voxel spectroscopy (SVS), the placement of the voxel is of critical importance. The voxel was placed so as to include as much of the lesion as possible while excluding normal as well as necrotic tissue. Spectral data was acquired by applying three orthogonal slice selective gradients to define three slabs, intersection of which defined the VOI.

Few spectra were also taken from the normal site to serve as control.

One or more novel MR techniques was performed according to indication and feasibility. Using standard imaging parameters, the images were analyzed, findings were recorded and comparisons between various MR sequences were done.

PET-CT Protocol: A low dose non-contrast CT scan of brain was obtained for attenuation correction and co-registration. Limited PET scan of the brain was acquired approximately 60 minutes after the intravenous injection of 296-444 MBq of 18F-FDG. The PET scan was acquired in a whole body full ring scanner (GE Discovery STE 16 camera). Images were reconstructed using a 3D VUE algorithm and slices reformatted into axial, coronal and sagittal views.

Following radiological criteria were taken into consideration while evaluating brain Tumours:

- a) Tumours were considered as highly malignant gliomas when they showed contrast enhancement with rCBV ratio >1.5 on PWI, a choline (Cho)/creatine (Cr) >2.5 on MRS, significantly reduced/absent NAA peak along with NAA/Cho ratio <1 in the tumour adjacent normal-appearing brain tissue.
- b) Tumours showing no or mild contrast enhancement along with rCBV ratio <1.5 on PWI, and Cho/Cr <2.5 on MRS were considered to be low grade malignant gliomas.
- c) Tumours showing homogeneous contrast enhancement along with rCBV ratio < 1.5 on PWI were considered to be CNS lymphomas.
- d) Tumours showing contrast enhancement (homogeneous or ring-enhancing) with rCBV ratio > 1.5 on PWI, Cho/Cr >2.5 on MRS, and NAA/Cho >1 in the normal-appearing brain tissue adjacent to the tumour were considered to be metastases.
- e) peritumoural rCBV: Tumours with low rCBV in the immediate non-enhancing peritumoural tissue were considered to be metastases, while those with high rCBV were considered to be highly malignant gliomas.
- f) Cystic lesions with rim contrast enhancement, low ADC value in the central cystic portion, and with lactate and amino acid peaks on MRS, were considered to be abscesses.

ORIGINAL ARTICLE

Criteria (d) and (e) were considered together while differentiating between metastases and highly malignant gliomas.

Data Quantitation: Morphologic analysis was performed by conventional MRI techniques using following features:

- i. Signal contrast with respect to normal brain parenchyma.
- ii. Tumour size, shape, margins, internal architecture & extent of perifocal edema.
- iii. Indirect tumour signs (compression syndrome, midline shift etc.)

Post processing of the perfusion weighted images generates relative regional cerebral blood volume (rCBV) maps which were included in the analysis. The rCBV values in the tumour and in the normal-appearing white matter (NAWM) in the centrum semiovale were determined. The rCBV tumour was the maximum rCBV value obtained in the tumour. The rCBV ratio was calculated as the rCBV tumour/rCBV NAWM. In general high grade tumours have high rCBV in tumour as compared with rCBV in NAWM. Perfusion analysis was performed at Siemen's workstation using the 'Perfusion MR' application software.

Three-dimensional regions of interest (ROIs) were drawn manually on non-interpolated DW images in all lesions and additional normal tissue regions. ROIs used were slightly smaller than the actual lesions in order to avoid partial-volume effects. Areas of necrotic tissue, as identified from the morphologic and contrast-enhanced images, were avoided.

Proton magnetic resonance spectroscopy was analyzed for the presence of 5 different metabolite peaks. These are the choline (Cho), creatine (Cr), N-acetylaspartate (NAA), lactate, and lipid. Tumours, especially primary brain tumours show very specific pattern in elevation of choline and loss of N-Acetyl Aspartate peaks. Cho/Cr and Cho/NAA ratio were also calculated. In general the higher grade gliomas tend to exhibit higher Cho/Cr and Cho/NAA ratios.

Lesions were localized on PET-CT and ROI were drawn well within the lesions which generated standardized uptake values for the lesion with FDG uptake.

Based on the above parameters, the lesions were categorized as benign or malignant. A prospective diagnosis of malignant lesion was made based on morphological characteristics, PWI (rCBV tumour), ADC values, Values of NAA, Cho & Cr with Cho/Cr and Cho/NAA ratios and SUV on PET images.

STATISTICAL ANALYSIS: The results of PWI, DWI and MR spectroscopy were compared with histopathologic factors.

All the statistical data were assessed for the sensitivity, specificity, positive predictive value, negative predictive value and diagnostic accuracy of these different techniques. These were compared with the histopathological findings and datas.

Statistical analysis was carried out by using Chi square test to calculate the correlation between different imaging modalities (Novel MRI techniques) and histopathological examination.

A measure of agreement 'Kappa statistics' along with its statistical significance was determined by Chi square test. It was used to measure the agreement between different imaging modalities and histopathological diagnosis.

Statistical analysis was conducted using version 12.0 of the software, SPSS (Statistical Package for Social Sciences).

ORIGINAL ARTICLE

OBSERVATION AND RESULTS: A total of 30 patients with brain tumours (referred to MRI department of INMAS, Delhi-54) were included in the present study. Novel MRI techniques (DWI, PWI & MRS) were performed on these patients.

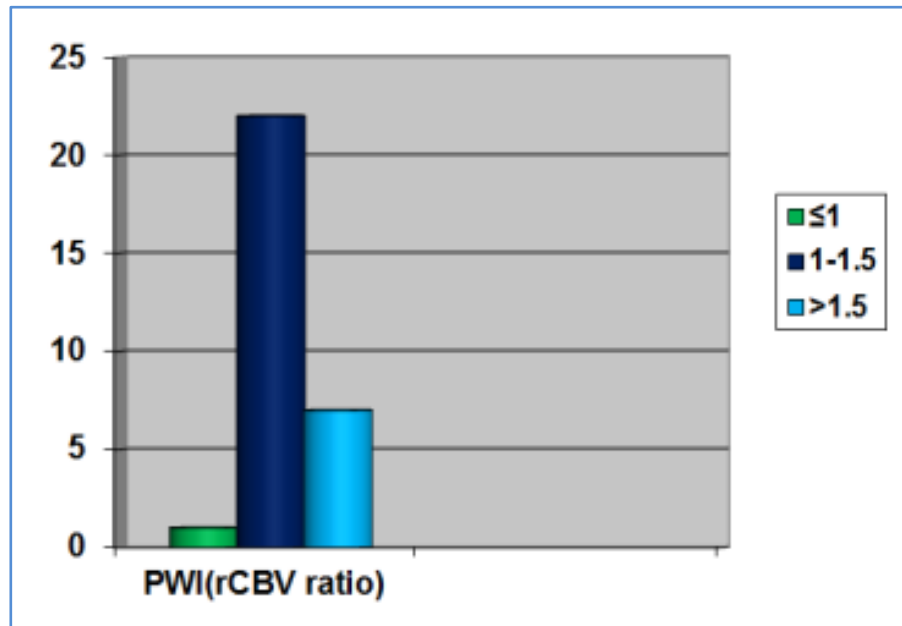
The patients were classified according to various Parameters:

Table 1: Distribution of lesions according to Perfusion Weighted MRI.

Categorization of lesions based on rCBV ratio yielded by perfusion weighted MRI:

RCBV ratio	Number of Patients
≤ 1	01
Between 1 & 1.5	22
>1.5	07

Table 1



Graph - 1

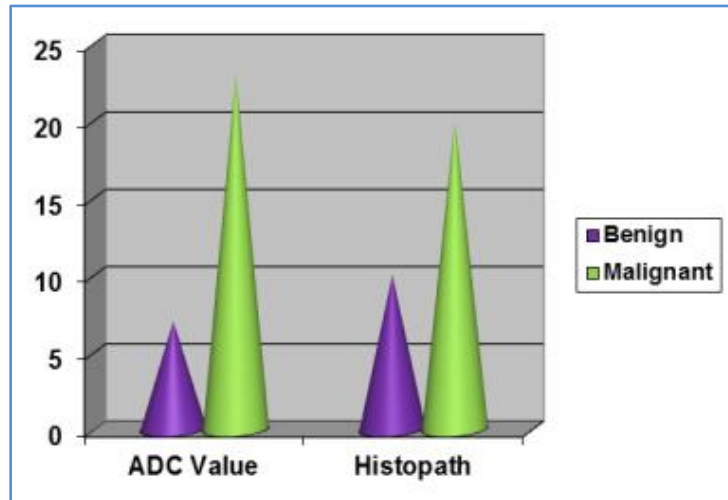
Table 2: Distribution of lesions according to DWI.

Categorization of lesions as benign or malignant based on Diffusion weighted imaging characteristics alone yielded the following results:

Type of lesion	DWI	Histopath
Benign	07	10
Malignant	23	20

Table 2

ORIGINAL ARTICLE



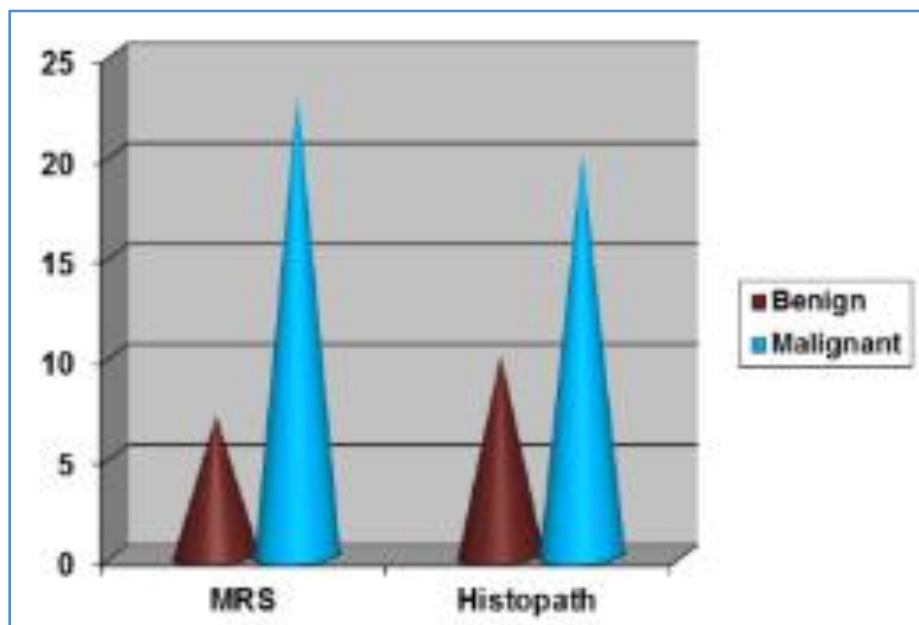
Graph - 2

Table 3: Distribution of lesions according to MRS.

Categorization of lesions as benign or malignant based on MR spectroscopy results alone yielded the following results:

Type of lesion	MRS	Histopath
Benign	07	10
Malignant	23	20

Table 3



Graph - 3

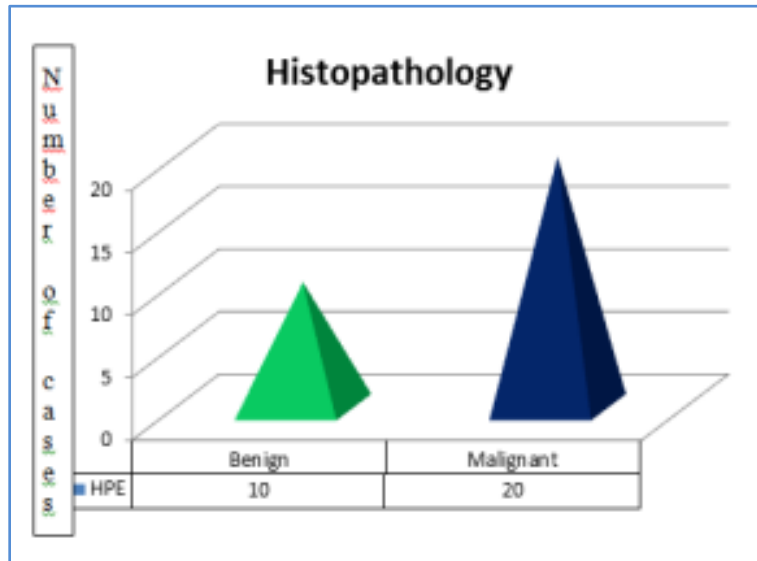
ORIGINAL ARTICLE

Table 4: Histopathological diagnosis.

Ten lesions were benign with majority being meningioma. Rest of the twenty lesions.

HPE	Number of cases	Percentage
Benign	10	33.33%
Malignant	20	66.66%
Total	30	100%

Table 4



Graph - 4

Table 5: Distribution of lesions on histopathology.

Type of lesion	Number of cases	Percentage
I - Malignant	20	66.66
a) Glioblastoma multiforme	14	46.66
b) Metastasis	3	10
c) Lymphoma	1	3.33
d) Anaplastic astrocytoma	2	6.66
I - Benign	10	33.33
a) Meningioma	4	13.33
b) Low grade glioma	2	6.66
c) Pituitary adenoma	1	3.33
d) Arachnoid cyst	1	3.33
e) Tuberculoma	1	3.33
f) Choroid plexus papilloma	1	3.33

Table 5

ORIGINAL ARTICLE

STATISTICAL ANALYSIS: Out of thirty cases twenty (66.66%) were malignant at histopathology. Ten cases were benign (33.33%) of which one case was found to be granulomatous lesion and another one was benign cystic lesion.

To evaluate the performance of novel magnetic resonance techniques including perfusion weighted imaging, diffusion weighted imaging and magnetic resonance spectroscopy against HPE as gold standard, five standard parameters were calculated: sensitivity, specificity, positive predictive value, negative predictive value and diagnostic accuracy after correlation with histopathology results of thirty patients.

The diffusion weighted imaging alone showed a sensitivity of 95% and specificity of 70% with a positive predictive value of 86.3%, negative predictive value of 87.5% and diagnostic accuracy of 86.7%.

The MR spectroscopy was 90% sensitive and 60% specific in identifying a malignant lesion. It showed a positive predictive value of 82%, negative predictive value of 75% with a diagnostic accuracy of 80%.

With perfusion weighted imaging, the rCBV ratios were determined. With rCBV ratio value >1.5, the sensitivity and specificity was 100% with poor negative predictive value. Lesions with rCBV ratio between 1 and 1.5 were of indeterminate variety and showed significant overlap amongst benign and malignant lesions.

Table 6: Statically Analysis.

Modality	Sensitivity	Specificity	PPV	NPV	Diagnostic Accuracy
DWI	95%	70%	86.3%	87.5%	86.7%
MRS	90%	60%	80%	82%	75%
Combined	100%	90%	95%	100%	96.7%

Table 6

The statistical analysis showed that with combined use of Novel magnetic resonance techniques and FDG PET, the specificity increased to 90% and diagnostic accuracy increased to 96.7% which is highly significant.

The Chi square value for the novel MRI techniques was 0.5 which was significant ($p < 0.05$). The kappa statistic shows a value of 0.406 which is significant and shows good agreement between the two modalities.

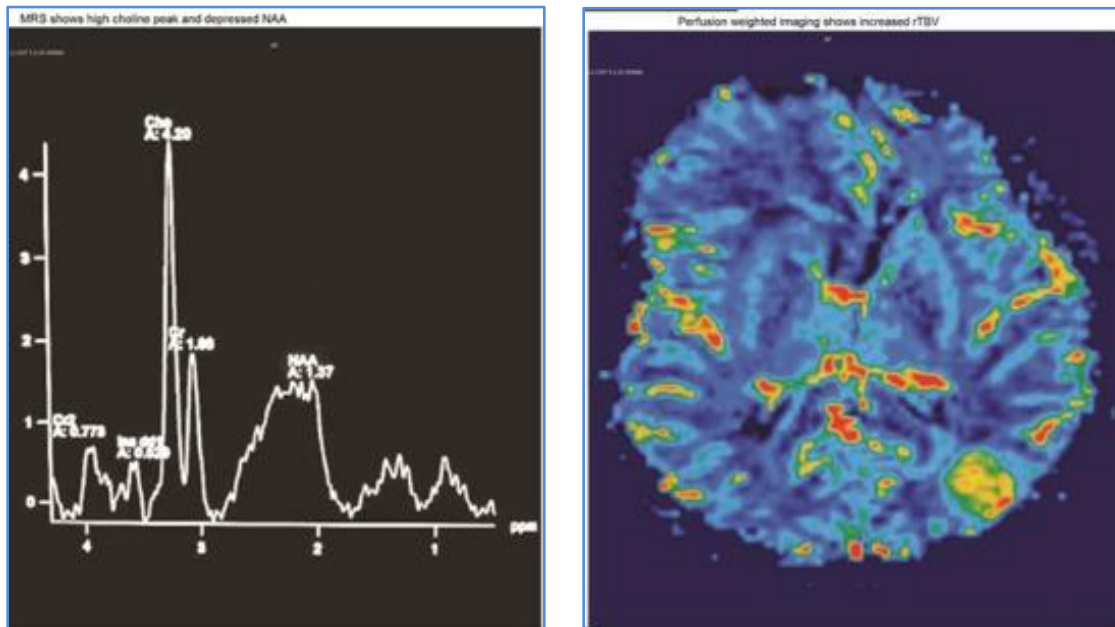
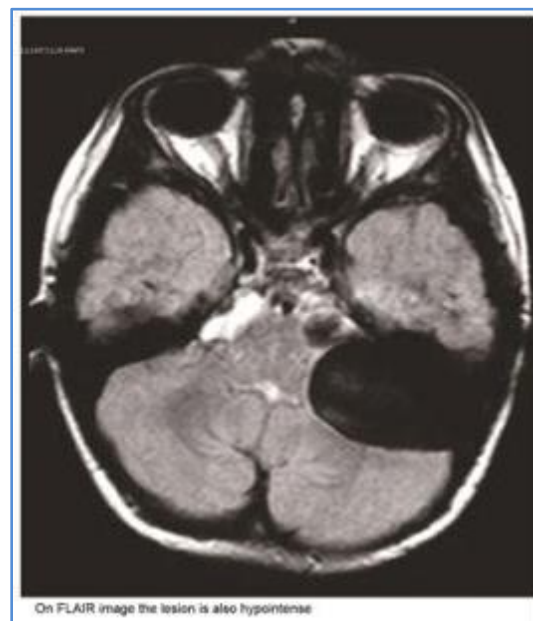
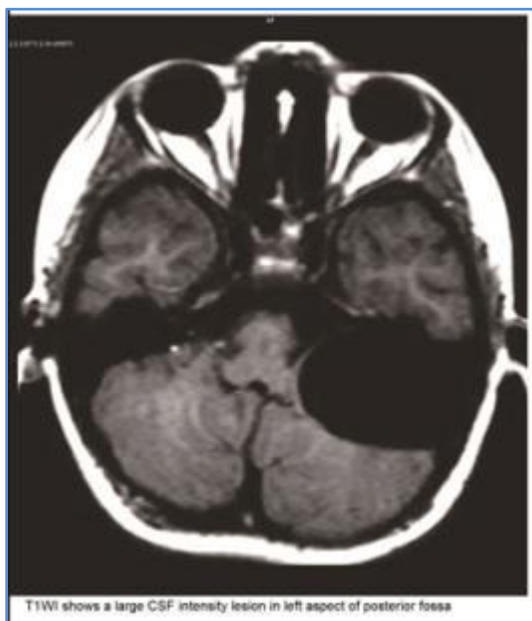


Fig. 1: Case of anaplastic astrocytoma



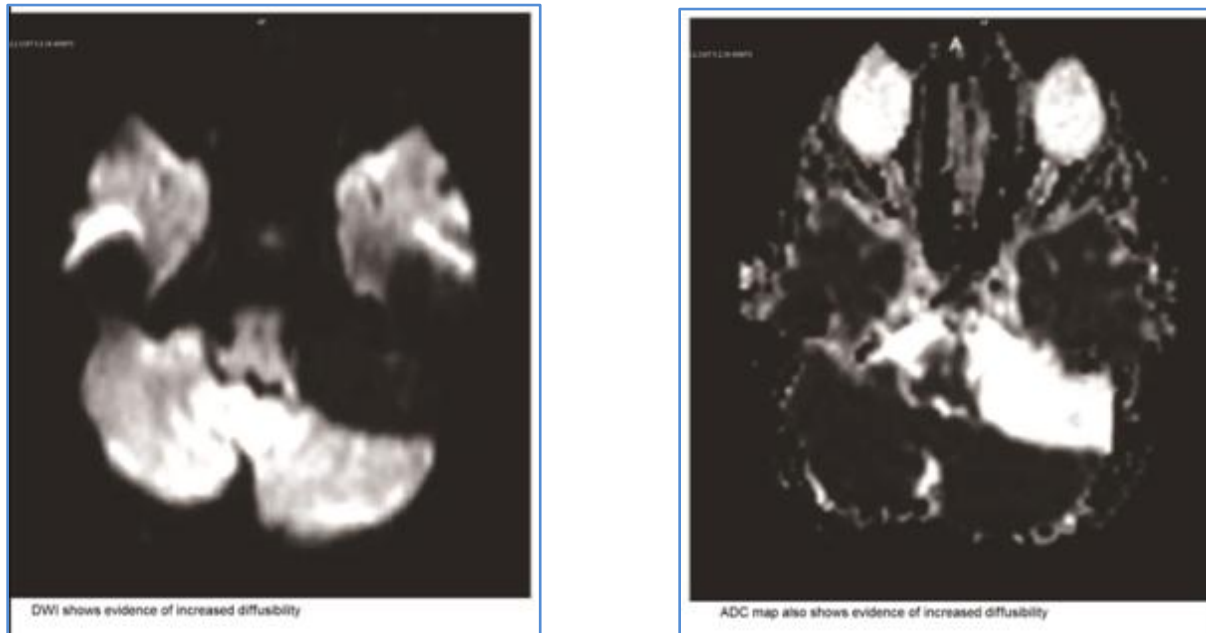
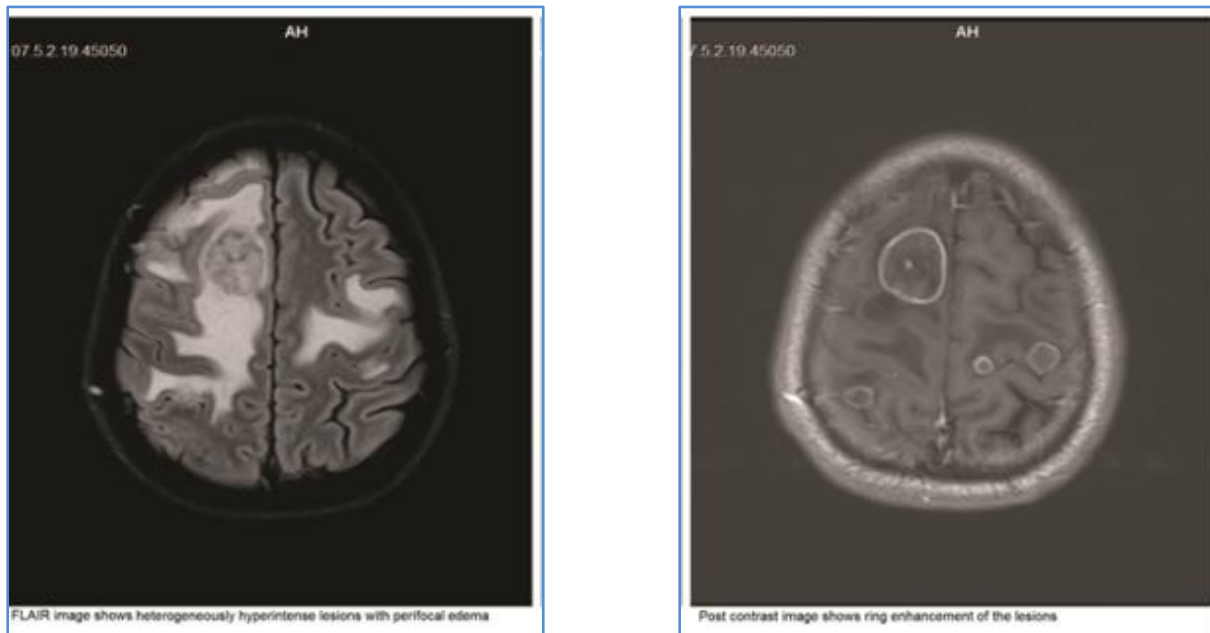


Fig. 2: Case of arachnoid cyst



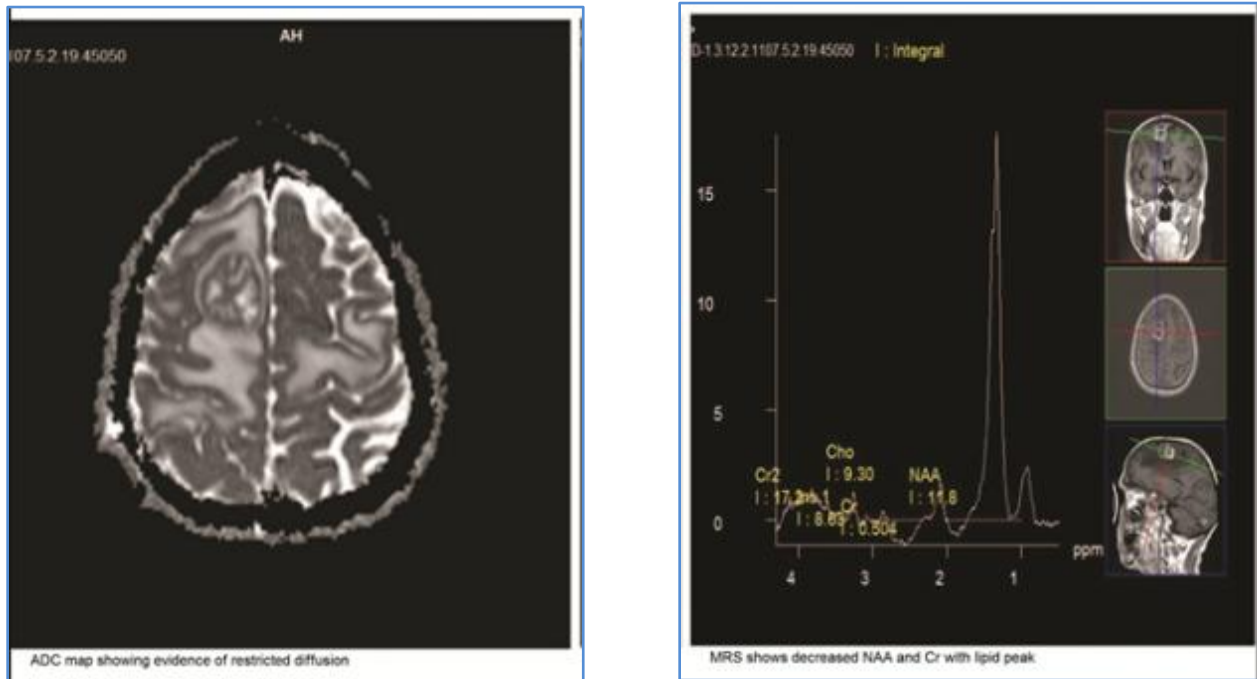
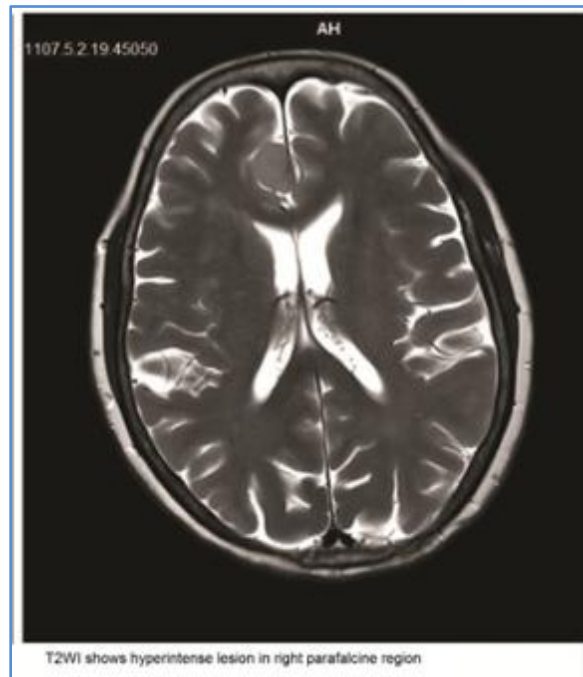
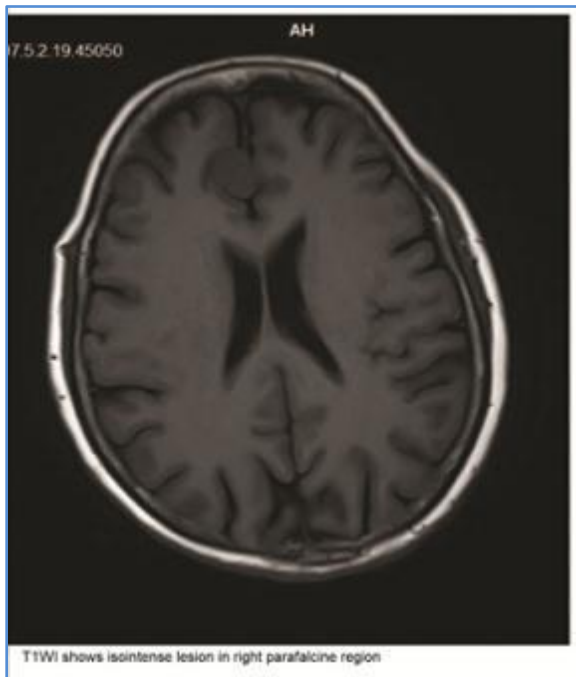


Fig. 3: Case of multiple cerebral metastases



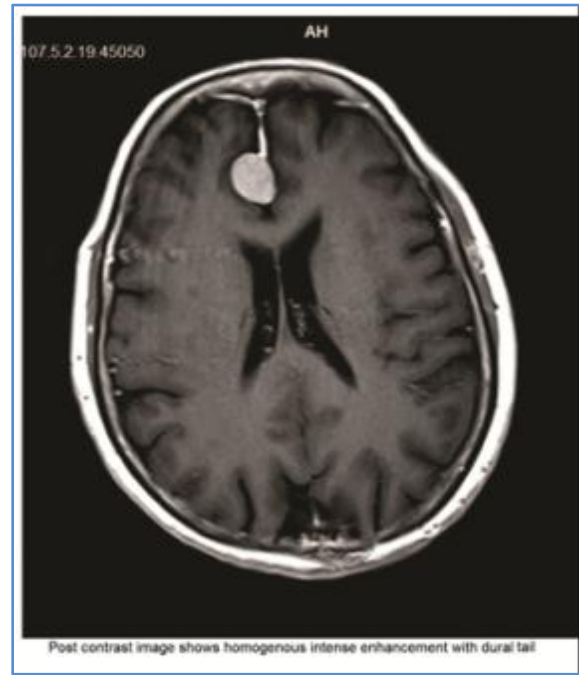
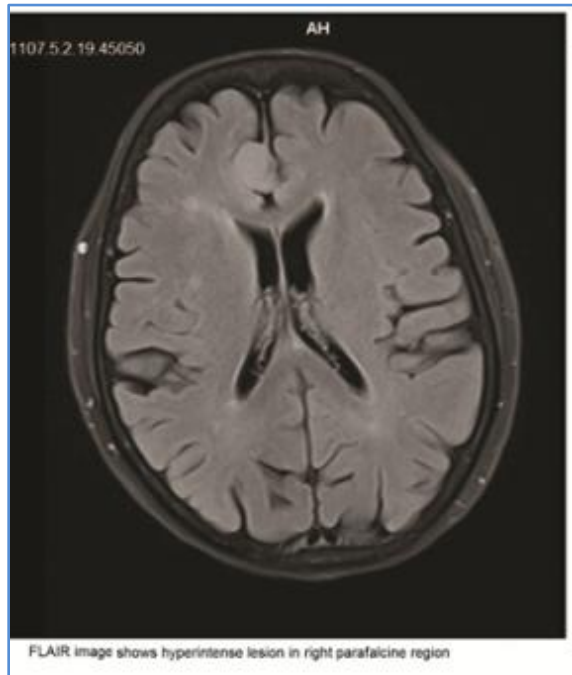
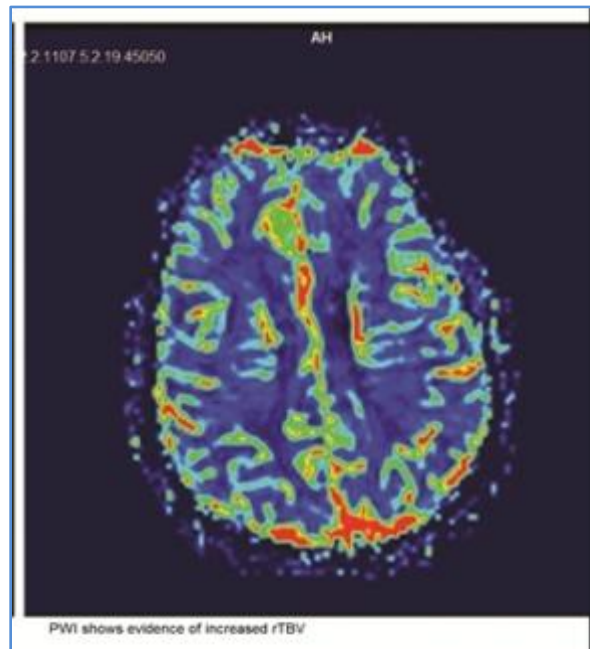
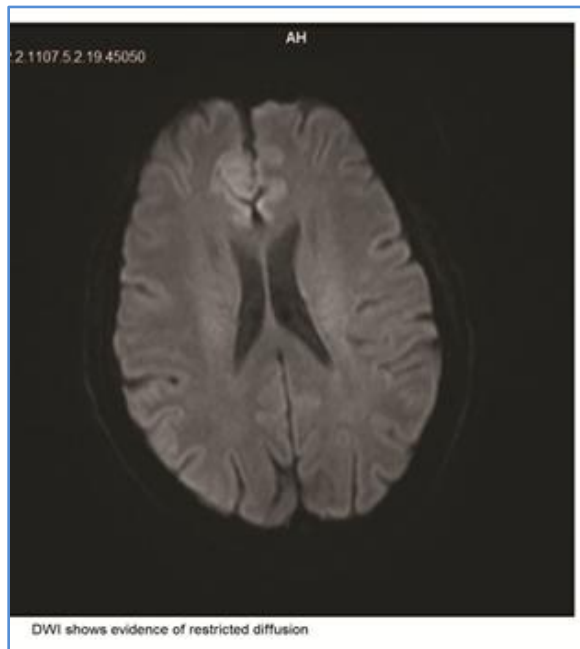


Fig. 4: Case of right parafalcine meningioma



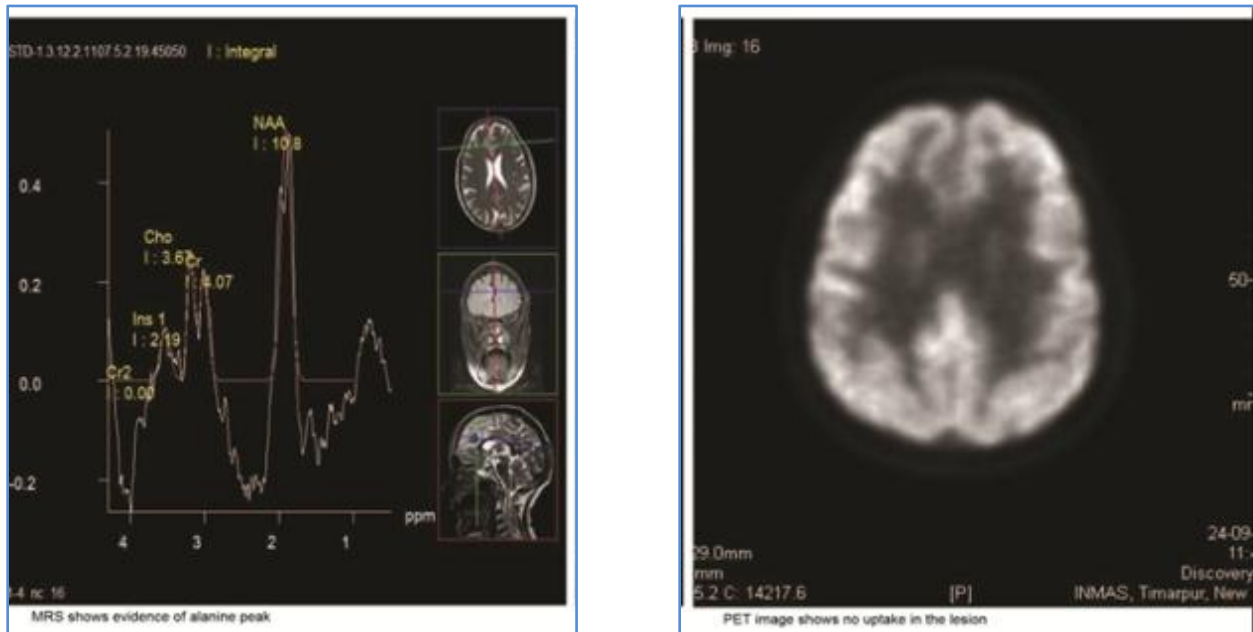


Fig. 5: Case of right parafalcine meningioma

DISCUSSION: Apart from routine MR imaging of the brain tumours, other newer MR techniques hold great promise in evaluation of these lesions. These novel MR techniques include Perfusion weighted imaging, Diffusion imaging studies and MR spectroscopic analysis of the lesion.

The present study evaluates the role of novel magnetic resonance techniques in evaluation and characterization of brain tumours. Thirty cases of brain tumours were analyzed in this study.

The age of the patients in this study ranged from 22 to 63 years. The youngest patient who was 22 years old presented with headache and nausea/vomiting. Twenty two patients (73%) belonged in the 30-50 years age group and formed the majority in the study group. All the patients had chief complaint of headache. 60% (n=18) of the patients presented with complaint of seizures, 40% (n=12) of the patients presented with complaint of nausea/vomiting, 10% (n=3) presented with focal neurological deficit and 10 % (n=3) presented with vision problems.

Few of the patients had other comorbid conditions like diabetes, hypertension or coronary artery disease. None of the patients had any renal pathology or reaction to any medication as per past history. There was no adverse reaction observed in any of the patients after Gadolinium contrast administration.

Histopathology is considered to be the gold standard for final diagnosis and management. Out of the thirty cases in the present study, twenty cases were malignant in nature and ten cases were benign. Out of the benign cases, four were meningiomas, two were low grade glioma, one was pituitary macroadenoma, one was choroid plexus papilloma, one was granulomatous lesion and one was arachnoid cyst. The majority of malignant cases were glioblastoma multiforme (n=14), followed by metastases (n=3), anaplastic astrocytoma (n=2) and lymphoma (n=1).

Diffusion weighted imaging was carried out successfully in all the lesions using echoplanar imaging. Diffusion weighted images and corresponding ADC maps were generated. In an study made

ORIGINAL ARTICLE

by Kinuko Konoa et al the ADC value ranged from 0.65 to $1.06 \times 10^{-3} \text{ mm}^2/\text{s}$ (mean $0.82 \pm 0.13 \times 10^{-3} \text{ mm}^2/\text{s}$) in nine patients with glioblastoma multiforme, from 0.88 to $1.41 \times 10^{-3} \text{ mm}^2/\text{s}$ ($1.14 \pm 0.18 \times 10^{-3} \text{ mm}^2/\text{s}$) in eight patients with grade II astrocytoma, from 0.35 to 1.37 ($0.79 \pm 0.23 \times 10^{-3} \text{ mm}^2/\text{s}$) in 21 patients with metastatic tumour, and from 0.51 to 1.08 ($0.78 \pm 0.17 \times 10^{-3} \text{ mm}^2/\text{s}$) in 18 patients with meningioma. Cutoff value of $0.92 \times 10^{-3} \text{ mm}^2/\text{s}$ for ADC provided 91.5% sensitivity and 86.5% specificity.

In our study, mean ADC values ranged from 0.473×10^{-3} to 2.631×10^{-3} . The median ADC value of malignant lesions was 0.529×10^{-3} and that of benign lesions was 1.621×10^{-3} . Three lesions that were proved to be benign on histopathology had mean ADC values in the range of malignant lesions, ranging from 0.276 to 0.738×10^{-3} . These values had good agreement with earlier studies. Out of the three false positive cases, two were later proved to be meningiomas and one was a granulomatous lesion. The false positive cases could represent benign lesions with high cellularity leading to restricted diffusion.

Perfusion weighted MRI (PwMRI) was carried out to see for lesion enhancement pattern as well as to study relative cerebral blood flow (rCBV). rCBV ratio was calculated. Out of twenty proven malignant cases, seven had rCBV ratio > 1.5 which is strongly suggestive of malignancy. None of the benign lesions showed rCBV ratio > 1.5 . Out of total thirty patients, twenty two patients had rCBV ratio between 1.5 and 1 which signifies an indeterminate lesion. rCBV ratio between 1.5 and 1 can be seen in benign as well as malignant cases as was seen in this study. Only one of the lesions had rCBV ratio < 1 suggestive of hypovascular lesion and is highly characteristic of benign lesions as was the case in our study.

MR spectroscopy was carried out in all thirty patients and Cho/Cr ratio were automatically generated using software provided. According to a study made earlier tumours with a choline (Cho)/creatine (Cr) > 2.5 in the tumour and NAA/cho < 1 in the normal-appearing brain tissue adjacent to the tumours were considered to be highly malignant gliomas whereas tumours with a cho/cr < 2.5 on MRS were considered to be low-malignant gliomas. Tumours with a cho/cr > 2.5 in the tumour on MRS, and an NAA/cho > 1 in the normal-appearing brain tissue adjacent to the tumour were considered to be metastases. Cystic lesions with lactate and amino acid peaks on MRS, were considered to be abscesses. This study concluded lower added utility of MRS (70%) when used alone indicating that the MRS must be complemented by other novel MRI techniques.

CONCLUSION: This study was conducted on thirty patients of brain tumours diagnosed on CT scan / Conventional MRI. It was performed in the Department of Radiological and PET Imaging, Institute of Nuclear Medicine and Allied Sciences (INMAS), Brig S.K. Mazumdar Marg, Lucknow road, Delhi.

The aim of our work was to evaluate the role of novel MRI techniques in brain tumours. Out of thirty patients 19 patients (63.33%) were male and 11 patients (36.66%) were female. Their ages ranged from 22 to 63 years. The most common presenting symptom was headache followed by seizures.

With advent of high field magnets and stronger gradients, the imaging times have reduced considerably along with superior spatial and temporal resolution. This has brought MRI to the forefront in diagnostic imaging of brain tumours.

Contrast enhanced MRI including perfusion weighted imaging adds to the information available from conventional MRI sequences and is being routinely integrated into magnetic

ORIGINAL ARTICLE

resonance protocols for brain tumours imaging. With advent of 20 channel dedicated head coil and recent scanners, the temporal resolution required for perfusion weighted characteristics is being routinely evaluated adding to the diagnostic confidence.

Diffusion weighted technique is a robust technique which can be easily integrated into brain tumours imaging with little addition in scanning time. It has proven to be highly sensitive in differentiating malignant lesions from benign with very high positive predictive values and low false negatives.

MR spectroscopy can be used to identify biochemical milieu of a lesion in vivo. It has got diagnostic as well as prognostic value in evaluation of brain tumours. However high choline is a non-specific marker for increased cell membrane turnover and there is a significant overlap between benign and malignant lesions. With further progress in hardware and software technology, new markers can be identified in future to add more specificity to spectroscopic findings.

With integration of newer imaging techniques like diffusion weighted imaging, perfusion weighted imaging and MR spectroscopy, a high level of diagnostic confidence can be achieved in characterization of brain tumours thus significantly reducing patient morbidity and mortality.

So to conclude combining novel MRI techniques especially DWI, PWI and MRS with conventional MR imaging increases the diagnostic accuracy of MRI in the evaluation of brain tumours and tumour-like lesions. In some tumours, this benefit might preclude brain biopsy, which is an invasive procedure that would otherwise be required to establish the final diagnosis. It also helps to avoid delay in initiating tumour therapy as well as progress of the treatment. Although expensive and time-consuming, the novel MRI techniques should, wherever available, be performed in addition to conventional MRI sequences in the evaluation of brain tumours and tumour-like lesions.

BIBLIOGRAPHY:

1. Moritani T, Ekholm S, Westesson PL. Diffusion-Weighted MR Imaging of the Brain. Berlin Heidelberg: Springer; 2009.
2. Bammer R. Basic principles of diffusion-weighted imaging. *European Journal of Radiology* 2003; 45(3) 169-184.
3. Timothy PL, Rowley HA. Diffusion weighted magnetic resonance imaging in stroke. *European Journal of Radiology* 2003; 45(3) 185-194.
4. Petrella JR, Provenzale JM. MR Perfusion Imaging of the Brain Techniques and Applications. *American Journal of roentgenology* 2000; 175(1) 207-219.
5. Pollock JM, Tan H, Kraft RA, Whitlow CHT, Burdette JH, Maldjan JA. Arterial Spin Labeled MRI Perfusion Imaging: Clinical Applications *Magnetic resonance imaging clinics of North America* 2009; 17(2) 315-338.
6. Majós C, Aguilera C, Cos M, Camins A, Candiota AP, Delgado-Goni T, Samitier A, Castaner S, Sánchez JJ, Mato D, Acebes JJ, Arús C. In vivo proton magnetic resonance spectroscopy of intraventricular tumours of the brain. *European Radiology* 2009; 19(8) 2049-2059.
7. Schlemmer HP, Bachert P, Henze H, Buslei R, Herfarth KK, Debus J, van Kaick G. Differentiation of radiation necrosis from tumour progression using proton magnetic resonance spectroscopy. *Neuroradiology* 2002; 44(3) 216-222.

ORIGINAL ARTICLE

AUTHORS:

1. Mohammad Shamim Ahmad
2. Reyaz Anjum
3. Anju Singh
4. Dinesh Kumar Singh
5. D. G. Paricharak

PARTICULARS OF CONTRIBUTORS:

1. Assistant Professor, Department of Radiology, Major S. D. Singh Medical College, Farukhabad.
2. DNB, 3rd Year, Department of Radiology, Institute of Nuclear Medicine and Allied Sciences, Delhi.
3. Associate Professor, Department of Forensic Medicine, Mayo Institute of Medical Sciences, BBK.

4. Assistant Professor, Department of Pathology, MIMS, BBK.
5. Associate Professor, Department of Pathology, D. Y. Patil Medical College Kolhapur.

NAME ADDRESS EMAIL ID OF THE CORRESPONDING AUTHOR:

Dr. Dinesh Kumar Singh,
#18/431, Indira Nagar,
Lucknow-226016, Uttar Pradesh.
E-mail: drdineshsingh7@gmail.com

Date of Submission: 13/11/2014.
Date of Peer Review: 14/11/2014.
Date of Acceptance: 29/12/2014.
Date of Publishing: 06/01/2015.