

CASE REPORT

OUTCOME OF CATARACT SURGERY IN A PATIENT WITH BILATERAL MICROCORNEA AND IRIS COLOBOMA

Nanda L¹, Appaji Gowda², Shivakumar M³, Aadith Bhaskar⁴

HOW TO CITE THIS ARTICLE:

Nanda L, Appaji Gowda, Shivakumar M, Aadith Bhaskar. "Outcome of cataract surgery in a patient with bilateral microcornea and iris coloboma". Journal of Evolution of Medical and Dental Sciences 2013; Vol. 2, Issue 41, October 14; Page: 4931-4935.

ABSTRACT: Presenting here, the outcome of cataract surgery in a 38 years old female patient who was diagnosed with bilateral microphthalmos, microcornea, and iris coloboma, choroidal coloboma with posterior sub-capsular cataract right eye and with immature cataract in left eye. Patient underwent an uneventful right eye cataract surgery with good visual outcome and normal intraocular pressure.

KEYWORDS:-Microphthalmos, Microcornea, Iris coloboma, Choroidal coloboma, Immature cataract.

INTRODUCTION: Microphthalmos refers to a condition where entire eyeball is small in size. Microcornea refers to horizontal corneal diameter less than 10mm.¹Corneal diameters can adversely impact the eye in many ways including the size of the incision, corneal decompensation, secondary glaucoma, maculopathy and discomfort.²

CASE REPORT: A 38 yrs old female patient presented to ophthalmology OPD with complaints of diminished vision in both eyes (Right>Left) since one year. It was gradual, painless, progressive loss of vision, associated with no other ocular complaints. There was no history of redness, watering, intake of any drug or trauma to the eye. There was no history of wearing glasses. Patient is not a known case of diabetes mellitus, hypertension and bronchial asthma.

Ocular examination revealed only best corrected visual acuity of counting fingers 2 meters in the right eye and the visual acuity in her left eye was counting fingers of 2 meters with pinhole improving to 6/36.

On slit lamp examination of right eye, there was microphthalmos, microcornea, irregular depth of the anterior chamber, total typical iris coloboma in lower nasal quadrant with briskly reacting pupil and posterior sub-capsular cataract with faint fundal glow. The intra ocular pressure was 11mm of mercury with non-contact tonometer.

On slit lamp examination of left eye, there was microphthalmos, microcornea, irregular depth of the anterior chamber, iris coloboma in lower nasal quadrant with briskly reacting pupil and immature cortical cataract with faint fundal glow, details could not be made out. The intra ocular pressure was 12mm of mercury with non-contact tonometer.

CASE REPORT

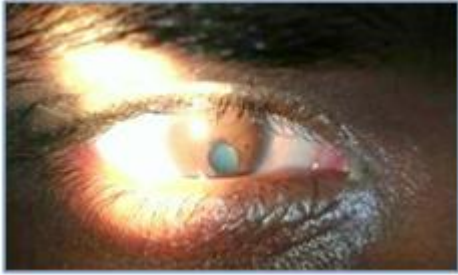

Fig 1: Right eye showing Microphthalmos, microcornea, iris coloboma, posterior sub-capsular cataract

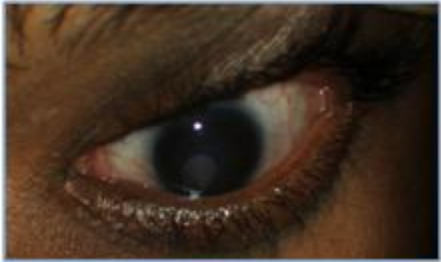


Fig 2: Left eye showing microphthalmos, microcornea, irregular depth of the anterior chamber and iris coloboma

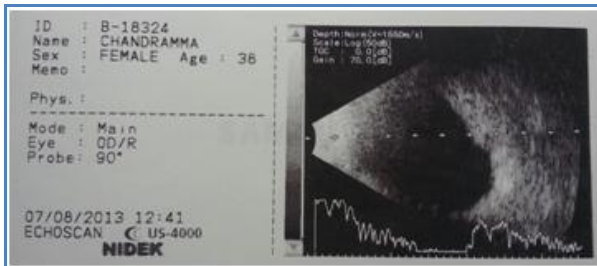


Fig 3: B-scan of right eye showing choroidal coloboma

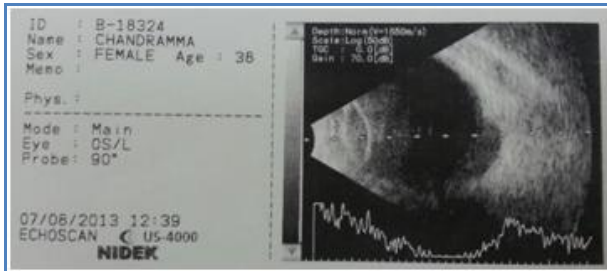


Fig 4: B-scan of left eye showing choroidal coloboma

	RIGHT EYE	LEFT EYE
Horizontal diameter	8.5mm	8.0mm
Vertical diameter	8.0mm	7.5mm


Table 1: Corneal diameter

CASE REPORT



Fig 5: A-scan of both eyes

On Gonioscopy:-



After one week patient was posted for Right eye Phacoemulsification cataract surgery.

Subconjunctival injection of 2% xylocaine with adrenaline mixed with hyaluronidase injection was given for local anesthesia. A clear corneal tunnel using 3.2mm keratome blade at 11 O' clock position was made. Size of corneal tunnel was 2mm in length. Continuous curvilinear capsulorhexis was done. Phacoemulsification was done using low vacuum of 200mm Hg with the linear mode. A CTR (Capsular Tension Ring) was implanted into the capsular bag. Posterior Chamber Foldable Lens was implanted in the capsular bag. It was an uneventful surgery.

	RIGHT EYE	LEFT EYE
K1(VERTICAL)	44.5 (7.58)	44.25 (7.65)
K2(HORIZONTAL)	45.0 (7.50)	45.50 (7.40)
AXIAL LENGTH	20.15 mm	20.19 mm
IOL POWER	+30 D	+30 D

Table 2: A-scan and keratometry

CASE REPORT

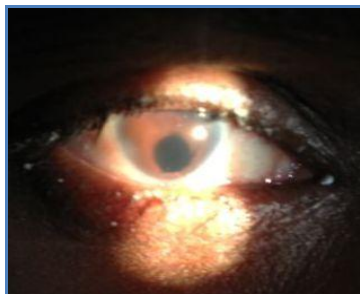


Fig 6:-Right eye after surgery

On the first post-op day cornea was clear, anterior chamber quiet and well formed, pupil reacting and PCIOL was in situ. Unaided visual acuity was 6/36 and with pin hole it improved to 6/18p.

She was started on Gatifloxacin with Prednisolone eye drops hourly and ketorolac eye drops 4 times per day. She was followed up every week. After 2 week unaided visual acuity in the right eye improved to 6/24 and pinhole was 6/12p. IOP was 11mm of Hg with Non-contact tonometer. Fundus examination revealed choroidal coloboma with no other abnormalities.

Both eye drops were continued for 6 weeks with tapering of steroid eye drops to 1 drop 4 times a day after 4 weeks.

DISCUSSION: Microphthalmos, microcornea, iris coloboma, posterior sub-capsular cataract and choroidal coloboma is a common condition. But attempting phacoemulsification is difficult in this condition. Microcornea refers to a condition when the horizontal corneal diameter is less than 10mm. Patients with microcornea are hypermetropic and have shallow anterior chamber.³ Ocular associations with microcornea includes glaucoma (closed and open angle), congenital cataract, leukoma, optic nerve hypoplasia, microphakia and cornea plana. Other associated systemic syndromes include Turner's syndrome, Ehlers-Danlos syndrome and Weill-Marchesani syndrome.⁴

Coloboma implies the absence of tissue. Iris coloboma also known as keyhole defect of the iris is due to defective closure of embryonic fissure.

Microphthalmos refers to small eye ball with axial length less than 21mm.

CONCLUSION: Microphthalmos, microcornea, iris coloboma, posterior sub-capsular cataract and choroidal coloboma is not a contra-indication for cataract surgery (phacoemulsification).

Our case highlights that in spite of microphthalmos, microcornea, iris coloboma, posterior sub-capsular cataract, choroidal coloboma and with shallow anterior chamber, the phacoemulsification cataract surgery was uneventful with post operative good visual outcome

REFERENCES:

1. Jay. H. Krachmer, Fundamentals Diagnosis and Management of Cornea. Second Edition. Pg730-731.
2. Smolin and Thoft's, The Cornea- Scientific, Foundation and Clinical Practice. Fourth edition. Pg. 708-709.
3. M. Bruce Shields, TEXTBOOK OF GLAUCOMA. Fourth edition. Pg5-25.
4. Peyman -Sanders-Goldberg; Principles and Practice of Ophthalmology, Volume II. pg 1491-1521.
5. Roger. F. Steinert, Cataract Surgery. Third edition. Pg399-410.

CASE REPORT

AUTHORS:

1. Nanda L.
2. Appaji Gowda
3. Shivakumar. M.
4. Aadith Bhaskar

PARTICULARS OF CONTRIBUTORS:

1. Senior Resident, Department of Ophthalmology, Rajarajeswari Medical College and Hospital, Bangalore.
2. Professor, Department of Ophthalmology, Rajarajeswari Medical College and Hospital, Bangalore.
3. Professor and HOD, Department of Ophthalmology, Rajarajeswari Medical College and Hospital, Bangalore.

4. Post Graduate, Department of Ophthalmology, Rajarajeswari Medical College and Hospital, Bangalore.

NAME ADDRESS EMAIL ID OF THE CORRESPONDING AUTHOR:

Dr. Nanda. L,
Senior Resident,
Department of Ophthalmology,
Rajarajeswari Medical College and Hospital,
Kambipura, Kengeri Hobli,
Mysore Road, Bangalore – 74.
Email – nanda.shivakumar@rediffmail.com

Date of Submission: 26/09/2013.

Date of Peer Review: 28/09/2013.

Date of Acceptance: 04/10/2013.

Date of Publishing: 09/10/2013