

# CASE REPORT

---

## RETINAL HAEMORRHAGE IN PLASMODIUM VIVAX PATIENTS- 2 RARE CASE REPORTS

Sangeeta Sharma, Ujwala Maheshwari, Nidhi Bansal

1. Assistant Professor, Department of Pathology MGM Medical College, Navi Mumbai
2. Professor, Department of Pathology MGM Medical College, Navi Mumbai
3. Resident, Department of Pathology MGM Medical College, Navi Mumbai

### CORRESPONDING AUTHOR

Dr. Sangeeta Sharma,  
1801, Kasturi Heights,  
Sector-20, Plot 39, Kharghar,  
Navi Mumbai, Maharashtra, India  
E-mail: drsangeetasharma@gmail.com  
Ph: 0091 9323009867, 0091 8692999076

**ABSTRACT:** Retinal haemorrhage is commonly detected during ophthalmoscopic examination of patients with Plasmodium falciparum infections. However, it is observed very rarely in Plasmodium vivax infections. Only six cases of retinal haemorrhage have been reported so far in Plasmodium vivax infections. We review the literature and discuss two such cases of retinal haemorrhage that presented at our hospital. It is suggested that retinal haemorrhage be routinely ruled out in all malaria patients, and Plasmodium vivax infection be considered in patients with unexplained retinal haemorrhage and fever.

**KEYWORDS:** Retinal Haemorrhage, Plasmodium vivax, Plasmodium falciparum, Malarial Retinopathy

**CASE REPORT 1:** A 23 year old female presented with complaints of fever with chills, malaise since 5 days, and a few episodes of watery, non-blood stained vomiting. There was no history of any bleeding manifestations, joint pain, or breathlessness. She had no significant past history. Clinical examination revealed Fever-100°F, Pulse rate-130/min regular, Blood pressure-110/70 mm Hg, severe pallor, and mild icterus. Systemic examination per abdomen revealed soft, mild hepato-splenomegaly. Routine lab investigations showed Hb-2.4gm%, low Platelet count-20,000/cumm, Total Bilirubin-4.74mg/dl and Serum Creatinine-1.34mg/dl. Peripheral smear showed pancytopenia with microcytic hypochromic anemia and ring forms of trophozoites and schizonts of Plasmodium vivax. Anti-malarial treatment was started and blood transfusion was also done. On the morning of Day 3, the patient suddenly developed blurring of vision. An urgent ophthalmoscopic examination revealed generalized retinal bleeding involving the macular areas in both eyes (Right eye>Left Eye), leading to the loss of vision [Fig 1]. A review ophthalmoscopic examination done 5 days later showed that both eyes had Sub-hyaloid haemorrhages along with Roth's spots.

**CASE REPORT 2:** A 23 year old male presented with complaints of malaise, fever with chills off and on for 5 days, bleeding per rectum since 3 days, and blurring of vision since 3 days. There was no history of bleeding from any other site or any rashes or joint pain. Clinical examination showed that he was afebrile, Pulse rate-88/min regular, Blood pressure-110/70 mm Hg, severe pallor, icterus, and bilateral pitting pedal edema. Systemic examination showed mild hepato-

# CASE REPORT

---

splenomegaly. Routine lab investigations showed Hb-3.7gm%, low Platelet count - 70,000/cumm, Total Bilirubin-1.41mg/dl, and Serum Creatinine-1.08mg/dl. Peripheral smear showed dimorphic anaemia, leucopenia and ring forms of trophozoites of Plasmodium vivax. Fundoscopy revealed bilateral Roth's spots with Sub-hyaloid haemorrhages [Fig 2]. The patient was treated with anti-malarials and blood transfusion. A repeat ophthalmoscopic examination after 9 days showed resolution of haemorrhages in both the eyes, which was consistent with improved vision in the patient.

**DISCUSSION:** Retinal haemorrhages are frequently observed in cases of Plasmodium falciparum infections, with its incidence associated with the severity of the Plasmodium falciparum infection [1,2,3]. Malarial retinopathy is seen in adult patients with severe malaria [4], with retinal haemorrhages in 46% cases of cerebral malaria [5] An incidence of 60% is observed in children with cerebral malaria, with lower incidence in less severe forms of malaria [1,6]. A study by Beare et al [7] proposed that detection of malarial retinopathy should tilt the diagnosis in favour of cerebral malaria. Lewallen and others [1] proposed that children with Plasmodium falciparum malaria should be categorized according to their ocular fundus findings, which helps in further diagnostic evaluation.

However, retinal haemorrhage is rarely reported in patients infected with Plasmodium vivax and its exact incidence is not known. The only six cases reported till now have come from India and South Korea, both countries having malaria endemic zones. Both cases in our study also came from endemic zones in Navi Mumbai, India.

Retinal haemorrhages in Plasmodium falciparum patients are due to the sequestration of parasitized RBCs and cytoadhesion with Rosetting, which leads to the haemorrhage [8]. However the mechanism is poorly understood in Plasmodium vivax infections, where sequestration is not seen, although Rosetting has been rarely reported [8,9]. Both cases presented by us had severe anaemia and thrombocytopenia, which could also play a role in the development of retinal haemorrhage in Plasmodium vivax infections.

It has been observed that retinal haemorrhages in malaria patients usually resolve spontaneously but a decrease in visual acuity has been reported in rare cases [10]. This may be because of haemo-toxicity to the photoreceptors, after disruption of tissue oxygenation. To conclude, physicians should routinely conduct ophthalmoscopic examination, even in cases of Plasmodium vivax infection, to rule out retinal haemorrhages. It is also suggested that the possibility of Plasmodium vivax infection be considered in cases of sudden unexplained retinal haemorrhage.

**ACKNOWLEDGEMENT:** We thank the 'Medicine Department' and the 'Ophthalmology Department' of MGM Medical College and Hospital, Kamothe, Navi Mumbai for their help, valuable discussions and providing photographs.

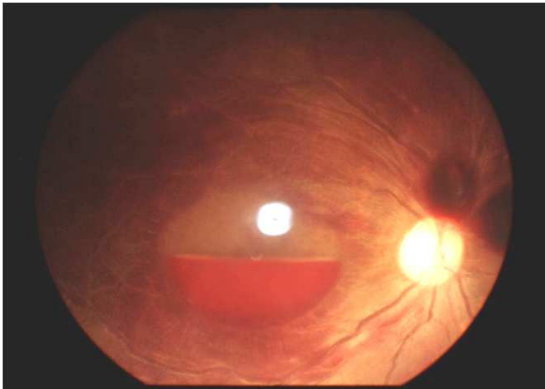
## REFERENCES:

- 1 Lewallen S, Bronzan RN, Beare NA, Harding SP, Molyneux M.E. Taylor T.E. Using malarial retinopathy to improve the classification of children with cerebral malaria. Trans R Soc Trop Med Hyg. 2008; 102: 1089-109

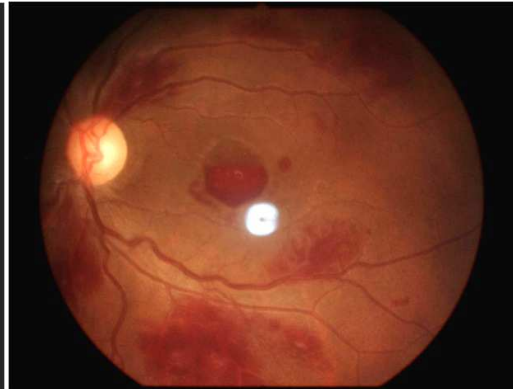
## CASE REPORT

---

- 2 Looareesuwan S, Warrell D.A., White N.J., Chanthavanich P., Warrell M.J., Chantaratherakitti S. Retinal hemorrhage, a common sign of prognostic significance in cerebral malaria. *Am J Trop Med Hyg.* 1983; 32: 911-915
- 3 Lewallen S, Taylor TE, Molyneux ME, Wills BA, Courtright P. Ocular fundus findings in Malawian children with cerebral malaria. *Ophthalmology*1993;100(6): 857-861
- 4 Maude RJ, Beare NA, Abu Sayeed A, Chang CC, et al. The spectrum of retinopathy in adults with *Plasmodium falciparum* malaria. *Trans R Soc Trop Med Hyg.* 2009; 103(7): 665-671
- 5 Beare NA, Southern C, Chalira C, Taylor TE, Molyneux ME, Harding SP. Prognostic significance and course of retinopathy in children with severe malaria. *Arch Ophthalmol.* 2004;122: 1141-1147.
- 6 Choi H.J., Lee S.Y., Yang H., Bang J.K. Retinal haemorrhage in vivax malaria. *Trans R Soc Trop Med Hyg.* 2004; 98: 387-389
- 7 Beare N.A.V., Taylor T.E., Harding S.P., Lewallen S., Molyneux M.E. Malarial retinopathy: a newly established diagnostic sign in severe malaria. *Am J Trop Med Hyg* 2006; 75: 790-797
- 8 Mackintosh C.L., Beeson J.G., Marsh K. Clinical features and pathogenesis of severe malaria. *Trends Parasitol.* 2004; 20: 597-603
- 9 Udomsanpetch R., Thanikkul K., Pukrittayakamee S., White N.J. Rosette formation by *Plasmodium vivax*. *Trans R Soc Trop Med Hyg.* 1995;89: 635-637
- 10 Runyan T.E., Ostberg R.C.. An unusual macular lesion associated with malaria. *Ann Ophthalmol.*1977; 9: 1521-1525



**Fig 1 - Shows boat shaped Sub-hyaloid haemorrhages over the macular area (Right Eye).**



**Fig 2 - Shows multiple Roth's spots with Sub-hyaloid haemorrhages in the macular region (Left Eye).**