

A HISTOMORPHOLOGICAL STUDY OF PAEDIATRIC ADRENAL TUMOURS

M.Ramani¹, O.H.Radhika Krishna², K.Geetha³, K.Ramesh Reddy⁴, P.Sreenivas Reddy⁵, Chandu Revathi⁶, Ibraheem Javeed⁷, Puja Deshmukh⁸.

1. Professor, Department Of Pathology, Niloufer Hospital, Institute Of Child Health.
2. Assistant Professor, Department Of Pathology, Niloufer Hospital, Institute Of Child Health.
3. Assistant Professor, Department Of Pathology, Niloufer Hospital, Institute Of Child Health.
4. Professor and HOD, Department Of Paediatric Surgery, Niloufer Hospital, Institute Of Child Health.
5. Professor, Department Of Paediatric Surgery, Niloufer Hospital, Institute Of Child Health.
6. Iii Year Undergraduate, Osmania Medical College
7. Postgraduate, Department Of Pathology, Niloufer Hospital, Institute Of Child Health.
8. Postgraduate, Department Of Pathology, Niloufer Hospital, Institute Of Child Health.

CORRESPONDING AUTHOR:

Dr. M.Ramani,
Professor, Department Of Pathology,
Niloufer Hospital For Women And Child Health,
Red hills, Hyderabad, Andhra Pradesh.
E-mail: drmramani@sify.com

ABSTRACT: BACKGROUND: Tumors of the adrenal gland are extremely rare in children. Those of the adrenal cortex account for only 0.3-0.4 % of all childhood neoplasms. Its rarity has hindered the identification of meaningful prognostic factors. Because very few children have been treated for adrenal tumors, even at major cancer centers, clinical experience is relatively limited and optimal therapy has not been established. Even though assessment of malignancy through histological criteria has been controversial, several investigators reported high degree of accuracy in the evaluation of malignancy by microscopic examination^(1, 2). Furthermore, Bugg et al reported that histological type and tumour weight were the most reliable predictors of tumour behaviour in the paediatric age group. **AIM:** To analyze various adrenal tumors based on histopathological pattern and correlate with clinical findings. **MATERIALS AND METHODS:** The study included 12 surgical specimens of adrenal gland out of which 3 were resected and 9 were biopsied specimens, collected between JULY 2006 to JUNE 2011 at Institute of Child Health, Niloufer hospital, Hyderabad. Tissues were processed and histopathological patterns were studied on Hematoxylin and Eosin stained sections. Immuno histochemistry was done in relevant cases and the markers used were Ki-67, Synaptophysin, NSE, Chromogranin. **RESULT:** The study showed incidence of 75% in male and 25% in female children with predilection towards left adrenal gland. **KEY WORDS:** Adrenal adenoma and carcinoma, Neuroblastoma, Pheochromocytoma, Weiss system (adrenal carcinoma).

INTRODUCTION: Tumors of adrenal gland arise from Adrenal cortex and medulla.⁽³⁾ Neoplasms of the adrenal cortex include Adenoma and Carcinoma which are very rare in pediatric age group. In contrast to adults, most children with adrenal cortical neoplasms

have evidence of a functioning tumour at presentation (virilization, Cushing syndrome or feminization).^(3,4)

Neoplasms of adrenal medulla include Neuroblastoma and Pheochromocytoma. Neuroblastoma, derived from neural crest cells, is the most common extra cranial malignancy in childhood. Ratio of Neuroblastomas to cortical neoplasms in children is 10-16:1. Pheochromocytoma is a relatively rare neoplasm in children derived from chromaffin cells of adrenal medulla.

MATERIALS AND METHODS: July 2006 to June 2011, 12 patients with adrenal tumors were studied in Niloufer hospital, Hyderabad. Clinical data like name, age, sex, symptoms at presentation, clinical features and abdominal examination with blood pressure measurement was done.

Hormonal evaluation of the adrenocortical functions and a provisional diagnosis made based on the symptoms present. Criteria for Cushing's syndrome were moon face, buffalo hump, weight gain, centripetal fat distribution, and / or hypertension with high concentrations of plasma and urinary cortisol.

Virilisation was defined by clitoromegaly or macrogenitosomia, hirsutism, deep voice, and / or increased muscle mass with elevated concentrations of plasma androgens

Feminization considered if the patient had precocious puberty, enlargement of the breasts (thelarche), pubertal distribution of fat and enlargement of both labia majora and minora with elevated levels of estradiol and decreased FSH^(5,6). Hypertension was most common followed by headache and sweating in Pheochromocytoma.⁽⁷⁾

An intravenous pyelogram, adrenal ultrasound and abdominal computerized (CT) tomography scan and search for distant metastases done. Patients underwent complete surgical resection of the neoplasm.

Tumour size and weight were recorded in all patients. Grossing was done and the sections were given for histopathology. As pathological distinction between benign and malignant adrenocortical lesions is difficult, the Weiss system^(2,8,9), first introduced 25 years ago, and considered the gold standard for determining malignancy of the adrenal cortex was used in the present study. Criteria include:

Presence of 3 or more of the following features is highly correlated with malignant behaviour

- 1) High nuclear grade (Fuhrman grade system)
- 2) >5 mitotic figures/50 HPF
- 3) Atypical mitotic figures
- 4) Eosinophilic cytoplasm in >75% of tumour cells
- 5) Diffuse architecture in >1/3 rd of the tumour
- 6) Necrosis
- 7) Venous invasion
- 8) Sinusoidal invasion
- 9) Capsular invasion

All the adrenal tumors in the study were classified on this basis.

Neuroblastomas were classified on the basis of mitotic karyotic index; in which number of cells in each high power field was counted and an average of 10 fields was taken.

ORIGINAL ARTICLE

Immunohistochemistry was performed in relevant cases with the markers Ki-67, Synaptophysin (in adrenal carcinoma) ; NSE, Chromogranin (in Neuroblastoma) and prognosis was determined using IHC.

RESULT: In the present study, incidence of adrenal tumors was more in males (9 cases) when compared to females (3 cases). The ratio of male to female incidence was 3:1. Adrenal tumors were slightly more common on the left side (7 cases) when compared to right side (5 cases), the ratio being 1.4:1.

9 patients presented with mass abdomen in which 5 of them had associated pain, 2 complained of giddiness and sweating, one had virilisation symptoms, 2 had shown criteria indicating Cushing's syndrome (fig 1).

Adrenal medullary tumors were seen in 9 (75%) cases, out of which there were 7 cases of Neuroblastoma and 2 cases of Pheochromocytoma. Adrenal cortical tumors were seen in 3(25%) cases out of which there were 2 cases of Adrenal adenoma and 1 case of adrenocortical carcinoma.

Neuroblastomas were further classified on the basis of differentiation. Out of the seven cases of Neuroblastoma, two were differentiated, one was poorly differentiated, three were undifferentiated, and one was ganglioneuroblastoma.

Immunohistochemistry with Ki67 was positive in adrenocortical carcinoma with a Ki67 labelling index of 10% (fig3a). Neuron specific enolase, Synaptophysin and chromogranin immunohistochemistry was positive in all the cases of Neuroblastoma(fig 5b).

DISCUSSION: Incidence of adrenal tumors is more in male children and slightly greater on the left side. The median age of presentation of adrenal tumors in children is 1 year. Cushing syndrome is associated with adrenocortical adenoma (fig 1a) and virilisation is associated with adrenocortical carcinoma. The evaluation and categorization of adrenocortical neoplasms remain the most challenging areas in adrenal pathology.

Adrenal adenoma: well circumscribed, yellow brown cytoplasm eosinophilic to vacuolated. Nuclei round to oval with small nucleoli, few hyperchromatic pleomorphic nuclei.(fig 1b)

Adrenal carcinoma: large, variegated areas(fig 2a). abundant eosinophilic cytoplasm, pleomorphic nuclei with prominent nucleoli. Multinucleated tumour cells with mitotic figures -12/50 hpf ⁽¹⁰⁾. (fig2b). Markers ki 67(fig 3a) and synaptophysin done (fig 3b);⁽⁴⁾ confirmed by ki 67 index >8% (Weiss system). Adrenal tumors are classified by Weiss criteria.

Pheochromocytoma: tumor was small, circumscribed, yellow tan (fig 6a), cells in "ZELLBALLEN" pattern (fig7) with salt and pepper chromatin, Reactivity for chromogranin (fig 6 b).

Neuroblastoma: calcification and cystic changes, neuroblasts and epithelial-like cells⁽¹¹⁾ ganglion cells, Schwann cells Mitotic karyotic index (MKC) used to classify as :
Low - < 2% of MKC, Intermediate - 2% - 4% of MKC, High - >4% of MKC.⁽¹⁾
NSE and chromogranin done (fig 5b).

Stewart et al (2004) studied 9 cases of adrenocortical tumors and male to female ratio of adrenocortical tumors is 1.3:1. The mean age of presentation was 29 months. These

ORIGINAL ARTICLE

cases presented with abdominal distension . Virilisation was seen in adrenocortical carcinoma and Cushing syndrome seen in cases of adrenal adenoma (table 3).

Chen qui Li et al (2008) studied 73 cases of adrenal medullary tumors over a period of 20 years . Male to female ratio was 1.8:1 and peak age of onset was 2-5 years. Most common presenting complaint was mass abdomen (table 4). The findings in the present study are in concordance with the above literature.

CONCLUSION : The evaluation and categorization of adrenocortical neoplasms remain the most challenging areas in adrenal pathology. Neuroblastoma present as abdominal masses, whereas Pheochromocytoma and adrenocortical tumors usually present with endocrine dysfunction. The clinical, radiological, biochemical and pathological features should be considered while evaluating adrenal cortical and medullary tumors. Immunohistochemistry can be used as an adjunct to histomorphology to categorize adrenal tumors. High degree of accuracy in the evaluation of malignancy by microscopic examination of adrenal tumour has been achieved, helping in easy treatment, and follow up of the patient and also to present emerging evidence concerning the adrenocortical tumorigenesis in order to address the issue of an adenoma-carcinoma sequential progression as well as to further elucidate the incompletely understood pathophysiology of this aggressive neoplasm.

REFERENCES :

1. Weiss L: Comparative histologic study of 43 metastasizing and non-metastasizing adrenocortical tumors. *Am J Surg Pathol* 1984;8 : 163-169.
2. Kenny FM, Hashida Y, Askari A et al : Virilizing tumors of the adrenal cortex , *Am J Dis Child* 1968; 115 : 445-448
3. W.Saegar, *European journal on clinical investigation, histopathological classification of adrenal tumors*, December 2003, 30: (3), 58-62
4. Romolo Sandrini et al: Childhood adrenocortical tumors. *The Journal of Clinical Endocrinology & Metabolism* July 1, 1997, 82: (7), 2027-2031.
5. Hough AJ, Hollified JW, Page DL, Hartmann WH. Prognostic factors in adrenal cortical tumors. A mathematical analysis of clinical and morphologic data. *Am J Clin Pathol.* 1979, 72:390-399.
6. Van Slooten H, Schaberg A, Smeenk D, Moolenaar AJ. Morphologic characteristics of benign and malignant adrenocortical tumors. *Cancer.* 1985, 55:766-773.
7. Terzolo M et al: Immunohistochemical assessment of Ki-67 in the differential diagnosis of adrenocortical tumors. *Urology* 2001 Jan;57(1):176-82
8. Weiss LM, Medeiros LJ and Vickery AL : Pathologic features of prognostic significance in adrenocortical carcinoma, *Am J Surg Pathol* 1988 , 13 : 202-206
9. A Blanes et al: Histologic Criteria for Adrenocortical Proliferative Lesions. *Am J Clin Pathol* 2007;127:398-408.
10. Sasano H et al : Recent advances in histopathology and immunohistochemistry of adrenocortical carcinoma. *Endocr pathology* 2006 Winter;17(4):345-54.
11. Chen Qiu Li et al: Clinical Analysis of Adrenal Neuroblastoma in 73 Children. *Journal of Applied clinical pediatrics* 2008,20:140-48

ORIGINAL ARTICLE

TABLE 1: PRESENTING SYMPTOMS OF PATIENTS

Symptoms	number of cases
mass abdomen	9
pain abdomen	5
Cushing syndrome	2
giddiness, sweating	2
virilization	1

Table 2: Identified Cases Of Neuroblastomas In The Study

Nb undifferentiated	03
Poorly differentiated	01
Differentiated	02
Ganglioneuroblastoma	01

TABLE 3: Comparison of a similar study conducted by Stewart et al and our study.

	Stewart et al (2004)	Present study
No. Of cases	09	03
Duration of study	29 years	5 year
M:f	5:4	2:1

Median age of presentation	29 months(5 months-11 years)	1 year(45 days-1 year)
Chief complaint	Abdomen distention	Abdomen distention
Cushing syndrome	8 cases	2 cases
Virilisation	4 case	1 cases
Adenoma: carcinoma	1:8	2:1

Table 4 : Comparison of a similar study conducted by Chen Qui Li et al and our study.

	Chen qiu li et al	Present study
No. Of cases	73	07
Duration of study	20 years	05 years
M:f	1.8:1	1.3:1
Chief presenting complaint	Mass abdomen	Mass abdomen
Peak age of onset	2-5 years	1-5 years

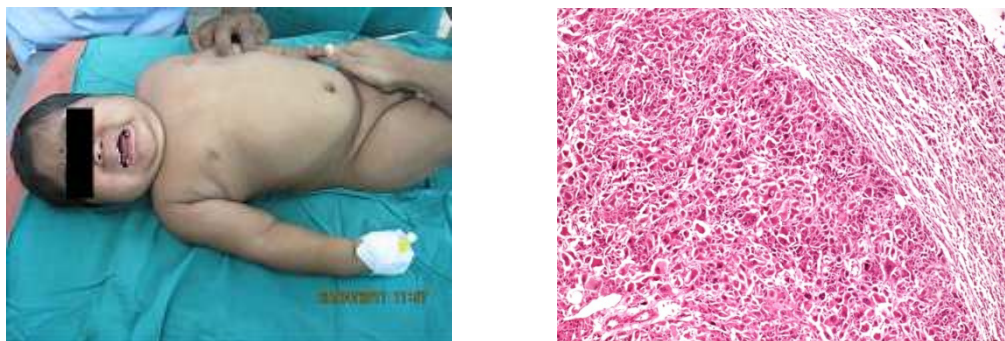


Fig 1: a) A 2 year child with right adrenal mass and Cushing syndrome
b) Photomicrograph of adrenal Adenoma, showing well defined capsule, Round to oval nuclei with small nucleoli, Few hyperchromatic nuclei and Pleomorphic nuclei in some of the cells(H & E) 10x

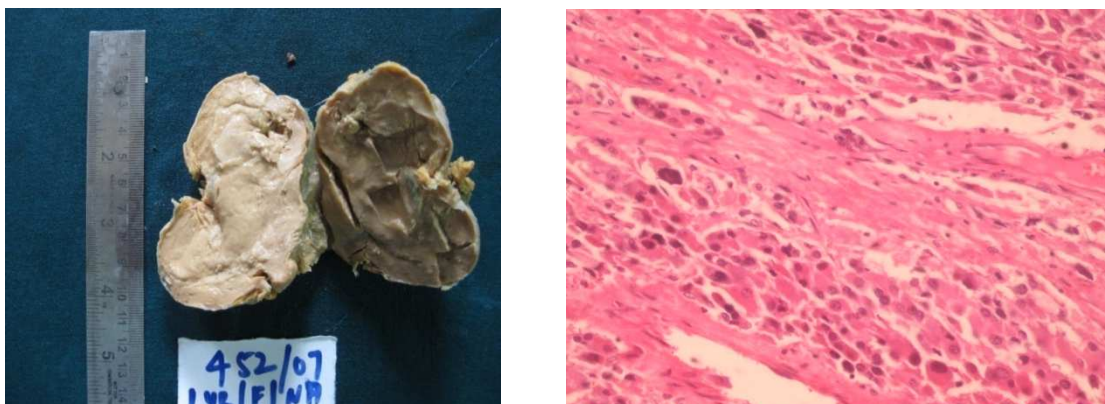


Fig 2:a)Cut section of left adrenal mass of a female child suffering with virilisation
b)Photomicrograph of adrenal carcinoma showing large pleomorphic cells ,abundant eosinophilic cytoplasm, pleomorphic nuclei with prominent nucleoli, multinucleated tumour cells, Mitotic figures -12/50 hpf(H & E) 40x

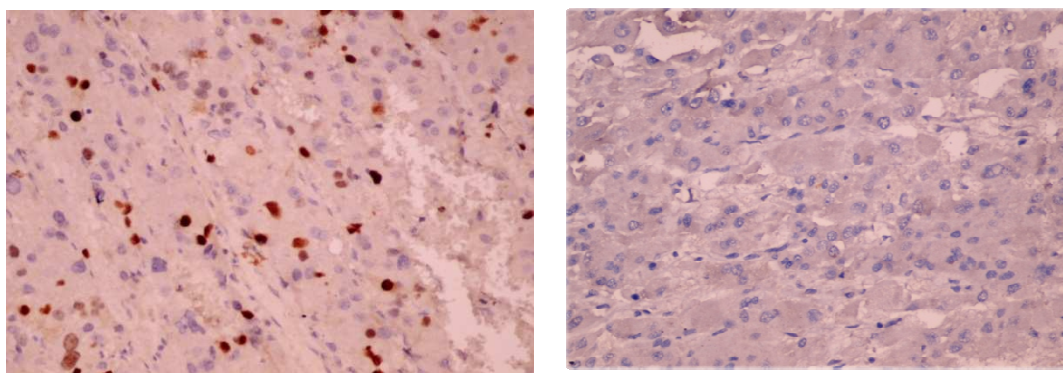


Fig 3: Photomicrograph of adrenal carcinoma detecting markers
a)ki-67 (labeling index-15%, >8% in favor of carcinoma - Weiss system for Adrenocortical carcinoma) b)synaptophysin ; immunohistochemistry, 40x

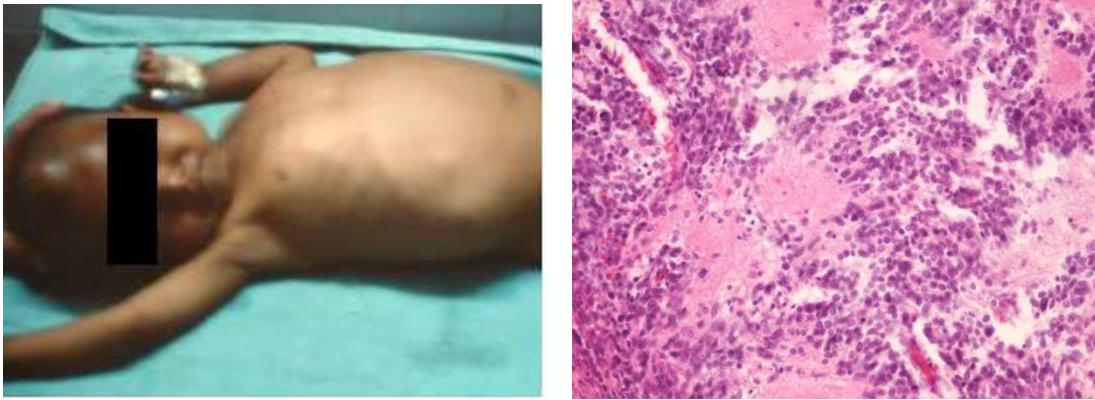


Fig 4: a) photograph of child with right adrenal Neuroblastoma with scalp metastasis b) Photomicrograph showing poorly differentiated Neuroblastoma (H & E) 10x

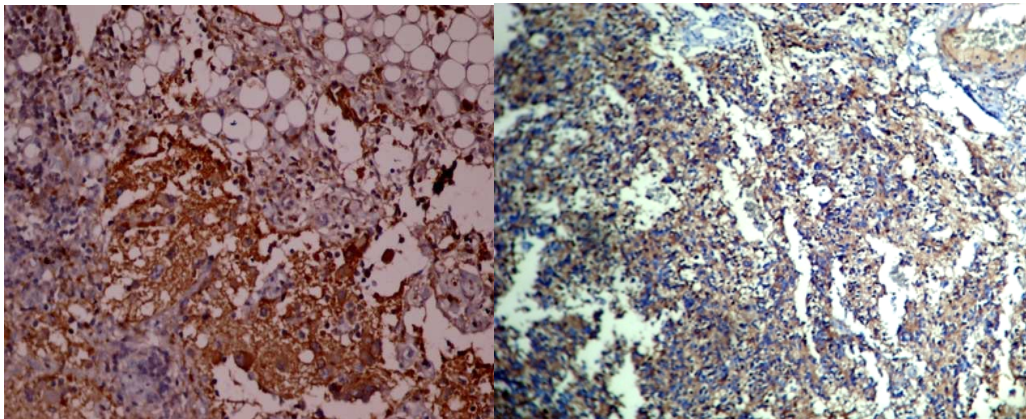


Fig 5: Photomicrograph of Neuroblastoma with tumour markers a) NSE b) chromogranin (immunohistochemistry)

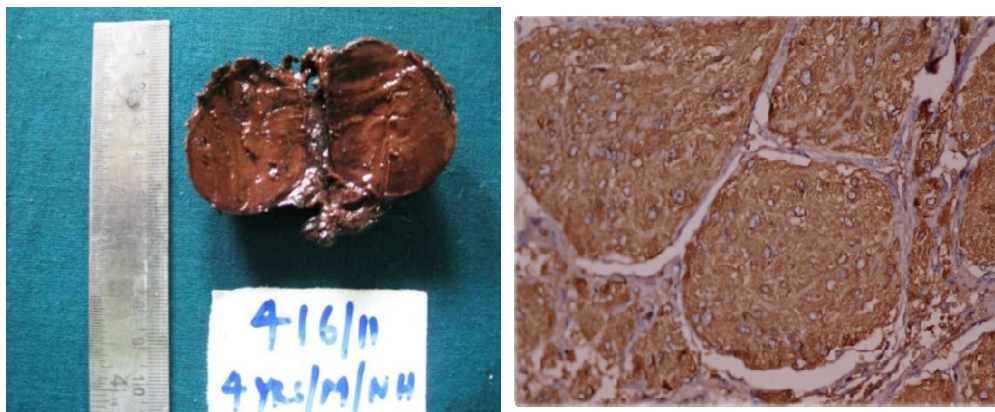


Fig 6: a) cut section of Pheochromocytoma of a child suffering with giddiness, sweating and raised VMA levels b) photomicrograph of Pheochromocytoma with chromogranin detection(marker)

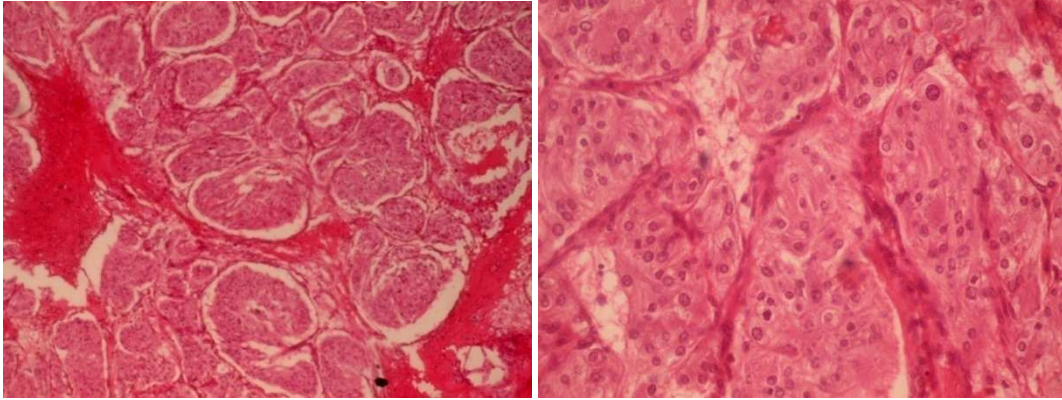


fig 7: Photomicrograph of Pheochromocytoma showing: Zellballen pattern , large round to polygonal cells with granular eosinophilic cytoplasm , pleomorphic hyperchromatic nuclei (H & E) a)10x b)40x