

CLINICOPATHOLOGICAL STUDY OF DISEASES HOMING AND INFILTRATING BONE MARROW IN CHILDREN LESS THAN 3 YEARS OF AGE

M. Ramani¹, D. Ranganath², K. Geetha³, Kazi Wajid Husain⁴, J. Khyati Kiran⁵, Puja Deshmukh⁶

HOW TO CITE THIS ARTICLE:

M. Ramani, D. Ranganath, K. Geetha, Kazi Wajid Husain, J. Khyati Kiran, Puja Deshmukh. "Clinicopathological study of diseases homing and infiltrating bone marrow in children less than 3 years of age". Journal of Evolution of Medical and Dental Sciences 2013; Vol2, Issue 34, August 26; Page: 6387-6393.

ABSTRACT: BACKGROUND: Bone marrow is the fourth largest organ with approximately 5% of body weight. It is also a prime site for infiltration of foreign and abnormal tissue. It may be involved without any abnormality in imaging, bone scan, serum chemistry or haematological parameters. Bone marrow examination is fastest, easiest, cheapest and simplest technique. Bone marrow biopsy is particularly useful when aspirate cannot be obtained due to fibrosis or densely packed tumour cells. Early and accurate diagnosis with prompt treatment might significantly improve the patient outcomes. **AIMS AND OBJECTIVES:** To study the clinical presentation, peripheral smear examination and bone marrow findings of diseases homing in and infiltrating the marrow in children less than 3 years of age. **MATERIAL AND METHODS:** The present retrospective study was undertaken for a period of 5 years from June 2005 to May 2010 at Department of Pathology, Paediatric Referral Hospital. Clinical findings were obtained from the patients records, their haemograms were studied and the bone marrow smears and biopsies were examined. **RESULTS:** A Total of 194 Bone marrow aspirations and biopsies were done during this period in children aged less than 3 years. In all these cases clinical examination, ultrasound study, peripheral smear examination and bone marrow study lead us to conclusive diagnosis. Bone marrow infiltration was found in 13 patients (6.7%). In majority of children, bone marrow was infiltrated by lymphoma, followed by neuroblastoma, Neimann Pick Disease, Gaucher's disease, rhabdomyosarcoma and Langerhans Cell Histiocytosis **CONCLUSION:** Closed trephine needle biopsy of the bone marrow has become an established procedure in the evaluation of many malignant and benign diseases in adults; however, its role in paediatric pathology has not yet been defined. Bone marrow aspiration and biopsy gives a diagnosis for heterogeneous group of diseases involving haematopoietic cells and other diseases infiltrating the bone marrow. The present study highlights the significance of study of bone marrow in diagnosis of diseases homing and infiltrating the bone marrow in children.

KEYWORDS: Lymphoma, Neuroblastoma, Neimann Pick Disease, Gaucher's disease, Rhabdomyosarcoma, Langerhans Cell Histiocytosis.

INTRODUCTION: Bone marrow is a principal site for blood cell formation and is a major haematopoietic organ. It is fourth largest organ constituting about 5% of the body weight in humans [1]. It is also a chief site for infiltration of foreign and abnormal tissue. It may be involved in certain diseases without any demonstrable abnormality in imaging, bone scan, serum chemistry or haematological parameters. This fact highlights the need for using sensitive techniques to detect bone marrow metastases. Though polymerase chain reaction and immunohistochemistry are more sensitive techniques, bone marrow examination is fastest, easiest, simplest and the most cost effective technique for reporting of metastases in a very short span of time.

The history of bone marrow examination dates back to 1908, when the first biopsy was accomplished. In the first few decades thereafter the reports were based on smears of bone marrow aspiration. The importance of histological sections and touch preparations of marrow in comparison with bone marrow smears was revealed in 1933^[2]. The presence of metastatic cells in a bone marrow aspirate was first reported in 1936^[3].

Cancer is a metastatic disease. Ideally cancer cells can metastasise towards many organs of the body. Clinically it has been demonstrated that cancer cells prefer to migrate to certain distant organs of the body such as bone, lung, liver, brain or the adrenal gland^[4]. In children, neuroblastoma, rhabdomyosarcoma, Ewing's sarcoma and retinoblastoma account for the majority of metastases^[5].

Bone marrow trephine biopsy is particularly valuable when aspirate cannot be obtained due to fibrosis or densely packed tumour cells. It is also important in the initial staging of certain paediatric tumours, such as neuroblastoma, rhabdomyosarcoma, primitive neuroectodermal tumour, and Ewing's tumour^[6]. It is therefore considered imperative to rule out marrow involvement in any malignancy where curative treatment is considered. Early and accurate diagnosis with prompt management significantly improves the patient outcomes.

In this present series we aim to study the clinical presentation, peripheral smear examination and bone marrow findings of diseases homing in and infiltrating the marrow in children less than 3 years of age.

MATERIAL AND METHODS: The present retrospective study was undertaken for a period of 5 years from June 2005 to May 2010 at Department of Pathology, Paediatric Referral Hospital. A Total of 194 Bone marrow aspirations and biopsies were done during this period in children aged less than 3 years. Children older than 3 years were excluded from the study. Detailed history, clinical signs and symptoms of the patient were obtained from the patients records. Complete haemogram and bone marrow studies were done.

RESULTS: A total of 194 Bone marrow aspirations and biopsies were done in children aged less than 3 years. Mean age at diagnosis was 23.7 ± 9.34 months (Range 10 - 36 months). In all these cases clinical examination, ultrasound study, peripheral smear examination and bone marrow study lead us to conclusive diagnosis. Bone marrow infiltration was found in 13 patients (6.7%). In majority of children, bone marrow was infiltrated by lymphoma (Figure 1A, 1B), followed by neuroblastoma (Figure 2A, 2B), Neimann Pick Disease (Figure 3), Gaucher's disease (Figure 4), rhabdomyosarcoma (Figure 5A, 5B) and Langerhans Cell Histiocytosis (Figure 6).

Out of the 13 cases with Bone marrow infiltration, 38.46% were cases of lymphoma, with male to female ratio being 1:4. In 23.07% of the children, bone marrow was infiltrated by neuroblastoma. While 7.69% of cases showed their bone marrow infiltrated by rhabdomyosarcoma and Langerhans Cell Histiocytosis. The rest of the 23.07% cases were storage disorders which included Neimann Pick disease and Gaucher's disease.

Incidence of bone marrow infiltration was observed to be higher in male children in all the cases except than in lymphoma. Bone marrow findings of children less than 3 years are tabulated in Table 1. Clinically the children with bone marrow infiltrations presented usually with constitutional symptoms. Other features of bone marrow involvement in the affected children

included recurrent vomiting, haematemesis, melena, haematuria, failure to thrive, hepatosplenomegaly and bone pains (Table 2).

DISCUSSION: Bone marrow examination is one of the most common and relatively safe invasive procedures done routinely in paediatric units. It is commonly done for the assessment of unexplained cytopenias and malignant conditions like leukaemia. It is also done for the diagnosis or staging of a neoplasm and storage disorders.^[7]

Chemokines play an important role in tumour cell homing to the bone marrow microenvironment. Stromal cell derived factor-1 (SDF-1) is expressed by bone marrow stroma cells and helps in sequestering mature B cells to the bone marrow. CXCR4, a G protein coupled cell surface receptor is expressed by both normal and malignant haematopoietic cells, and also includes B and T cell non-Hodgkin lymphoma, multiple myeloma, acute and chronic leukaemias. Solid tumours like breast, ovarian, prostate, rhabdomyosarcoma, and neuroblastoma also express the CXCR4 receptor and metastasise to bone in an SDF-1 dependent manner^[8].

The identification of metastatic cells in bone marrow do not pose much of a problem because the cells appear unfamiliar to the normal haematopoietic tissue, however sometimes their morphology may not reveal the exact site of origin. The morphology of metastatic tumour cells must be correlated with the clinical presentation and histopathological findings of the tumour to confirm the final diagnosis^[9].

In one series, bone marrow aspirates of 79 children with malignant solid tumours showed infiltrations in 28 patients. Bone marrow was infiltrated by neuroblastoma in 21 cases, embryonal rhabdomyosarcoma in 3 cases, osteogenic sarcoma in 2 cases, Ewing's sarcoma in 1 case and retinoblastoma in 1 case^[10].

According to another study, 213 children with various solid tumours were reviewed. 493 bone marrow aspirates from these patients were analysed. 60 patients showed bone marrow infiltrations. Bone marrow was infiltrated by neuroblastoma in 49 cases, rhabdomyosarcoma in 5 cases, retinoblastoma in 3 cases, ganglioneuroblastoma in 2 cases and miscellaneous sarcomas in 1 case^[11].

In the present study 13 children had bone marrow infiltration. Bone marrow was infiltrated by lymphoma in 5 cases, neuroblastoma in 3 cases, rhabdomyosarcoma in 1 case, Langerhans cell histiocytosis in 1 case, Niemann Picks Disease in 2 cases and Gaucher's disease in 1 case.

One study reviewed 30 children with undifferentiated lymphoma, non-Burkitt's type, bone marrow involvement was present in 70%^[12]. While another series reported lymphomas as the commonest condition infiltrating the bone marrow^[13].

Our study reported the incidence of neuroblastoma infiltrating the bone marrow to be around 23.07%. According to a study which included 48 cases of neuroblastoma, bone marrow involvement by neuroblastoma was documented in 20 patients (42%)^[14].

In the present study the incidence of storage disorders infiltrating the bone marrow was 23.07% which included 2 cases of Neimann Pick Disease and 1 case of Gaucher's disease. Our findings were consistent with that of similar study^[15].

Comparison of the present study with available literature is depicted in Table 3. Lymphoma was commonest condition to infiltrate the bone marrow in our study as similarly reported by other series. Some authors reported neuroblastomas as the most common condition infiltrating the bone

ORIGINAL ARTICLE

marrow^[10, 11]. While our study showed neuroblastomas and storage disorders as second most common conditions to infiltrate the bone marrow.

CONCLUSION: Bone marrow examination in children should be done meticulously as the identification of metastatic cells in bone marrow is not that problematic. Closed trephine needle biopsy of the bone marrow has become a recognised procedure in the assessment of many malignant and benign diseases in adults; however, its role in paediatric pathology has not yet been defined. Bone marrow aspiration and biopsy gives a diagnosis for heterogeneous group of diseases involving haematopoietic cells and other diseases infiltrating bone marrow. Bone marrow examination is fastest, easiest, cheapest and simplest technique. The current study highlights the significance of bone marrow evaluation in the diagnosis of diseases homing and infiltrating the bone marrow in children.

REFERENCES:

1. Perng GC. Role of Bone Marrow in Pathogenesis of Viral Infections. *J Bone Marrow Res.* 2013. 1: e102.
2. Bashawri LA. Bone marrow examination. Indications and diagnostic value. *Saudi Med J.* 2002 Feb; 23(2):191-6.
3. Pittman G, Tung KS, Hoffman GC. Metastatic cells in bone marrow; study of 83 cases. *Cleve Clin Q.* 1971 Apr; 38(2):55-64.
4. Coleman RE. Clinical features of metastatic bone disease and risk of skeletal morbidity. *Clin Cancer Res.* 2006 Oct 15; 12(20 Pt. 2):6243s-6249s.
5. Kaur G, Basu S, Kaur P, Sood T. Metastatic Bone Marrow Tumors: Study of Nine Cases and Review of the Literature. *J Blood Disord Transfus.* 2011. 2:110.
6. Bain BJ. Bone marrow trephine biopsy. *J Clin Pathol.* 2001 Oct; 54(10):737-42.
7. Memon S, Shaikh S, Nizamani MA. Etiological spectrum of pancytopenia based on bone marrow examination in children. *J Coll Physicians Surg Pak.* 2008 Mar; 18(3):163-7.
8. Meads MB, Hazlehurst LA, Dalton WS. The bone marrow microenvironment as a tumor sanctuary and contributor to drug resistance. *Clin Cancer Res.* 2008 May 1; 14(9):2519-26.
9. Mehdi SR, Bhatt ML. Metastasis of solid tumors in bone marrow: a study from northern India. *Indian J Hematol Blood Transfus.* 2011 Jun; 27(2):93-5.
10. Basil G. Delta, Donald Pinkel, Bone marrow aspiration in children with malignant tumours. *The Journal of pediatrics* 1 April 1964; Volume 64 issue 4: 542-546.
11. Finklestein JZ, Isaacs H, Jr., Ekert H, Higgins G. Bone Marrow Metastases in Children with Solid Tumors. *Am J Dis Child.* 1970; 119(1):49-52.
12. Sullivan MP, Watanabe A, Sutow WW, Wilbur JR. Undifferentiated Lymphoma, Non-Burkitt's Type: Meningeal and Bone Marrow Involvement in Children. *Am J Dis Child.* 1973; 125(1):57-61.
13. Cozzutto C, De Bernardi B, Comelli A, Guarino M. Bone marrow biopsy in children: a study of 111 patients. *Med Pediatr Oncol.* 1979; 6(1):57-64.
14. A. E. Mills, A. R. Bird. Bone Marrow Changes in Neuroblastoma. *Fetal & Pediatric Pathology* 1986; 5:2, 225-234.

ORIGINAL ARTICLE

15. Syed NN, Moiz B, Adil SN, Khurshid M. Diagnostic importance of bone marrow examination in non-hematological disorders. J Pak Med Assoc. 2007 Mar; 57(3):123-5.

Table 1: Bone marrow findings in children aged less than 3 years.

BONE MARROW FINDINGS	NUMBER OF PATIENTS	MALE	FEMALE
NON HODGKINS LYMPHOMA	5	1	4
NEUROBLASTOMA	3	3	0
RHABDOMYOSARCOMA	1	2	0
LANGERHAN CELL HISTIOCYTOSIS	1	1	0
NEIMANN PICK DISEASE	2	1	0
GAUCHERS DISEASE	1	1	0

Table 2: Clinical features of cases with bone marrow infiltrations in our study.

SYMPTOMS AND SIGNS
Constitutional symptoms
Recurrent vomiting
Haematemesis
Melena
Haematuria
Failure to thrive
Hepatosplenomegaly
Bone pains

Table 3: Comparison of our study with available literature.

BONE MARROW FINDINGS	BASIL ^[10] et al.	FINKLESTEIN ^[11] et al.	SULLIVAN ^[12] et al.	MILLS ^[14] et al.	SYED ^[15] et al.	PRESENT STUDY
Neuroblastoma	75%	82 %	-	42%	-	23.07%
Rhabdomyosarcoma	11%	8%	-	-	-	7.69%
Lymphoma	0%	0%	70%	-	-	38.46%
Storage Disorders	0%	0%	-	-	23.07%	23.07%
Others	14%	10%	-	-	-	7.69%

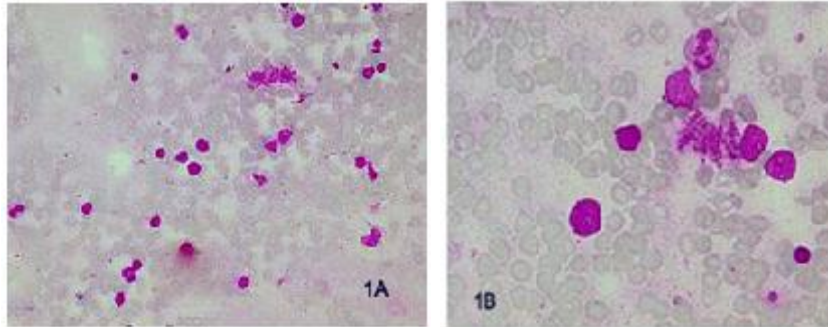


Figure 1: Bone marrow picture of lymphoma (A) Photomicrograph showing infiltrate of atypical lymphocytes with scant cytoplasm, large nuclei (Leishman's stain, 40x) (B) Photomicrograph (Leishman's stain, 100x)

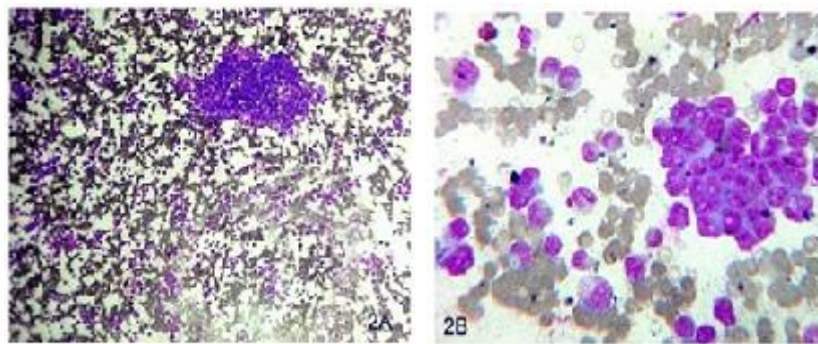


Figure 2: Bone marrow picture of metastases from neuroblastoma showing small blue round cells (A) Photomicrograph (Leishman's stain, 4x) (B) Photomicrograph (Leishman's stain, 40x)

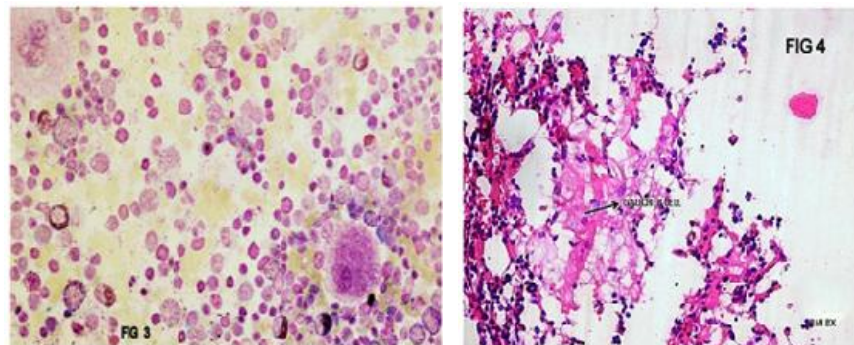


Figure 3 and 4: Bone marrow picture of infiltrations by storage disorders (3) Photomicrograph of bone marrow findings of Niemann Pick disease showing lipid-laden macrophages (Leishman's stain, 100x) (4) Photomicrograph of bone marrow findings of Gaucher's disease showing wrinkled tissue paper macrophages (Leishman's stain, 40x)

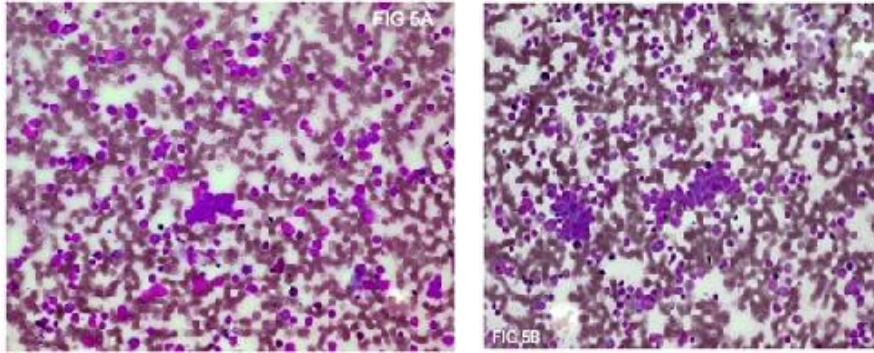


Figure 5: Bone marrow picture of metastases from rhabdomyosarcoma showing small blue round cells (A) Photomicrograph (Leishman's Stain, 10x) (B) Photomicrograph (Leishman's stain, 10x)

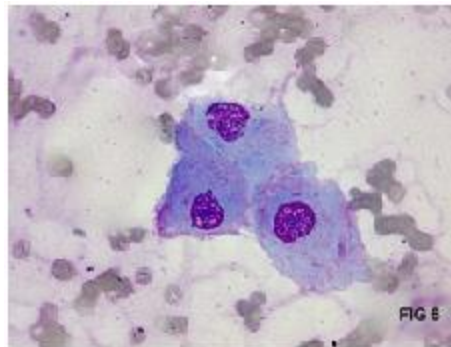


Figure 6: Photomicrograph of bone marrow findings of metastases from Langerhans Cell Histiocytosis. The histiocytes show coffee bean appearance of the nucleus. (Leishman's stain, 100x)

AUTHORS:

1. M. Ramani
2. D. Ranganath
3. K. Geetha
4. Kazi Wajid Husain
5. J. Khyati Kiran
6. Puja Deshmukh

PARTICULARS OF CONTRIBUTORS:

1. Professor, Department of Pathology, Niloufer Hospital, Hyderabad.
2. Professor, Department of Paediatrics, Niloufer Hospital, Hyderabad.
3. Assistant Professor, Department of Pathology, Niloufer Hospital, Hyderabad.
4. Post Graduate, Department of Pathology, Niloufer Hospital, Hyderabad.

5. Undergraduate, Third Year M.B.B.S., Osmania Medical College, Hyderabad.
6. Post Graduate, Department of Pathology, Niloufer Hospital, Hyderabad.

NAME ADDRESS EMAIL ID OF THE CORRESPONDING AUTHOR:

Dr. M. Ramani,
Professor, Department of Pathology,
Niloufer Hospital, Institute Of Child Health,
Andhra Pradesh, Hyderabad, India.
Email- drmramani@sify.com

Date of Submission: 07/07/2013.
Date of Peer Review: 08/07/2013.
Date of Acceptance: 14/08/2013.
Date of Publishing: 21/08/2013